





## RESEARCH ARTICLE OPEN ACCESS

# Dental Stigmata and Skeletal Lesions of Congenital Treponematoses in Early Agricultural Vietnam (4000–3500 BP)

Melandri Vlok<sup>1</sup>  | Tran Thi Minh<sup>2,3</sup>  | Nicola Czaplinski<sup>4</sup> | Hallie Buckley<sup>5</sup> | Kate Domett<sup>6</sup>  | Hiep Hoang Trinh<sup>2</sup> | Nguyen Thi Mai Huong<sup>2</sup> | Nghia Thi Huu<sup>2</sup> | Do Thi Kim Dung<sup>7</sup> | Nguyen Thi Sau<sup>7</sup> | Nguyen Phuong Thao<sup>7</sup> | Do Thi Lan<sup>7</sup> | Phan Thi Kim An<sup>7</sup> | Luong Hong Phuoc<sup>7</sup> | Hirofumi Matsumura<sup>8</sup>  | Marc Oxenham<sup>9,10</sup>

<sup>1</sup>School of Dentistry and Medical Sciences, Charles Sturt University, Orange, Australia | <sup>2</sup>Institute of Archaeology, Vietnam Academy of Social Sciences, Hanoi, Vietnam | <sup>3</sup>School of Archaeology, The University of the Philippines Diliman, Quezon City, Philippines | <sup>4</sup>School of Health Sciences, The University of Notre Dame Australia, Sydney, Australia | <sup>5</sup>School of Biomedical Sciences, The University of Otago, Dunedin, New Zealand | <sup>6</sup>College of Medicine and Dentistry, James Cook University, Townsville, Australia | <sup>7</sup>Long An Provincial Museum and Library, Ho Chi Minh City, Vietnam | <sup>8</sup>Department of Anatomy, Sapporo Medical University, Sapporo, Japan | <sup>9</sup>School of Geosciences, University of Aberdeen, Aberdeen, UK | <sup>10</sup>School of Archaeology and Anthropology, The Australian National University, Canberra, Australia

**Correspondence:** Melandri Vlok ([mvlok@csu.edu.au](mailto:mvlok@csu.edu.au))

**Received:** 28 February 2025 | **Revised:** 21 January 2026 | **Accepted:** 26 February 2026

**Keywords:** prehistory | Southeast Asia | syphilis | tropical disease | yaws

## ABSTRACT

Prior research has documented treponematoses at a single site in Mainland Southeast Asia from northern Vietnam dated to the early agricultural transition (~4000–3500 BP). To date, no other cases in Southeast Asia's prehistory have been identified. Here, we present evidence for congenital treponematoses in three non-adults from two different sites in north and south Neolithic Vietnam (4000–3200 BP) who present with dental and/or skeletal evidence consistent with congenital treponematoses, including Moon's molars of the deciduous and permanent dentition, gummatous lesions, saddle nose, and goundou. Following an extensive review of clinical and paleopathological literature, we provide here a new threshold approach for dental stigmata related to congenital transmission of treponematoses. No other cases of treponematoses (congenital or acquired) were found in Vietnam following an extensive analysis of archaeological assemblages dated from 10,000 to 1000 BP ( $n = 309$ ), suggesting treponemal disease was not a widespread condition on the east coast of Mainland Southeast Asia in prehistory. These findings also indicate a deep plasticity of *Treponema pallidum*, as the broader epidemiology still indicates a non-venereal form of the disease in Vietnam's prehistory, even with the evidence of congenital transmission.

## 1 | Introduction

Skeletal evidence for venereal syphilis has predominantly relied on the presence of congenital forms to differentiate from endemic treponematoses in the archaeological record. Congenital forms of venereal syphilis are clinically well documented in comparison with endemic treponematoses that have very few mentions in the

clinical and paleopathological literature of the last few decades (Harper et al. 2011; LaFond and Lukehart 2006; Meyer et al. 2002; Mitjà et al. 2013; Peeling et al. 2017; Powell and Cook 2005a; Vlok et al. 2020). However, prior to major eradication efforts by the World Health Organization in the 1950s, congenital forms of endemic treponematoses were reported (Engelhardt 1959; Román and Román 1986). A notable study by Engelhardt (1959), who

Melandri Vlok, Tran Thi Minh, and Nicola Czaplinski contributed equally to this work.

This is an open access article under the terms of the [Creative Commons Attribution-NonCommercial](https://creativecommons.org/licenses/by-nc/4.0/) License, which permits use, distribution and reproduction in any medium, provided the original work is properly cited and is not used for commercial purposes.

© 2026 The Author(s). *International Journal of Osteoarchaeology* published by John Wiley & Sons Ltd.

surveyed live births in 814 pregnant women from Java diagnosed with yaws, found only 25% were seronegative for yaws, with up to 70% being born with yaws lesions. Over 100 children aged between 1 and 3 years of age presented with skeletal and joint destruction related to late-stage (tertiary) treponematoses, further suggesting their initial infection occurred in utero or immediately afterward. Grin (1952) cites anecdotal evidence of congenital forms of endemic syphilis in Bosnia without providing data on the incidence. However, late term miscarriage rates in mothers infected with endemic syphilis were nearly twice that of healthy mothers from the same region. The rates of stillbirth were also almost double in infected mothers. The contemporary assumption that congenital cases are limited to venereal syphilis may be associated with data bias driven by:

1. neglect in surveillance and public health of the endemic treponematoses;
2. the predominance of western-centric health issues in the general discussions around health both past and present;
3. the epidemiological relationship between unprotected sex, pregnancy, and sexually transmitted diseases favoring greater congenital transmissions in venereal forms; and
4. the predominance of venereal syphilis being the treponematoses with the greatest global spread and incidence

Animal models have clinically demonstrated intrauterine transmission of venereal syphilis from mother to fetus in rabbits (Cooper and Sánchez 2018). Recent health research (e.g., Marks et al. 2015) has argued that these findings of congenital endemic treponematoses are predominantly unsound, as they occurred prior to proper treponemal serodiagnosis. While there are certainly issues of misdiagnosis prior to serodiagnosis, the argument ignores the knowledge of many tropical doctors of this time in recognizing the specific signs and symptoms of endemic treponematoses, often living alongside communities for months while observing sociocultural dynamics, and the age and nature of infection of affected individuals. The nature of modern global health systems, the short-term cycling of funding especially of neglected tropical diseases, and medical training do not permit the same extent of understanding of natural disease progression as pre-antibiotic era doctors; instead, the focus is on disease elimination and early intervention, as medical progress now enables this.

The pursuit by paleopathologists to define the origins of syphilis has exacerbated this assumption. The Columbian versus Pre-Columbian debate has four centuries of focus, with scholars such as Nicolo Leonceno (1428–1524) arguing syphilis was an ancient disease, whereas others such as Johannis de Vigo (1460–1520) argued the disease had appeared within his lifetime (Major 1965, 12–28). Paleopathologists have relied on congenital forms of treponematoses to argue for the origins of syphilis in the Americas (Columbian hypothesis) or to refute this argument (Pre-Columbian hypothesis), often disregarding the poor diagnostic certainty (Harper et al. 2011; R. Oliveira, Strauss, et al. 2022; Pálfi et al. 1992; Powell and Cook 2005a; Smith-Guzmán 2022). Even with the growing promise of ancient DNA, differential findings within the Americas and in Europe have not proved to bring us closer to a consensus (Barquera et al. 2025; Majander et al. 2020). The most recent

paper by Barquera et al. (2025) argues for a most recent common ancestor for the three *Treponema pallidum* subspecies approximately 9000 years ago, thereby suggesting the origin of this species in the Americas. In the tropics, the lack of DNA has so far hindered any reconstruction of ancient treponemes, which could illuminate understanding of migratory and evolutionary aspects of *Treponema pallidum*—or even reveal extinct close relatives that may have instead caused identical skeletal lesions. However, we argue on ethical grounds that DNA “pathogen prospecting” by paleogeneticists should not become a trend in Southeast Asia and that samples selected for analysis need to be cautiously screened by those who know the assemblages best—tropical paleopathologists. Macroscopic and radiographic evidence of treponematoses then remains an extremely valuable tool for identification of the disease in tropical climates at this point in time.

There has also been a welcome paradigm shift in the minds of paleopathologists surrounding the origins and antiquity of treponematoses. Many researchers in the 21st century have already moved beyond this debate to instead focus on the role treponematoses can play in defining the biocultural and ecological contexts of the prehistoric past, allowing for more substantive discussions of all the treponematoses in human prehistory, including potential species and/or subspecies that have since gone extinct (Baker et al. 2020; Powell and Cook 2005a). Ortner (2005) drew particular attention to the potential for bioarcheological research on treponematoses to shed light on host–pathogen relationships and spatio-temporal dynamics between venereal and non-venereal forms. Powell and Cook (2005b) entertained the model by Grin (1956), which suggested that congenital transmission though rare in non-venereal cases may have occurred when the mother was infected at an older age than is typical for most cases, whereby initial infection occurs in childhood. The authors drew attention to research on immunological differences in host response to *T. pallidum pallidum* (venereal syphilis) and *T. pallidum pertenuis* (yaws)—where neonates and adults had higher susceptibility to the former, and young children high susceptibility to the latter—as potential reasons for far greater reports of congenital syphilis than congenital non-venereal infections. These immunoassays from in vivo guinea pigs do little to shed light on the exact genome differences that may underlie epidemiological differences, but the changes can be expected to be very small given the overall genomic similarity of each of the subspecies. Evolutionary changes over centuries within biosocial “pressure cookers” such as the Neolithic transition could enable mutations in all the treponemes toward congenital forms.

With more engagement with biomolecular and epidemiological research, has come a broader understanding that these spirochete bacteria may have a greater plasticity than previously inferred, with a significant degree of overlap in signs, symptoms, and pathophysiology. For example, yaws (typically restricted to tropical climates) appears to be limited to mucosal areas in the body in subtropical environments, resembling the presentation of endemic syphilis, which thrives in dry conditions (Hill 1953; Ricono 1916). Strains of yaws have been genetically identified in archaeological skeletal remains in Europe, demonstrating the ability of these pathogens to

mutate and adapt to environments atypical for the broader disease complex (Majander et al. 2020). However, it is important to recognize that the ability of the different treponeme subspecies to behave similarly under the same environmental conditions and to genetically recombine does not mean they are the same disease. Thus, the re-emergence of the Unitarian hypothesis in paleopathology, the belief that all subspecies of human treponemal diseases stem from the same disease, is not genetically supported (Arora et al. 2016; Harper et al. 2008; Pla-Diaz et al. 2022). This re-emergence of the Unitarian hypothesis, like the constraints of the Columbian versus Pre-Columbian debate, does not serve any purpose in the broader discussion of the human experience with treponematosis and conflates issues of etiology with pathophysiology and pathogenesis. In summary, the complexity of treponemes as an organism, their relationship to human groups, variable environments, and coevolutionary factors at play require nuance, rather than oversimplistic research focused on a pursuit of the origins of syphilis, especially as major treponemes such as yaws and venereal syphilis are re-emerging disease threats today (Benoit et al. 2022; Dofitas, Batac, and Richardus 2022; Dofitas, Kalim, et al. 2022; Foles et al. 2024; Orbe-Orihuela et al. 2022; White and Phua 2024).

Building upon earlier paleopathological contributions, our study extends this broader framework into Southeast Asia by documenting congenital manifestations within a tropical context. Rather than contesting earlier interpretations, we aim to refine the clinical and developmental basis for identifying congenital treponematosis in archaeological assemblages. This paper presents evidence for dental stigmata and skeletal signs associated with congenital treponematosis in two sites from Neolithic Vietnam to describe the impacts of congenital treponematosis on children and their community during Mainland Southeast Asia's agricultural transition. To diagnose these dental lesions, we conduct a review of the literature on "syphilitic" dental stigmata and propose a threshold diagnostic protocol.

## 2 | Materials and Methods

### 2.1 | Archaeological Sites Assessed for This Study

A paleopathological study investigating infectious and nutritional disease in 16 sites across Vietnam was conducted in June–July 2024. A total of 309 individuals across north, south, and central Vietnam were examined for evidence of disease (Table 1; Figure 1). These individuals ranged from the Pre-Neolithic to Iron Age (10,000–1500 BP).

### 2.2 | Evaluation of Dental Stigmata and Their Relationship to Diagnosis of Congenital Treponematosis

All skeletal and dental lesions were recorded macroscopically with a DinoLite (model AM7115M27). Radiographs were taken of bones that were potentially diagnostic. Congenital treponematosis cause specific skeletal changes that are present in both infancy (early onset) and post-infancy (late onset). Skeletal

changes related to congenital treponematosis have been covered previously (see Harper et al. 2011; Vlok et al. 2020). To summarize, congenital lesions do not follow a typical progression of disease from secondary to tertiary as in the case of acquired syphilis. Instead, lesions are consistent with both inflammatory response around regions of lymph nodes (bilateral nodes and expansions of the appendicular skeleton), as well as gross destruction throughout the skeleton (Wimberger corner sign of the tibia: lytic osteomyelitis), rhinomaxillary destruction (gangosa), saddle nose, and gummatous lesions, and shape changes including true bowing and/or pseudobowing of the anterior tibiae, and high palatal arch. Here, we review the literature on dental stigmata and evaluate their relationship to diagnosis of congenital treponematosis to produce a diagnostic protocol.

Permanent dentition begins to form within the first few months of life (Scheuer and Black 2000). Typical tooth development is highly dependent on environmental, nutritional, and health factors of an individual, and disruptions impacting the formation of enamel during this time can cause permanent lesions and changes to tooth morphology. As teeth tend to preserve well in the archaeological record, the dental stigmata associated with congenital syphilis are regarded as the most reliable way to paleopathologically differentially diagnose the condition (Harper et al. 2011).

Individuals with congenital syphilis may develop infections of their tooth buds during the morphodifferentiation stage of tooth development (Figure 2), which impacts the formation of tooth enamel, changing the shape and size of the permanent dentition (Lauc et al. 2015; Sarnat and Shaw 1943). These changes can be separated into three distinct groups, each resulting in different morphological features and variable levels of diagnostic certainty (Table 2). A differential diagnosis beyond the dentition is available in Text S1. An in-depth rationale for the determination of diagnostic strength for each category of dental stigmata and their relationship to pathogenesis and pathophysiology is provided in Text S2.

## 3 | Results

Three non-adults were identified to have dental and/or skeletal lesions consistent with congenital treponematosis (2.4%,  $n = 3/123$ ). Two individuals were identified at Man Bac (4000–3500 BP), in northern Vietnam where prior research had demonstrated over 10% of the assemblage had lesions consistent with treponematosis. The final individual was identified at An Son (3800–3200 BP), in southern Vietnam. Skeletal preservation for the two individuals from Man Bac was excellent with more than 75% of the skeleton represented, whereas the individual from An Son was incomplete with only portions of the skull and fragments of postcranial remains preserved.

### 3.1 | MB05M5, Man Bac (4000–3500 BP)

MB05M5 was an 18-month-old at death with a complete skeleton, previously diagnosed with possible treponemal disease based on skeletal characteristics (see Vlok et al. 2020; lesions summarized in Table 3). MB05M5 displayed a small

**TABLE 1** | List of assemblages analyzed for this study.

Site	Period	Date (BP)	Sample size	References
Phia Vai (PV)	Pre-Neolithic	~10,000–7500	1 adult	Chung (2023); Cuong (2007)
Con Co Ngua (CCN)	Pre-Neolithic	6700–6200	54 non-adults 84 adults	Oxenham et al. (2018)
Man Bac (MB)	Neolithic	4000–3500	44 non-adults 26 adults	Oxenham et al. (2011); Vlok et al. (2020)
An Son (AS)	Neolithic	3800–3200	11 non-adults 8 adults	Bellwood et al. (2011); Willis and Oxenham (2015)
Vuon Chuoi (VC)	Metal Period	3050–2900	1 non-adult 4 adults	Seonbok et al. (2004)
Nui Nap (NN)	Metal Period	3000–2500 2400–2000 1750–1550	1 non-adult 14 adults	Oxenham et al. (2002); Oxenham (2006)
Giong Ca Vo (GCV)	Metal Period	2550–2050	2 non-adults 31 adults	Nguyen (2001)
Quy Chu (QC)	Metal Period	2600–2400	3 adults	Oxenham (2006); Oxenham (2016)
Chau Son (CS)	Metal Period	2400–2250	1 adult	Oxenham (2006); Oxenham (2016)
Doi Son (DS)	Metal Period	2200–1700	1 non-adult 1 adult	Oxenham (2006); Oxenham (2016)
Minh Duc (MD)	Metal Period	2200–1700	1 non-adult 2 adults	Oxenham (2006); Oxenham (2016)
Vinh Quang (VQ)	Metal Period	2200–1700	1 adult	Oxenham (2006); Oxenham (2016)
Duong Co (DC)	Metal Period	2200–1700	1 non-adult	Oxenham (2006); Oxenham (2016)
Duong Xa (DX)	Metal Period	2200–1700	1 adult	Oxenham (2006); Oxenham (2016)
Hoa Diem (HD)	Metal Period	2050–1750	7 non-adults 8 adults	Willis and Oxenham (2015)
Bai Coi (BC)	Metal Period	~2000–1800	1 adult	Vietnam National Museum of History (2009)
Total				123 non-adults 186 adults 309 individuals

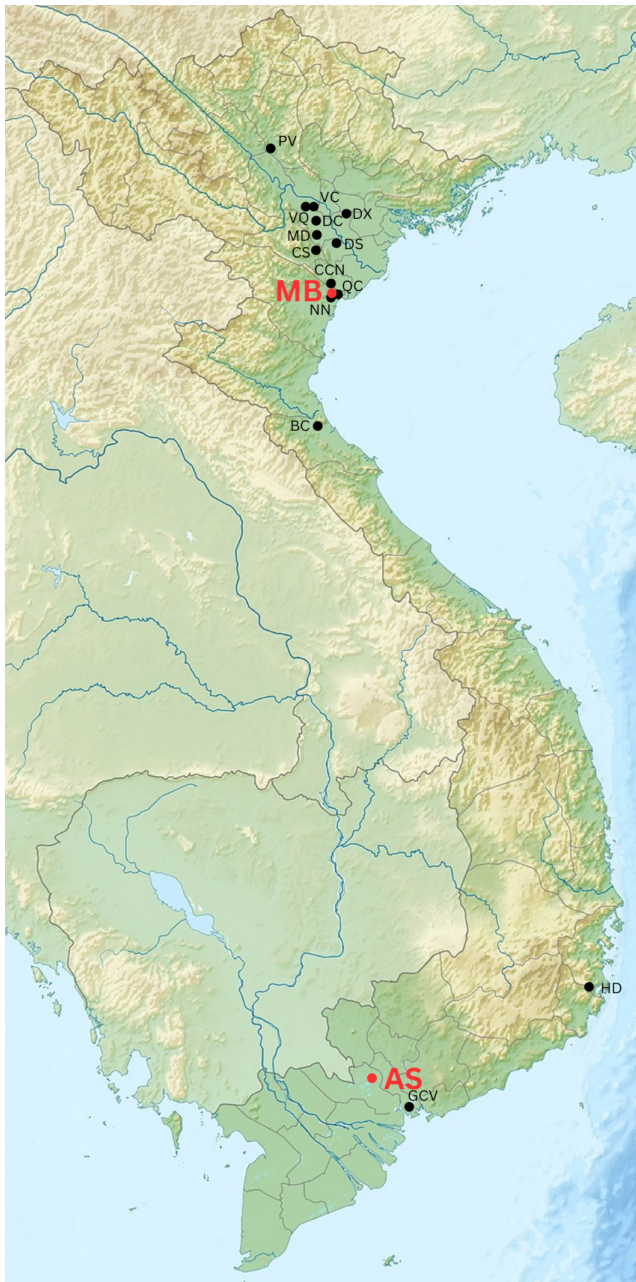“gummatous like” lesion extending from right distal humerus that was identical in appearance to the lesions observed in the tertiary treponemal cases from Man Bac. The small size of the lesion as well as other smaller superficial lytic lesions on the left tibia and right clavicle were also identified, but macroscopic identification precluded definitive classification of these lesions as gumma. Thus, at the time, Vlok et al. (2020) did not consider MB05M5 a probable case of treponemal disease. Reassessment of these lesions in 2024 under DinoLite identified that they were gummatous lesions (Figure 3). Minh et al. (this issue) also identified that MB05M5 has a significantly thickened frontal bone compared with others at Man Bac who died at a similar age (>1 SD) consistent with Parrot sign.

The reassessment of the individual identified dental stigmata that were strongly diagnostic for congenital treponemal

disease. MB05M5 displayed Moon's molars of the permanent maxillary and mandibular M1s as well as maxillary and mandibular deciduous m1s and m2s. The permanent molars were unerupted and were stained dark brown, indicating defective amelogenesis and/or dentinogenesis. Extreme dental decay of the deciduous maxillary incisors was also present. The combination of nine different pathological features of bone and teeth in MB05M5 is highly consistent with congenital treponematosi, and MB05M5 was determined to be a probable case.

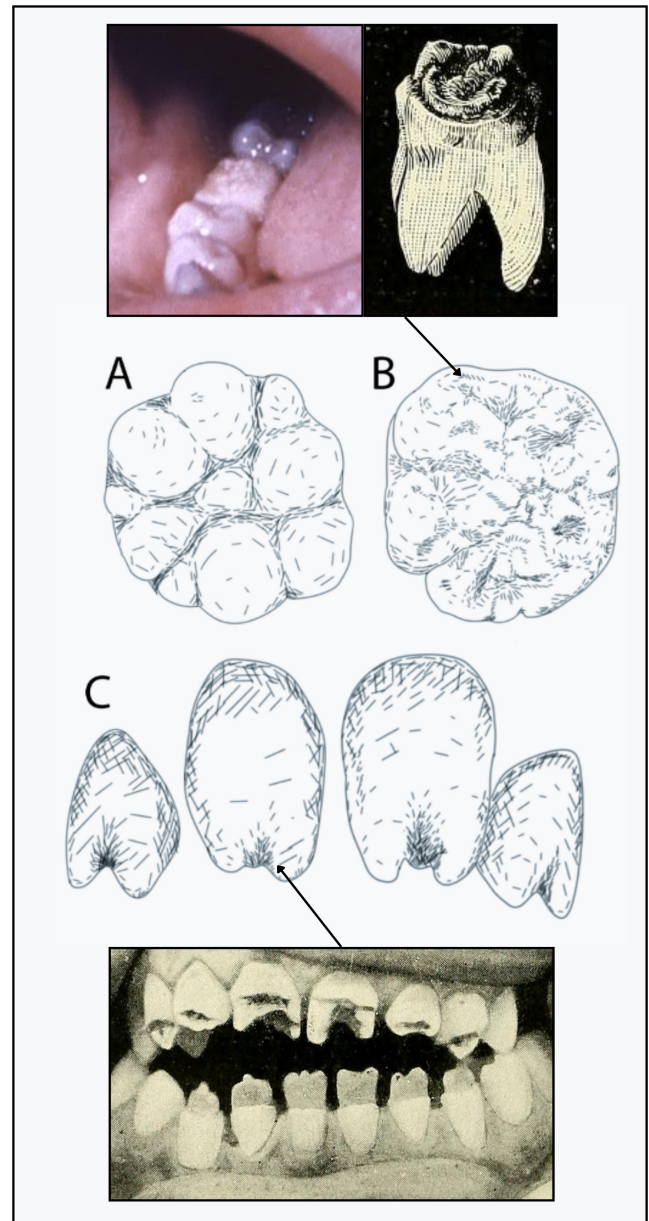
### 3.2 | MB05M25, Man Bac (4000–3500 BP)

MB05M25 is a non-adult approximately 5 years of age-at-death with a complete skeleton and well-preserved bone surfaces. This child was identified on preexisting photographs from



**FIGURE 1** | Site locations throughout Vietnam. Sites indicated in red are where cases of congenital treponematosi s was identified in this research. Image adapted from [https://commons.wikimedia.org/wiki/Category:Topographic\\_maps\\_of\\_Vietnam#/media/File:Vietnam\\_relief\\_location\\_map.jpg](https://commons.wikimedia.org/wiki/Category:Topographic_maps_of_Vietnam#/media/File:Vietnam_relief_location_map.jpg) (CC BY-SA 3.0). [Colour figure can be viewed at [wileyonlinelibrary.com](https://onlinelibrary.wiley.com/terms-and-conditions)]

the initial research in 2018 to have possible saddle nose deformity, which prompted a reanalysis of their skeleton. They were not identified by Vlok et al. (2020) to have treponemal disease. Their skeleton is complete with intact bone surfaces. Saddle nose deformity is exaggerated by expanded new bone on the nasal maxillae (goundou). There is extensive expansion of the entire maxillae inclusive of the alveolar bone. The anterior nasal spine is intact, and there is no porosity in the nasal region, thus ruling out leprosy. There is cortical expansion of the proximal tibiae (reminiscent of a node as characterized by Hackett (1976)) and left fibula shaft (the right is missing). The



**FIGURE 2** | The three most common dental stigmata of permanent teeth associated with congenital syphilis. (A) Moon's molars (photo not available), (B) Mulberry molars (Fournier's original illustrations for the molars described by him), and (C) Hutchinson's incisors. Fournier's canines are also observable in the right bottom image. Images in public domain from wikicommons via CDC and Fournier (1907). (Image: MV). [Colour figure can be viewed at [wileyonlinelibrary.com](https://onlinelibrary.wiley.com/terms-and-conditions)]

fibula has a clear enlarged cortex on the radiographs, but this is not the case with the tibiae. A similar finding was identified in a ~7-year-old from Man Bac (MB07H2M29) with tertiary treponemal disease who also had scurvy, which would have caused thinning of the cortices (Vlok et al. 2020). MB05M25 was also diagnosed with scurvy (Vlok et al. 2023). MB05M25 also appears to have Wimberger corner sign—destruction and radiolucency of the medial proximal tibiae, but this lesion is very subtle, and apparent focal lysis of the left tibial metaphysis (Figure 4D). Teeth presented with no stigmata. MB05M25's pathological features are consistent with possible congenital treponematosi s (Table 4; Figure 4).

**TABLE 2** | Protocol for diagnostic threshold of dental stigmata. Original descriptions of the stigmata provided. D, diagnostic; S, suggestive; SD, strongly diagnostic.

Dental stigmata	Diagnostic strength	Differential diagnosis	Reference
Hutchinson's incisors (permanent incisors, especially maxillary central incisors):	SD	Normal morphology, idiopathic amelogenesis defects, rickets, Nance-Horan syndrome	Snoddy et al. (2024); Cruickshank (1939); Hillson et al. (1998); Hutchinson (1863); Gjørup et al. (2017)
1. Loss of central mamelon			
2. Reduction of mesiodistal diameter towards the incisal edge			
3. Short and narrow			
Moon's (Bud) Molars (first permanent molar):	SD	Normal morphology, idiopathic amelogenesis defects, genetic mutation, Nance-Horan syndrome	Laugel-Haushalter et al. (2018); Hillson et al. (1998); Moon (1889); Pflüger (1924); Gjørup et al. (2017)
1. Reduced in size			
2. Dome-shaped			
3. Dwarfing of the central tubercle of each cusp			
4. Bud-shaped tooth			
Mulberry (Fournier's) Molars (first permanent molars):	D	Rickets, amelogenesis imperfecta, hypothyroidism, osteogenesis imperfecta, idiopathic amelogenesis or dentinogenesis defect	Cruickshank (1939); Hillson et al. (1998); Fournier (1884)
1. Linear or opaline horizontal defect across the crown			
2. Furrow-like imperfect formation of the occlusal surfaces			
3. Appears as if "corroded by acid" or "worm eaten wood" or "smaller tooth growing out of a larger one"			
4. Symmetrical			
Fournier's Canines:	D	Unknown	Cruickshank (1939); Hillson et al. (1998); Fournier (1884)
1. Hutchinson's incisors of the "cuspid's": crescentic notch			
2. Very rarely occur where the feature is absent from the central incisors.			
3. Defect occupies the edge of the tooth (rather than central as in Hutchinson's incisors)			
4. Can be accompanied with small "sinuosities" (pitting)			
5. Symmetrical			
Deciduous Moon's molars	D	Normal morphology, idiopathic amelogenesis defects, genetic mutation	Laugel-Haushalter et al. (2018); De Wilde (1943)
Deciduous Hutchinson's incisors	S	Rickets, Nance-Horan syndrome	Snoddy et al. (2024); Cruickshank (1939); Hillson et al. (1998); Gjørup et al. (2017)
Deciduous Mulberry molars (m1 and m2)	S	Rickets, amelogenesis imperfecta, idiopathic amelogenesis or dentinogenesis defect	De Wilde (1943)
Gross dental carious lesions (deciduous and permanent teeth)	S	Dietary, non-specific enamel hypoplasia	Cruickshank (1939)

**TABLE 3** | Skeletal and dental characteristics of MB05M5.

Lesion	Skeletal/dental elements	Diagnostic strength <sup>a</sup>
Focal superficial cavitation within expanded node of new bone	Proximal and distal tibiae	SD
Moons molars	Permanent maxillary and mandibular M1	SD
Deciduous Moon's molars	Deciduous maxillary and mandibular m1 and m2	D
Focal superficial cavitation not within expanded node of new bone	Distal right humerus, superior acromial end of the right clavicle	D
Nodes and expansions of new bone	Fibulae, tibiae, femora (bilateral)	S
Long bone pseudo-bowing/saber	Fibulae (bilateral)	S
Severe dental carious lesions	Anterior teeth	S
Dark staining (hypoplasia) of the unerupted permanent molars	M1s	S
Parrot sign (frontal bossing due to new bone)	Frontal bone	S

<sup>a</sup>D, diagnostic; S, suggestive; and SD, strongly diagnostic, following Vlok et al.'s (2020) diagnostic protocol and Vlok et al.'s (2023) clarification of diagnostic definitions.

### 3.3 | AS07H1M2, An Son (3800–3200 BP)

AS07H1M2 is a young child approximately 2.5 years at death. They are represented only by portions of the cranium, mandible, maxillary fragments, maxillary and mandibular dentition, left clavicle and scapula, rib fragments, and fragments of femoral shaft. AS07H1M2 presented with Moon-like molars on the deciduous maxillary second molars (Diagnostic) and mandibular first molars (Figure 5). The stigmata of the deciduous molars of AS07H1M2 are highly reminiscent (though less distinct) of the Moon's molars observed in MB05M5's deciduous teeth. AS07H1M2's dental pathological features are consistent with possible congenital treponematosi. However, dissimilar to Man Bac, no other individual at the site ( $n = 19$ ) presented with evidence of treponematosi.

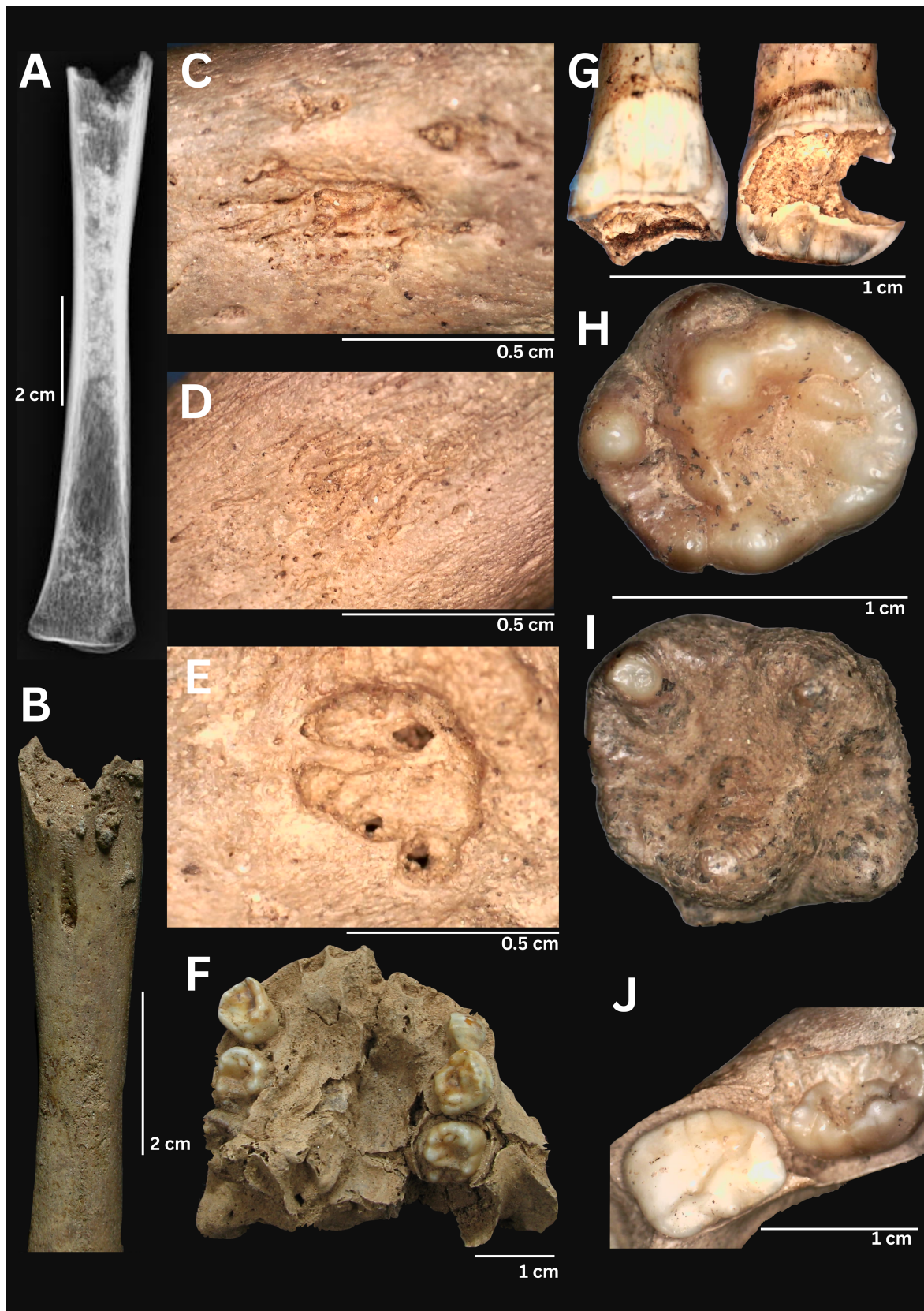
## 4 | Discussion

From an analysis of sites across Vietnam from the Pre-Neolithic to the Metal Periods, we identified cases consistent with treponematosi in only two sites, both dating to the Neolithic period. With the addition of this research, 11.4% ( $n = 8/70$ ) of Man Bac individuals presented with evidence of treponematosi. On the other hand, the case of dental stigmata from An Son instead remains tentative, as no other evidence for treponematosi was found at the site, nor was the individual's remains sufficiently well preserved to assess skeletal evidence of the disease to corroborate the dental stigmata.

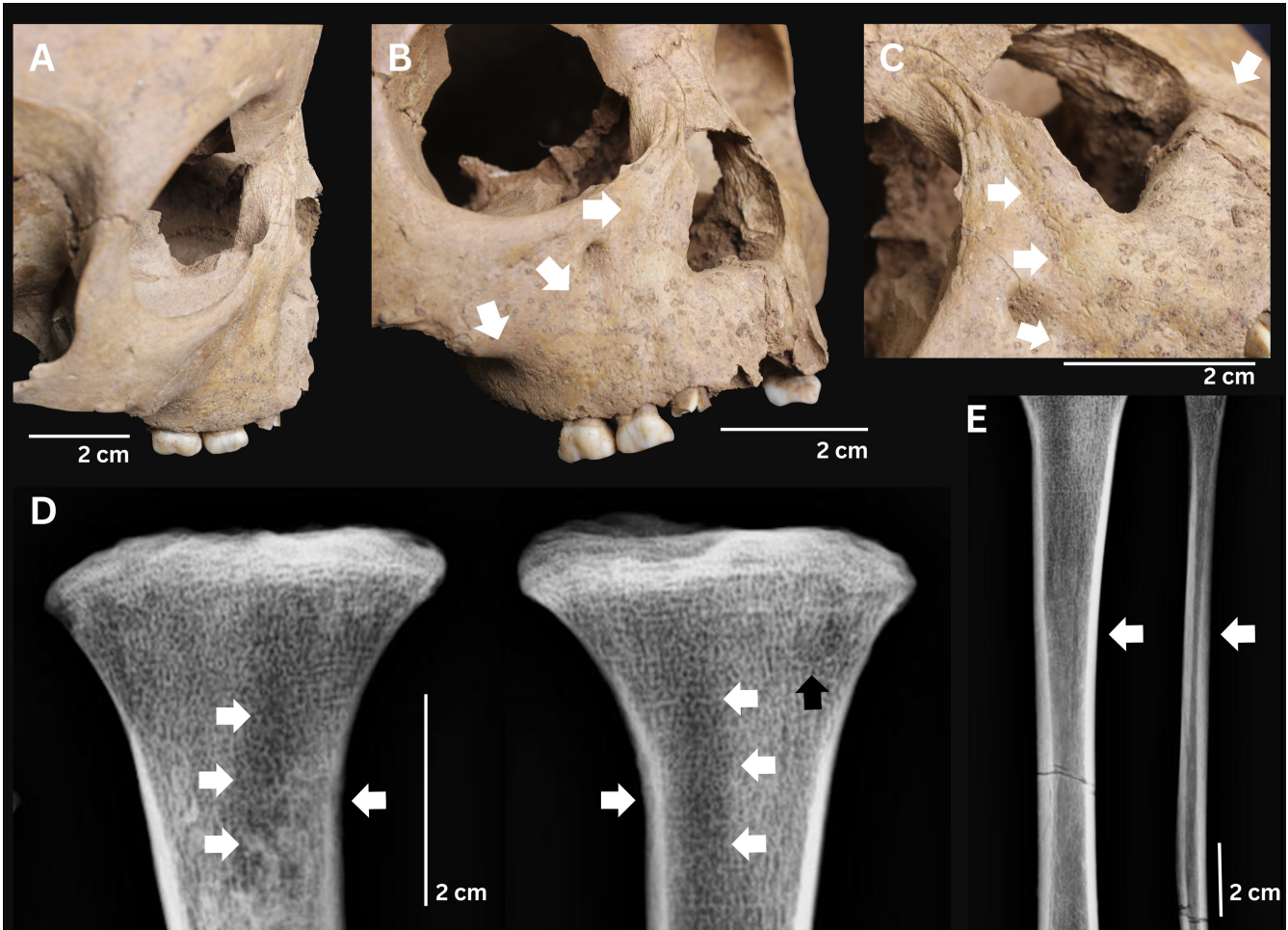
Man Bac in northern Vietnam is one of the most extensively studied archaeological human skeletal assemblages in Southeast Asia. Bioarchaeological research at the site has identified a highly dynamic population that was genetically and ethnically diverse (Matsumura and Oxenham 2014; McColl et al. 2018) with a complex social structure and highly developed cosmology (Oxenham et al. 2021). Like other Neolithic communities in the region, and globally, the community

experienced elevated levels of fertility and natural population growth (Domett and Oxenham 2011; McFadden et al. 2018) in the context of significant disease loads (Adams et al. 2021; Minh et al. [this issue](#); Oxenham et al. 2008; Oxenham et al. 2009; Vlok et al. 2021; Vlok et al. 2023; Vlok, Oxenham, Domett, et al. 2024; Vlok, Oxenham, McFadden, et al. 2024; Vlok et al. 2020). That said, it should be noted that the funerary treatment of Man Bac children references the considerable esteem in which their parents and/or community held them (Oxenham et al. 2008: 205). MB05M5, for example, was the only infant at Man Bac to be buried with ceramic pots. While such treatment in death likely also reflected care in life, it is difficult to reconstruct the type of treatment and/or care sick children received, although one particular case may throw light onto this issue. Man Bac Burial 9 was a core case study in the initial development of the Bioarchaeology of Care sub-discipline (Oxenham et al. 2009; Tilley and Oxenham 2011). This particular individual received constant, sophisticated, and intense care from a very early age until their eventual death in adulthood. It can only be assumed that most, if not all, children at Man Bac were the recipients of considerable care and attention while both healthy and ill. In contrast, other sites in Vietnam have received significantly less attention, which dramatically influences the understanding of disease antiquity of coastal Southeast Asia. This research has attempted to address the dearth in such research.

Prior work has suggested that the lack of research in Southeast Asia comparative with Europe and the Americas may be responsible for the scant evidence of treponematosi in the archaeological record of Southeast Asia (Buckley and Oxenham 2016; Buckley et al. 2019; Vlok et al. 2020). However, the extensive research that has been conducted in Thailand and now in Vietnam is beginning to present a picture of disease presence, perhaps exclusive to the eastern margins of the mainland. Where anthroponotic infectious diseases like tuberculosis and leprosy have been identified in ancient sites from Thailand, this has not been the case for treponematosi



**FIGURE 3** | Dental and skeletal lesions of MB05M5 consistent with congenital treponematosis. (A and B) Radiographs and image of the left tibia with node of new bone on the proximal shaft (around the region of the foramen). (C) Gummatous lesion on the right humerus (35 $\times$ ), (D) gummatous lesion on the right tibia (35 $\times$ ), and (E) gummatous lesion on the right clavicle (35 $\times$ ). (F) Maxilla with clear Moon's molars of deciduous m1s and m2s. (G) Right maxillary central and lateral incisor showing severe dental decay (25 $\times$ ). (H) Left maxillary deciduous m2 with budding (25 $\times$ ). (I) Left maxillary permanent M1 with budding and dark staining. (J) Right mandibular deciduous m1 and m2 with budding (25 $\times$ ). [Colour figure can be viewed at [wileyonlinelibrary.com](https://onlinelibrary.wiley.com)]



**FIGURE 4** | Skeletal lesions of MB05M25 consistent with congenital treponematosi. (A) Saddle nose in lateral view. (B) Saddle nose. Note the new bone expansion around the nasal region (goundou). (C) The expansion extends onto the body of the maxillae and alveolar bone. (D) Possible Wimberger corner sign. Note the radiolucency of the trabeculae and external cortices (localized osteolysis) of the medial proximal tibiae (white arrows). A focal lesion with a thin sclerotic margin also appears toward the lateral metaphyses consistent with descriptions and radiographs by Hackett (1951) of “focal rarefactions” (black arrow). Similar lesions were identified in a probable case of ~7-year-old child with treponematosi at Man Bac reported in Vlok et al. (2020). (E) Node-like expansion of the proximal tibia and fibula (white arrows). The expansion involves the cortices of the fibula but not the tibia (left shown). [Colour figure can be viewed at [wileyonlinelibrary.com](https://onlinelibrary.wiley.com/doi/10.1002/oa.70096)]

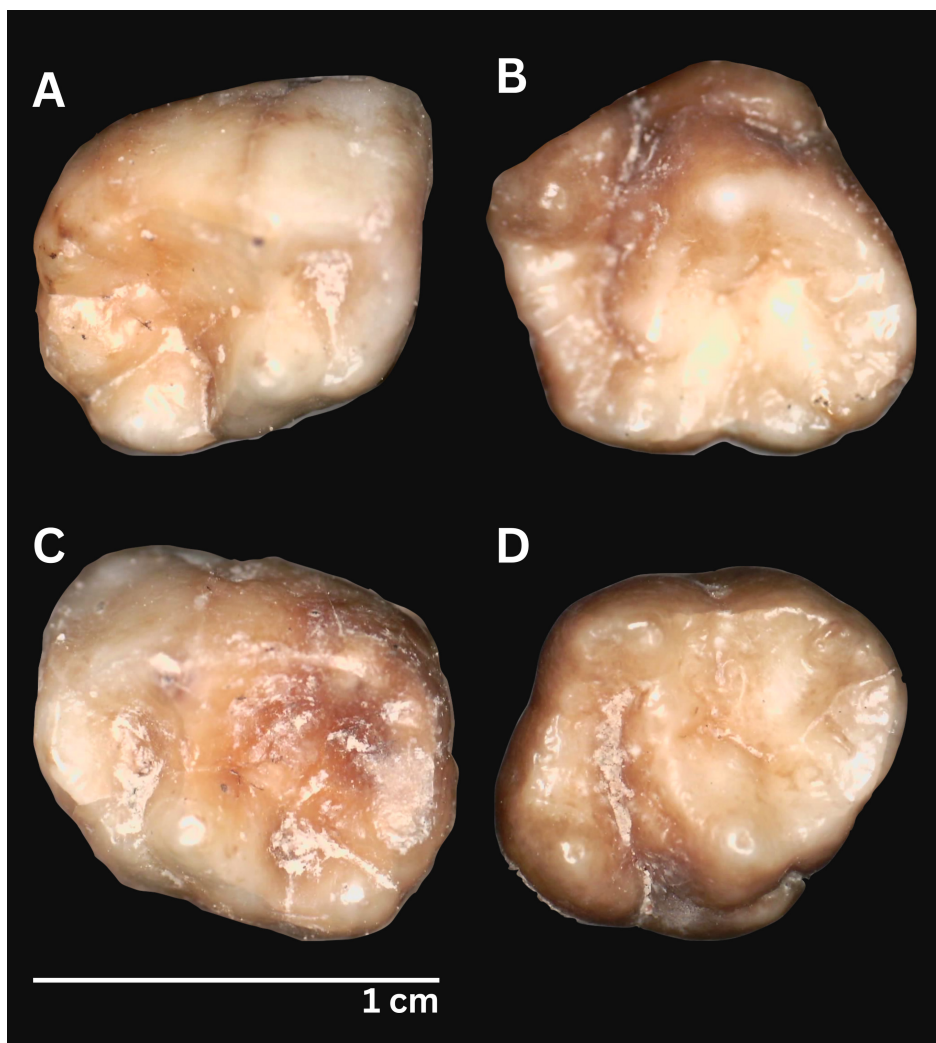
(Buckley et al. 2020; Tayles and Buckley 2004). Instead, the cases presented here appear to represent the most western distribution of treponematosi of the tropical Asia-Pacific region in antiquity. Another case from the Asia-Pacific dating to the Neolithic is reported by Yuwono et al. (this issue) from Alor Island, Indonesia (~3000 BP). Following this, cases from the Asia-Pacific are restricted to the last 1200 years (Buckley and Tayles 2003; Stewart and Spoehr 1952; Stodder and Trembly 1992; Trembly 1996; Zhou et al. 2022). Further work is still required to assess the presence of treponematosi throughout Laos, Cambodia, Myanmar, Malaysia, Indonesia, and the Philippines to comprehend the full extent of treponematosi in Southeast Asia's antiquity. For many of these countries, paleopathology is still in its infancy, but regional interest in the field is developing exponentially.

We make no assertions here that possible evidence of congenital treponematosi in Neolithic Vietnam indicates venereal syphilis (or sexual transmission) is present. The overall epidemiological signature at Man Bac overwhelmingly affects young

**TABLE 4** | Skeletal and dental characteristics of MB05M25.

Lesion	Skeletal/dental elements	Diagnostic strength
Saddle nose deformity	Maxillae	S
Thick periosteal new bone deposition and exostoses on the maxillae (goundou)	Maxillae	S
Wimberger corner sign?	Tibiae	D?
Nodes and expansions of new bone	Fibulae, tibiae (bilateral)	S

children and adolescents, which is highly consistent with non-venereal transmission (Vlok et al. 2020). As AS07H1M2 is the only individual from An Son to present with possible treponematosi, epidemiology cannot be assessed. Both sites represent the results of the migration of early farmers from modern



**FIGURE 5** | Dental stigmata (Moon's molars) of AS07H1M2 consistent with congenital treponematosis. (A) left deciduous mandibular m1 (25 $\times$ ), (B) left deciduous maxillary m2 (25 $\times$ ), (C) right deciduous mandibular m1, and (D) right deciduous maxillary m2. [Colour figure can be viewed at [wileyonlinelibrary.com](https://onlinelibrary.wiley.com)]

southern China into mainland Southeast Asia and subsequent interaction with local foragers who descend from the first wave of modern humans out of Africa, those that colonized the region at least 50,000 years ago (Bellwood et al. 2011). It is possible that this migration introduced treponemal disease to coastal Vietnam. With a better understanding that there were multiple waves of movement and migration across mainland Southeast Asia, island Southeast Asia, and Oceania, it is also possible that interaction between these two regions may have led to initial transmission from the islands (Carlhoff et al. 2021; Lipson et al. 2018; Matsumura et al. 2017; McColl et al. 2018; S. Oliveira, Nägele, et al. 2022). The wide distribution of artifacts such as baked clay ear ornaments, greenstone, and nephrite artifacts found in coastal Vietnam, southern China, and island Southeast Asia indicates connection between these areas at least 4000 years ago (Hung 2017). Why the disease does not persist in the subsequent Metal Periods requires future investigation but may be related to the rise of urbanization, reduced population growth, and a shift in social dynamics of communities influencing how households related to each other, which enabled spread of the disease amongst children during the Neolithic.

#### 4.1 | Limitations of the Study

We recognize that deciduous stigmata are poorly described in the foundational clinical literature, and we are limited by the lack of photographs accompanying descriptions of authors of the late 19th to early 20th century upon which most dental stigmata research relies. We emphasize that our research here is for the sole purpose of exploring a new avenue for diagnosis especially in regions outside the western hemisphere that have received less clinical attention and may be expected to show differences in skeletal phenotypes compared with the classical literature. We welcome future research that will no doubt refine or even refute the findings we have observed.

There are still many regions of Vietnam that remain to be explored in future research through both traditional macroscopic and bio-molecular means to better characterize treponematosis in deep history. Archaeological research in central Vietnam is comparatively less intense than in the northern region, which impacts the distribution of available assemblages to study (see Figure 1). As such, the spatiotemporal distribution of treponematosis in deep antiquity will continue to develop in the future.

## 5 | Conclusions

An extensive analysis of sites across Vietnam dating from 10,000 to 1000 BP with a new diagnostic protocol for dental stigmata has revealed three individuals with pathology consistent with congenital treponematosi. The two sites are coastal Neolithic sites (4000–3200 BP) in northern and southern Vietnam. No other cases, congenital or acquired, were identified, which, along with extensive research in Thailand in the last two decades, suggests that treponematosi may not have been endemic throughout mainland Southeast Asia in deep antiquity, which contrasts that of Oceania. Further work is needed in Southeast Asian countries where bioarcheological research is still minimal to support this hypothesis.

### Acknowledgments

Permissions to access the collections were granted in 2024 by the Institute of Archaeology in Hanoi, Ho Chi Minh City History Museum, Long An Provincial Museum, Tuyen Quang Provincial Museum, and Khan Hoa Museum. We would like to thank Dr. Ngo Anh Son, Dr. Bui Van Khanh, and Dr. Nellissa Ling for their assistance with the radiographs. This work was supported by the National Geographic Society (EC-54332R-18), Royal Society of New Zealand Skinner Fund, University of Otago Doctoral Scholarship, Wenner Gren Foundation Wadsworth Fellowship (WIF-294), the Australian Research Council (DP110101097, FT120100299), Sydney Southeast Asia Workshop grant, financial support from the Thai Fine Arts Department, and the Faculty of Archaeology, Silpakorn University, Thailand, and an American Association of Biological Anthropologists Cobb Professional Development grant. Open access publishing facilitated by Charles Sturt University, as part of the Wiley - Charles Sturt University agreement via the Council of Australasian University Librarians

### Conflicts of Interest

The authors declare no conflicts of interest.

### Data Availability Statement

Data are available on request to authors.

### References

Adams, A. B., S. E. Halcrow, C. King, et al. 2021. "We're All in This Together: Accessing the Maternal-Infant Relationship in Prehistoric Vietnam." In *The Family in Past Perspective: an Interdisciplinary Exploration of Familial Relationships Through Time*, edited by E. J. Kendall and R. Kendall, 191–221. Routledge Taylor & Francis Group.

Arora, N., V. J. Schuenemann, G. Jäger, et al. 2016. "Origin of Modern Syphilis and Emergence of a Pandemic *Treponema pallidum* Cluster." *Nature Microbiology* 2, no. 1: 1–6.

Baker, B. J., G. Crane-Kramer, M. W. Dee, et al. 2020. "Advancing the Understanding of Treponemal Disease in the Past and Present." *American Journal of Physical Anthropology* 171: 5–41.

Barquera, R., T. L. Sitter, C. L. Kirkpatrick, et al. 2025. "Ancient Genomes Reveal a Deep History of Treponemal Disease in the Americas." *Nature* 640: 186–193.

Bellwood, P., M. F. Oxenham, B. C. Hoang, et al. 2011. "An Son and the Neolithic of Southern Vietnam." *Asian Perspectives* 50, no. 1: 144–175. <https://doi.org/10.1353/asi.2011.0007>.

Benoit, P., L. Tennenhouse, A. Lapple, et al. 2022. "Syphilis Resurgence in Canada: Congenital Syphilis Re-Emergence in Winnipeg, Manitoba." *Canada Communicable Disease Report* 48, no. 2–3: 89.

Buckley, H., K. Domett, S. Halcrow, et al. 2020. "An Initial Report on Health and Disease at Non Ban Jak." Fine Arts Department, Thailand.

Buckley, H., and M. F. Oxenham. 2016. "Bioarchaeology in the Pacific Islands: a Temporal and Geographical Examination of Nutritional and Infectious Disease." In *The Routledge Handbook of Bioarchaeology in Southeast Asia and the Pacific*, edited by M. F. Oxenham and H. Buckley, 363–388. Routledge.

Buckley, H. R., and N. Tayles. 2003. "The Functional Cost of Tertiary Yaws (*Treponema pertenue*) in a Prehistoric Pacific Island Skeletal Sample." *Journal of Archaeological Science* 30, no. 10: 1301–1314.

Buckley, H. R., M. Vlok, K. Domett, H. H. Trinh, and M. Oxenham. 2019. "The Antiquity of Treponemal Disease in the Asia-Pacific Regions: Implications for Settlement History." *American Journal of Physical Anthropology* 168: 31.

Carlhoff, S., A. Duli, K. Nägele, et al. 2021. "Genome of a Middle Holocene Hunter-Gatherer From Wallacea." *Nature* 596, no. 7873: 543–547.

Chung, T. N. 2023. "Hang Phia Vai (Tuyen Quang)- Di Tich Hoa Binh Tieu Bieu o Mien Nui Dong Bac Viet Nam." *Nhân Lực Khoa Học Xã Hội*, 97–104.

Cooper, J. M., and P. J. Sánchez. 2018. "Congenital Syphilis." *Seminars in Perinatology*.

Cruikshank, L. G. 1939. "The Dental Stigmata of Congenital Syphilis." *Journal of the Royal Society of Medicine* 32, no. 4: 343–348.

Cuong, N. L. 2007. "Unique Burial Practice by Ancient Cavemen of the Hoa Binh Civilization in Vietnam." *Anthropologischer Anzeiger* 65, no. 2: 129–135.

De Wilde, H. 1943. "Stigmata of Congenital Syphilis in the Deciduous Dentition." *American Journal of Orthodontics and Oral Surgery* 29, no. 7: B368–B376.

Dofitas, B. L., M. C. Batac, and J. H. Richardus. 2022. "Finding Yaws among Indigenous People: Lessons From Case Detection Surveys in Luzon and Visayas Island Groups of the Philippines." *American Journal of Tropical Medicine and Hygiene* 108, no. 2: 305.

Dofitas, B. L., S. P. Kalim, C. B. Toledo, and J. H. Richardus. 2022. "Yaws in the Philippines: a Clinico-Seroprevalence Study of Selected Communities in Mindanao." *PLoS Neglected Tropical Diseases* 16, no. 6: e0010447.

Domett, K. M., and M. F. Oxenham. 2011. "The Demographic Profile of the Man Bac Cemetery Sample." In *Man Bac: the Excavation of a Neolithic Site in Northern Vietnam, The Biology. Terra Australis*, edited by M. F. Oxenham, H. Matsumura, and N. Kim Dung, vol. 33, 9–20. ANU ePress.

Engelhardt, H. K. 1959. "A Study of Yaws (Does Congenital Yaws Occur?)" *Journal of Tropical Medicine and Hygiene* 62, no. 10: 238–240.

Foles, A. I., M. E. Dias, M. Figueiredo, and M. Marçal. 2024. "Congenital Syphilis: the Re-Emergence of a Forgotten Disease." *BMJ Case Reports* 17, no. 1: e257694.

Fournier, A. 1884. "Syphilitic Teeth." *The Dental Cosmos: a Monthly Record of Dental Science*.

Fournier, E. 1907. *Recherches et diagnostic de l'hérédo-syphilis tardive*. Masson.

Gjørup, H., D. Haubek, P. Jacobsen, and J. R. Ostergaard. 2017. "Nance-Horan Syndrome—the Oral Perspective on a Rare Disease." *American Journal of Medical Genetics Part A* 173, no. 1: 88–98.

Grin, E. I. 1952. "Endemic Syphilis in Bosnia: Clinical and Epidemiological Observations on a Successful Mass-Treatment Campaign." *Bulletin of the World Health Organization* 7, no. 1: 1.

Grin, E. I. 1956. "Endemic Syphilis and Yaws." *Bulletin of the World Health Organization* 15, no. 6: 959–973.

- Hackett, C. J. 1951. *Bone Lesions of Yaws in Uganda*. Blackwell Scientific Publications.
- Hackett, C. J. 1976. *Diagnostic Criteria of Syphilis, Yaws and Treponarid (Treponematoses) and of Some Other Diseases in Dry Bones*. Springer.
- Harper, K. N., P. S. Ocampo, B. M. Steiner, et al. 2008. "On the Origin of the Treponematoses: a Phylogenetic Approach." *PLoS Neglected Tropical Diseases* 2, no. 1: e148.
- Harper, K. N., M. K. Zuckerman, M. L. Harper, J. D. Kingston, and G. J. Armelagos. 2011. "The Origin and Antiquity of Syphilis Revisited: an Appraisal of Old World Pre-Columbian Evidence for Treponemal Infection." *American Journal of Physical Anthropology* 146, no. S53: 99–133. <https://doi.org/10.1002/ajpa.21613>.
- Hill, K. R. 1953. "Non-Specific Factors in the Epidemiology of Yaws." *Bulletin of the World Health Organization* 8, no. 1–3: 17.
- Hillson, S., C. Grigson, and S. Bond. 1998. "Dental Defects of Congenital Syphilis." *American Journal of Physical Anthropology* 107, no. 1: 25–40.
- Hung, H.-c. 2017. "Cultural Interactions in Mainland and Island Southeast Asia and Beyond, 2000 BC–AD 200." In *Handbook of East and Southeast Asian Archaeology*, 633–658. Springer.
- Hutchinson, J. 1863. "A Clinical Memoir on Certain Diseases of the Eye and Ear, Consequent on Inherited Syphilis".
- LaFond, R. E., and S. A. Lukehart. 2006. "Biological Basis for Syphilis." *Clinical Microbiology Reviews* 19, no. 1: 29–49.
- Lauc, T., C. Fornai, Z. Premuzić, et al. 2015. "Dental Stigmata and Enamel Thickness in a Probable Case of Congenital Syphilis From XVI Century Croatia." *Archives of Oral Biology* 60, no. 10: 1554–1564.
- Laugel-Haushalter, V., S. Morkmued, C. Stoetzel, et al. 2018. "Genetic Evidence Supporting the Role of the Calcium Channel, CACNA1S, in Tooth Cusp and Root Patterning." *Frontiers in Physiology* 9: 1329.
- Lipson, M., O. Cheronet, S. Mallick, et al. 2018. "Ancient Genomes Document Multiple Waves of Migration in Southeast Asian Prehistory." *Science* 361, no. 6397: 92–95. <https://doi.org/10.1126/science.aat3188>.
- Majander, K., S. Pfrengle, A. Kocher, et al. 2020. "Ancient Bacterial Genomes Reveal a High Diversity of *Treponema pallidum* Strains in Early Modern Europe." *Current Biology* 30, no. 19: 3788–3803.
- Major, R. H. 1965. *Classic Descriptions of Diseases: With Biographical Sketches of the Authors*. 3rd edition ed. Charles C Thomas.
- Marks, M., D. Lebari, A. W. Solomon, and S. P. Higgins. 2015. "Yaws." *International Journal of STD & AIDS* 26, no. 10: 696–703.
- Matsumura, H., H.-C. Hung, L. Zhen, and K. I. Shinoda. 2017. "Bio-Anthropological Studies of Early Holocene Hunter-Gatherer Sites at Huiyaotian and Liyupo in Guangxi, China." National Museum of Nature and Science Tokyo.
- Matsumura, H., and M. Oxenham. 2014. "Demographic Transitions and Migration in Prehistoric East/Southeast Asia Through the Lens of Nonmetric Dental Traits." *American Journal of Physical Anthropology* 155, no. 1: 45–65. <https://doi.org/10.1002/ajpa.22537>.
- McColl, H., F. Racimo, L. Vinner, et al. 2018. "The Prehistoric Peopling of Southeast Asia." *Science* 361, no. 6397: 88–92. <https://doi.org/10.1126/science.aat3628>.
- McFadden, C., H. Buckley, S. E. Halcrow, and M. F. Oxenham. 2018. "Detection of Temporally Localized Growth in Ancient Southeast Asia Using Human Skeletal Remains." *Journal of Archaeological Science* 98: 93–101. <https://doi.org/10.1016/j.jas.2018.08.010>.
- Meyer, C., C. Jung, T. Kohl, A. Poenicke, A. Poppe, and K. Alt. 2002. "Syphilis 2001: a Palaeopathological Reappraisal." *HOMO-Journal of Comparative Human Biology* 53, no. 1: 39–58.
- Minh, T. T., K. A. Plomp, H. T. Hiep, et al. this issue. "Cranio-metric Analysis of Thalassaemic Individuals from Neolithic Northern Vietnam (4000–3500BP)." *International Journal of Osteoarchaeology*.
- Mitjà, O., K. Asiedu, and D. Mabey. 2013. "Yaws." *Lancet* 381, no. 9868: 763–773.
- Moon, H. 1889. "On Irregular and Defective Tooth Development." Odontological Society.
- Nguyen, K. D. 2001. "Jewellery from Late Prehistoric Sites Recently Excavated in South Viet Nam." *Bulletin of the Indo-Pacific Prehistory Association* 21: 107–113.
- Oliveira, R., A. Strauss, R. Murrieta, C. Castro, and A. Matioli. 2022. "An Early Holocene Case of Congenital Syphilis in South America." *International Journal of Osteoarchaeology* 33: 164–169. <https://doi.org/10.1002/oa.3180>.
- Oliveira, S., K. Nägele, S. Carlhoff, et al. 2022. "Ancient Genomes From the Last Three Millennia Support Multiple Human Dispersals Into Wallacea." *Nature Ecology & Evolution* 6, no. 7: 1024–1034.
- Orbe-Orihuela, Y. C., M. Á. Sánchez-Alemán, A. Hernández-Pliego, C. V. Medina-García, and D. N. Vergara-Ortega. 2022. "Syphilis as Re-Emerging Disease, Antibiotic Resistance, and Vulnerable Population: Global Systematic Review and Meta-Analysis." *Pathogens* 11, no. 12: 1546.
- Ortner, D. J. 2005. "Foreword." In *The Myth of Syphilis*, edited by M. L. Powell and D. C. Cook, 19–30. University Press of Florida.
- Oxenham, M. F. 2006. "Biological Responses to Change in Prehistoric Viet Nam." *Asian Perspectives* 45, no. 2: 212–239.
- Oxenham, M. F. 2016. *Bioarchaeology of Ancient Northern Vietnam*. Vol. 2781. Archaeopress.
- Oxenham, M. F., T. H. Hiep, H. Matsumura, et al. 2021. "Identity and Community Structure in Neolithic Man Bac, Northern Vietnam." *Archaeological Research in Asia* 26: 100282.
- Oxenham, M. F., C. Locher, N. L. Cuong, and N. K. Thuy. 2002. "Identification of *Areca catechu* (Betel Nut) Residues on the Dentitions of Bronze Age Inhabitants of Nui Nap, Northern Vietnam." *Journal of Archaeological Science* 29, no. 9: 909–915.
- Oxenham, M. F., H. Matsumura, K. Domett, et al. 2008. "Health and the Experience of Childhood in Late Neolithic Viet Nam." *Asian Perspectives* 47: 190–209.
- Oxenham, M. F., H. Matsumura, and N. Kim Dung. 2011. *Man Bac: the Excavation of a Neolithic Site in Northern Vietnam The Biology*, Terra Australis. Vol. 33. ANU ePress.
- Oxenham, M. F., L. Tilley, H. Matsumura, et al. 2009. "Paralysis and Severe Disability Requiring Intensive Care in Neolithic Asia." *Anthropological Science* 117, no. 2: 107–112. <https://doi.org/10.1537/ase.081114>.
- Oxenham, M. F., H. Trinh, A. Willis, et al. 2018. "Between Foraging and Farming: Strategic Responses to the Holocene Thermal Maximum in Southeast Asia." *Antiquity* 92, no. 364: 940–957.
- Pálfi, G., O. Dutour, M. Borreani, J. P. Brun, and J. Berato. 1992. "Pre-Columbian Congenital Syphilis From the Late Antiquity in France." *International Journal of Osteoarchaeology* 2, no. 3: 245–261.
- Peeling, R. W., D. Mabey, M. L. Kamb, X.-S. Chen, J. D. Radolf, and A. S. Benzaken. 2017. "Syphilis." *Nature Reviews. Disease Primers* 3: 17073.
- Pflüger, H. 1924. "Eine für Lues congenita charakteristische Formveränderung (Knospenform) an dem ersten Molaren." *Münchener Medizinische Wochenschrift* 71: 605.
- Pla-Diaz, M., L. Sánchez-Busó, L. Giacani, et al. 2022. "Evolutionary Processes in the Emergence and Recent Spread of the Syphilis Agent, *Treponema pallidum*." *Molecular Biology and Evolution* 39, no. 1: msab318.
- Powell, M. L., and D. C. Cook. 2005a. *The Myth of Syphilis: the Natural History of Treponematoses in North America*. University Press of Florida.
- Powell, M. L., and D. C. Cook. 2005b. "Treponematoses: Inquiries Into the Nature of a Protean Disease." In *The Myth of Syphilis: the Natural*

- History of Treponematosi in North America*, edited by M. L. Powell and D. C. Cook, 9–62. University of Florida Press.
- Ricono, M. 1916. “Yaws and Similar Diseases in South Africa”.
- Román, G. C., and L. N. Román. 1986. “Occurrence of Congenital, Cardiovascular, Visceral, Neurologic, and Neuro-Ophthalmologic Complications in Late Yaws: a Theme for Future Research.” *Reviews of Infectious Diseases* 8, no. 5: 760–770.
- Sarnat, B. G., and N. G. Shaw. 1943. “Dental Development in Congenital Syphilis.” *American Journal of Orthodontics and Oral Surgery* 29, no. 5: B270–B284.
- Scheuer, L., and S. Black. 2000. *Developmental Juvenile Osteology*. Academic Press.
- Seonbok, Y., J. L. June, M. D. Lam, and K. T. Nguyen. 2004. “AMS Dating From Archaeological Sites in Vietnam.” *VNU Journal of Science: Social Sciences and Humanities* 20, no. 3E: 33–36.
- Smith-Guzmán, N. E. 2022. “A Paleoepidemiological Approach to the Challenging Differential Diagnosis of an Isolated 1500-Year-Old Anomalous Molar From Panamá.” *International Journal of Paleopathology* 39: 1–13.
- Snoddy, A. M. E., H. Shaw, S. Newman, et al. 2024. “Vitamin D Status in Post-Medieval Northern England: Insights From Dental Histology and Enamel Peptide Analysis at Coach Lane, North Shields (AD 1711–1857).” *PLoS ONE* 19, no. 1: e0296203.
- Stewart, T. D., and A. Spoehr. 1952. “Evidence on the Paleopathology of Yaws.” *Bulletin of the History of Medicine* 26, no. 6: 538–553.
- Stodder, A. L., and D. L. Trembly. 1992. “Paleoepidemiology and Paleopathology of Treponematosi in Pre- and Proto-Historic Villages in Western Micronesia.” *American Journal of Physical Anthropology Supplement* 14: 157.
- Tayles, N., and H. R. Buckley. 2004. “Leprosy and Tuberculosis in Iron Age Southeast Asia?” *American Journal of Physical Anthropology* 125, no. 3: 239–256. <https://doi.org/10.1002/ajpa.10378>.
- Tilley, L., and M. F. Oxenham. 2011. “Survival Against the Odds: Modeling the Social Implications of Care Provision to Seriously Disabled Individuals.” *International Journal of Paleopathology* 1, no. 1: 35–42. <https://doi.org/10.1016/j.ijpp.2011.02.003>.
- Trembly, D. L. 1996. “Treponematosi in Pre-Spanish Western Micronesia.” *International Journal of Osteoarchaeology* 6, no. 4: 397–402.
- Vietnam National Museum of History 2009. “The Mutual Influence Dong Son – Sa Huynh in the Archaeological Site of Bai Coi (Nghì Xuan – Ha Tinh) (Monograph).”
- Vlok, M., H. R. Buckley, J. J. Miskiewicz, et al. 2021. “Forager and Farmer Evolutionary Adaptations to Malaria Evidenced by 7000 Years of Thalassemia in Southeast Asia.” *Scientific Reports* 11: 5677.
- Vlok, M., M. Oxenham, K. Domett, et al. 2023. “Scurvy in the Tropics: Evidence for Increasing Non-Adult Micronutrient Deficiency With the Transition to Agriculture in Northern Vietnam.” *American Journal of Biological Anthropology* 180, no. 4: 715–732. <https://doi.org/10.1002/ajpa.24698>.
- Vlok, M., M. Oxenham, K. Domett, et al. 2024. “High Prevalence of Adult and Nonadult Scurvy in an Early Agricultural Transition Site From Mainland Southeast Asia Was Associated With Decreased Survivorship.” *American Journal of Biological Anthropology* 185, no. 2: e25011.
- Vlok, M., M. Oxenham, C. McFadden, et al. 2024. “Hypomineralization Disorder in Tropical Southeast Asia During the Agricultural Revolution: Analysis of Morbidity and Mortality.” *International Journal of Osteoarchaeology* 34, no. 2: e3288.
- Vlok, M., M. F. Oxenham, K. Domett, et al. 2020. “Two Probable Cases of Infection With *Treponema pallidum* During the Neolithic Period in Northern Vietnam (ca. 2000–1500 B.C.).” *Bioarchaeology International* 4, no. 1: 15–39.
- White, C., and G. Phua. 2024. “The Resurgence of Syphilis in Australia.” *Australian Journal of General Practice* 53, no. 3: 133–137.
- Willis, A., and M. Oxenham. 2015. “Reconstructing Diet at An So’n and Hòa Diêm.” *The Routledge Handbook of Bioarchaeology in Southeast Asia and the Pacific Islands*, 137.
- Yuwono, P., M. Vlok, R. Joannes-Boyau, et al. this issue. “A Possible Case of Congenital Treponemal Disease in Wallacea: Implications for Early Health and Migration During the Neolithic Expansion.” *International Journal of Osteoarchaeology*.
- Zhou, Y., G. Gao, X. Zhang, et al. 2022. “Identifying Treponemal Disease in Early East Asia.” *American Journal of Biological Anthropology* 178, no. 3: 530–543.

### Supporting Information

Additional supporting information can be found online in the Supporting Information section. **Text S1:** Differential diagnosis of dental and skeletal characteristics. **Figure S1:** Macroscopic appearance of cortical expansions from rickets at Man Bac (MB07H1M5). While the diaphysis is thick (confirmed via radiographs), the bone is clearly poorly mineralized in appearance, and metaphyseal changes are associated supporting a rickets diagnosis. The cortical expansions are not localized into nodes as is the case for MB05M5 and MB05M25. This individual displayed a suite of diagnostic characteristics of the cranium and long bones consistent with a diagnosis of probable rickets (Vlok et al. 2024). **Text S2:** Determining the diagnostic strength of dental stigmata in treponematosi.