

Genomic Characterisation of a Novel Psittacid Herpesvirus from Indian Ringnecks (*Psittacula krameri*)



Michelle Sutherland¹, Subir Sarker², Shane R. Raidal³

1. Burwood Bird and Animal Hospital, 128 Highbury Rd., Burwood, Vic. 3125
2. Department of Physiology, Anatomy and Microbiology, School of Life Sciences, La Trobe University, Bundoora, Vic. 3086
3. Veterinary Diagnostic Laboratory, Charles Sturt University, Wagga Wagga, NSW. 2678

Introduction

Avian herpesviruses comprise a wide variety of pathogens and may infect a variety of hosts, having a propensity to infect epithelial cells, lymphatic tissue and nervous tissue. In natural hosts, herpesvirus disease is often mild; however cross-species infection may result in severe and fatal disease (Kaleta and Doherty, 2007). Herpesvirus sub-families include alpha-, beta- and gamma-herpesviruses. Alpha-herpesviruses are associated with rapid viral replication, the ability to cause host cell lysis, and the capacity to establish latent infections (Ritchie and Carter, 1995; Lazic et al., 2008). Alpha-herpesviruses of the genus *Iltovirus* have been documented to cause respiratory disease in birds. *Gallid alphaherpesvirus-1* (GaHV-1) causes infectious laryngotracheitis (ILT) in gallinaceous birds. This manifests as either a mild form associated with moderate mucoid tracheitis, conjunctivitis, and laryngeal and tracheal haemorrhage, or a severe form causing diphtheritic plaque formation in the larynx and trachea that may extend into the lungs and air sacs (Cover et al., 1958; Garcia et al., 2013). *Psittacid alphaherpesvirus-1* (PsHV-1; formerly known as Pacheco's Disease) causes an acute, highly contagious and frequently fatal respiratory disease in parrots. Particularly affecting cockatoos, macaws and Amazon parrots, the virus targets lymphocytes and hepatocytes, resulting in severe tissue necrosis and the formation of syncytial cells (Panhigrahy and Grumbles, 1984; Thureen and Keeler, 2006). In addition, herpesvirus infections with a tropism for the respiratory tract of parakeets have been reported in Bourke's parrots (*Neopsephotus bourkii*) and Indian ringnecks (*Psittacula krameri*) (Helfer et al., 1980; Tsai et al., 1993; Raidal et al., 1995; Lazic et al., 2008; Shivaprasad and Phalen, 2012). Typical histological lesions include intranuclear inclusion bodies in the epithelial and syncytial cells of the trachea, bronchi, air capillaries and air sacs, with an absence of upper respiratory tract disease (Raidal et al., 1995; Lazic et al., 2008; Shivaprasad and Phalen, 2012). Phylogenetic analysis of the virus affecting *N. bourkii* has suggested a novel Psittacid alphaherpesvirus in the genus *Iltovirus*, with the suggested name *Psittacid alphaherpesvirus-3* (PsHV-3)

(Shivaprasad and Phalen, 2012). However, this has yet to be ratified by the International Committee on Taxonomy of Viruses (ICTV, 2016). The purpose of this paper is to report the clinical, cytological, pathological findings and preliminary viral genomic analysis of a novel herpesvirus causing disease in Indian ringneck parrots (*P. krameri*) in Australia.

Case Report

A high morbidity/mortality disease process caused deaths in an aviary flock of Indian ringneck parrots in Victoria during the breeding season. The aviary contained approximately 300 birds, consisting of 160 breeding adults (80 pairs), 115 chicks and around 25 non-breeding birds. 120 adult birds (116 breeding adults) and 80 chicks were affected, giving a morbidity rate of 75% in adults and 69.5% in chicks. The clinical presentation was fatal in 85 adults (70% affected birds; all breeding adult) and 60 (75%) of affected chicks. The owner reported affected birds were either found dead with no prior signs of illness, or showed evidence of respiratory disease with signs including inspiratory dyspnoea, stridor, and mucus in the upper respiratory tract. All age groups were affected. Two representative birds (one juvenile, one adult) were presented for post-mortem examination. On gross necropsy, lesions included pericardial haemorrhage and pericardial sac distension; left atrial enlargement; diffuse consolidation, congestion and red discoloration of the lungs; thickened air sacs with cream/yellow discoloration, and pale kidneys. Heart and lung tissue were submitted to an external laboratory (Idexx Laboratories, 124/45 Gilby Rd, Mount Waverley, Vic 3149) for bacterial culture and sensitivity testing. No bacterial aerobes or anaerobes were isolated. Impression smears of lung, liver and renal tissue were made. Fresh tissue samples were taken from the lung, liver and kidney and stored frozen at -18°C. Visceral organs and brain tissue were fixed in 10% buffered formalin were collected for histopathological examination, along with impression smears for cytology.

Cytological examination of the lung impression smears

revealed large numbers of syncytia, some containing 20-30 nuclei, ballooning degeneration of nuclei, and margined chromatin. A moderate number of heterophils and macrophages were also present. Impression smears of the liver and kidney appeared normal.

On histopathological examination, samples from both birds demonstrated extensive acute inflammation of the bronchi and parabronchi with haemorrhage, exudating heterophils and focal epithelial necrosis associated with epithelial syncytia and eosinophilic intranuclear inclusions consistent with herpesvirus infection. In the adult bird, this was associated with large numbers of bacteria (suspected to be a *Staphylococcus* spp.). In the chick, the viral inclusions and inflammation extended into the adjacent air sacs and parietal pericardium with diffuse perivascular haemorrhage and oedema associated with the attached air sac inflammation. Changes in other organs included diffuse moderate to marked congestion. A histopathological diagnosis of herpesvirus bronchointerstitial pneumonia and severe acute heterophilic airsacculitis was made. Based on the suspicion that the herpesvirus inclusions seen on histopathology in this case may be caused by the same herpesvirus as previously described in Indian ringnecks (Helfer et al., 1980; Tsai et al., 1993; Lazic et al., 2008), an attempt to determine the genome of the virus was made.

Materials, Methods and Results

DNA extraction and Next Generation Sequencing (NGS)

Genomic DNA was extracted from lung tissue according to Sarker et al. (2017a). A DNA library was prepared using an Illumina Nextera XT DNA Library Prep V3 Kit (Illumina, San Diego, USA). Sequencing of the DNA library was performed as paired-end on an Illumina® MiSeq chemistry according to the manufacturer's instructions. Preliminary assembly of the viral genome was conducted according to the established pipeline (Sarker et al., 2017b) using the CLC Genomics workbench 9.5.4 under the La Trobe University Genomics Platform. Briefly, de novo assembly was performed and this generated large contigs with consensus sequences that corresponded strongly to Gallid herpesvirus-1 sequences, according to BLASTn searches of GenBank databases (Altschul et al., 1990; Boratyn et al., 2013). The nearly complete PsHV genome generated was approximately 128 Kbp in length.

Annotation and phylogenetic analysis

The nearly complete genome of this novel PsHV was annotated using Geneious software (version 10.2.3; Biomatters Ltd, Auckland, New Zealand). The nucleotide sequence of the DNA polymerase gene was extracted, and aligned with other selected sequences of herpesviruses using Geneious. Tree topology with 1000 bootstrap re-samplings was chosen to construct the phylogenetic tree. BlastP searches of the DNA packaging terminase

subunit 2 gene demonstrated 37-46% similarity to PsHV1, GaHV-1 and GaHV-2, respectively. The DNA-polymerase gene was 30.4-37.8% similar to recognized psittacine herpesviruses (PsHV-1, AY623125.1; PsHV-2, AY23121 and PsHV-3, JX028240.1). The unrooted phylogenetic tree derived from these sequence alignments confirmed that this novel PsHV from the *P. krameri* sample was distantly related to Gallid herpesvirus (GaHV), demonstrating a sequence similarity with GaHV-1 of 54.33% (Figure 1).

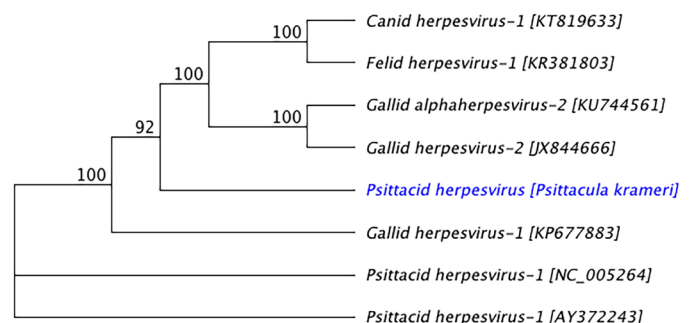


Figure 1: A neighbour joining tree was constructed from the nucleotide sequences of selected herpesviruses using DNA polymerase genes. The novel PsHV from this *P. krameri* sample demonstrated the highest sequence similarity with GaHV-1 (54.33%).

Discussion

The main findings at necropsy in this case were diffuse consolidation, congestion and red discoloration of the lungs; thickened airsacs with cream/yellow discoloration; pericardial haemorrhage and pericardial sac distension; left atrial enlargement; and pale kidneys. These findings are consistent with previously described lesions associated with a herpesvirus affecting parakeets with a tropism for the lower respiratory tract (Tsai et al., 1993; Raidal et al., 1995; Lazic et al., 2008; Shivaprasad and Phalen, 2012). Cytology (Figures 2 and 3) alongside histopathology (Figure 4) confirmed the presence of a herpesvirus bronchointerstitial pneumonia and air sacculitis. Whole genome sequencing of a novel herpesvirus from infected lung tissue is ongoing, but has confirmed the presence of a suspected novel PsHV that is distantly related to GaHV-1 according to phylogenetic tree analysis. GaHV-1 is an alpha-herpesvirus, and is the causative agent of ILT in poultry. This disease is characterised clinically by the development of necrotizing lesions within the oropharynx and upper respiratory tract, and occasionally, mild pneumonia (Timurkan et al., 2003; Lazic et al., 2008).

Based on the similarity of lesions demonstrated on histopathology, we suggest that the virus isolated in this case may be very similar to previously reported respiratory herpesvirus in Indian ringneck parrots (Tsai et al., 1993; Lazic et al., 2008) that had a demonstrated tropism for the lung and lower respiratory tract tissues. Such lesions have previously been identified on tissue histopathology and electron microscopy, but molecular characterization has been lacking. Preliminary analysis of sequencing data

has demonstrated that one of the large contigs matched with the GaHV-1 polymerase gene. Further sequencing will be conducted to fill the gap and complete the entire Psittacid herpesvirus genome. The genome will be annotated to capture all the potential open reading frames, followed by phylogenetic analysis to understand the evolutionary relationship with other Psittacid herpesviruses.

Understanding the epizootiology of respiratory herpesviruses requires genomic identification of the viruses involved. Such studies facilitate management of outbreaks of these diseases in individual birds and aviaries, biosecurity aspects relating to the international trade of birds, and conservation efforts of vulnerable avian species (Shivaprasad and Phalen, 2012).

Conclusion

A high morbidity and mortality outbreak of lower respiratory disease in an Indian ringneck flock in Victoria was caused by a herpesvirus as demonstrated by tissue histopathology. The herpesvirus isolated from infected lung tissue generated approximately 128 Kbp of the PsHV genome via NGS. This novel PsHV is distantly related to GaHV-1. Work is ongoing to fill the gap in the novel herpesvirus genome in order to complete the entire genome.

Acknowledgements

The authors would like to thank the AAVAC Research Fund for providing funding towards the costs of the genomic sequencing.

References

- Altschul, S.F., W. Gish, W. Miller, E.W Myers, D.J. Lipman. 1990. Basic local alignment search tool. *Journal of Molecular Biology*. **215**(3): 403-410
- Boratyn, G.M., C. Camacho, P.S. Cooper G. Coulouris, A. Fong, N. Ma, T.L. Madden, W.T. Matten, S.D. McGiniss, Y. Merezuk, Y. Raytselis, E.W. Sayers, T. Tao, J. Ye, I. Zaretskyaya. 2013. BLAST: a more efficient report with usability improvements. *Nucleic Acids Research*. **41**(W1): W29-W33. <https://doi.org/10.1093/nar/gkt282>
- Cover M.S. and W.J. Benton. 1958. The biological variation of the infectious laryngotracheitis virus. *Avian Diseases* **2**(4): 375-383
- Garcia M., S. Spatz, J.S. Guy. 2013. Infectious laryngotracheitis. In: Swain D.E., Glisson J.R., McDougald L.R., Nolan L.K., Suarez D.L. (Eds). *Diseases of Poultry*. Hoboken, NJ: John Wiley and Sons Inc. Pp 161-180.
- Helfer, D.H., J.A. Schmitz, S.L. Seefeldt, L. Lowenstein. 1980. A new viral respiratory infection in parakeets. *Avian Diseases*. **24**(3): 781-783.
- International Committee on Taxonomy of Viruses (ICTV). 2016. Virus Taxonomy: 2016 Release <https://talk.ictvonline.org/taxonomy/> Accessed 16 October 2017.
- Kaleta, E.F. and D.E. Doherty. 2007. Avian herpesviruses. In: Thomas N.J., Hunter D.B, Atkinson C.T. (Eds). *Infectious Diseases of Wild Birds*. Oxford: Blackwell Publishing. pp 63-86.
- Lazic, T.W., M.R. Ackermann, J.M. Drahos, J. Stasko, J.S. Haynes. 2008. Respiratory herpesvirus infection in two Indian Ringneck parakeets. *Journal of Veterinary Diagnostic Investigation*. **20**(2): 235-238
- Panigrahy, B. and L.C. Grumbles. 1984. Pacheco's disease in psittacine birds. *Avian Diseases*. **28**(3): 808-812
- Raidal, S.R., J.H. Gill, G.M. Cross. 1995. An acute respiratory disease with inclusion body bronchitis and splenitis in Bourke's parrots. *Australian Veterinary Practitioner*. **25**(2): 170-171.
- Ritchie, B.W. and K. Carter. 1995. *Avian Viruses Function and Control*. Wingers Publishing, Lake Worth, FL.
- Sarker, S., S. Das, K. Helbig, A. Peters, S.R. Raidal 2017a. Genome sequence of an Australian strain of canid alphaherpesvirus. *Australian Veterinary Journal* (In press)
- Sarker S., S. Das, J.L. Lavers, I. Hutton, K. Helbig, J. Imbery, C. Upton, S.R. Raidal 2017b. Genomic characterization of two novel pathogenic avipoxviruses isolated from Pacific shearwaters (*Ardenna* spp.) *BMC Genomics* **18**(1): 1-26. Article Number 298
- Shivaprasad, H.L. and D.N. Phalen. 2012. A novel herpesvirus associated with respiratory disease in Bourke's parrots. *Avian Pathology*. **41**(6): 531-539
- Thureen, D.R. and C.L. Keeler. 2006. Psittacid herpesvirus 1 and infectious laryngotracheitis virus: comparative genome sequence analysis of two avian alphaherpesviruses. *Journal of Virology* **80**(16): 7863-7872
- Timurkaan, N., F. Yilmaz, H. Bulut, H. Ozer, Y. Bolat. 2003. Pathological and immunohistochemical findings in broilers inoculated with a low virulent strain of infectious laryngotracheitis virus. *Journal of Veterinary Science*. **4**(2): 175-180
- Tsai, S.S , K. Hirai, C. Itakura. 1993. Herpesvirus infection in psittacine birds in Japan. *Avian Pathology*. **22**(1): 141-156.

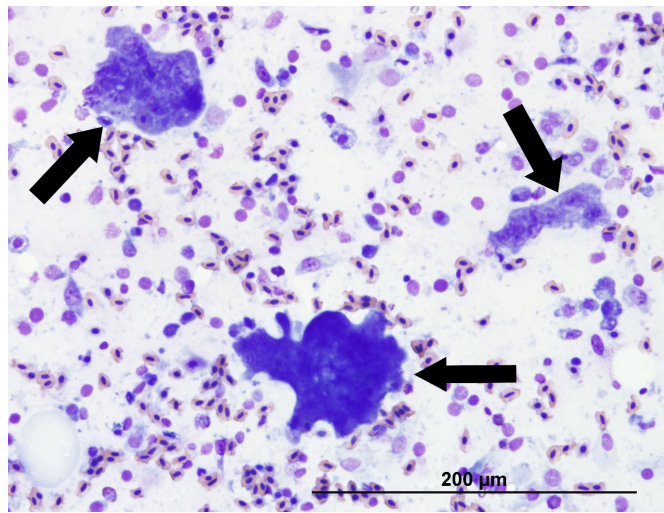


Figure 2. Impression smear of lung demonstrating three relatively large syncytia (arrows).

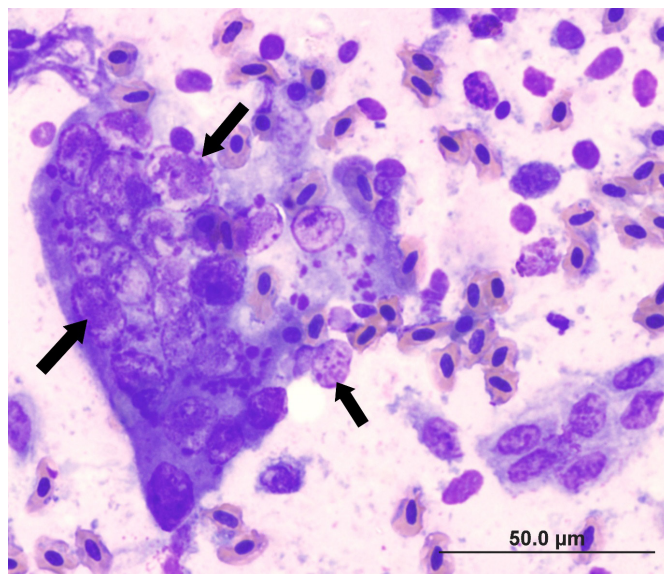


Figure 3. Impression smear of lung demonstrating numerous nuclei (arrow) containing intranuclear inclusions within a syncytium.

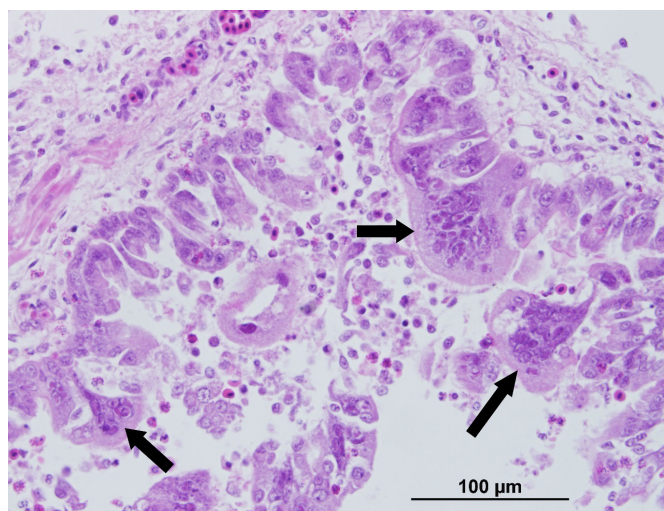


Figure 4. Haematoxylin and eosin-stained section of lung demonstrating multiple syncytia (arrows) within the epithelium and lumen of a parabronchus. Also present is diffuse oedema in the submucosa and a mixed inflammatory cellular infiltration and exudation into the lumen.