



## RESEARCH ARTICLE

### Evaluation of Fertility Disrupting Potentials of *Abrus precatorius* Seed Extracts in Male Rats for Arresting Spermatogenesis and Suppressed Fertility *In Vivo*

Saranika Talukder<sup>1\*</sup>, Subir Sarker<sup>2</sup>, Md Afzal Hossain<sup>3</sup>, Md Abu Hadi Khan<sup>4</sup>, Md Abdul Hannan<sup>3</sup> and M Tofazzal Islam<sup>5</sup>

<sup>1</sup>Department of Animal Science and Nutrition, Chittagong Veterinary and Animal Sciences University, Khulshi, Chittagong-4202; <sup>2</sup>Department of Animal Husbandry and Veterinary Science, Faculty of Agriculture, University of Rajshahi, Rajshahi-6205; <sup>3</sup>Department of Biochemistry, Faculty of Agriculture, <sup>4</sup>Department of Pathology, Faculty of Veterinary Medicine, Bangladesh Agricultural University, Mymensingh-2202; <sup>5</sup>Department of Biotechnology, Bangabandhu Sheikh Mujibur Rahman Agricultural University, Gazipur-1706, Bangladesh

\*Corresponding author: talukdersaranika@yahoo.com

#### ARTICLE HISTORY

Received: August 04, 2012  
Revised: October 19, 2012  
Accepted: April 05, 2013

#### Key words:

*Abrus precatorius* seed  
Antifertility  
Male rats  
Spermatogenesis

#### ABSTRACT

This study was aimed to evaluate the contraceptive potentials of different chemical extracts of *Abrus precatorius* seeds in male albino rats. The active ingredients of crushed seeds were extracted with 60% aqueous acetone and then partitioned consecutively with *n*-hexane, ethyl acetate, methanol and water. Water suspended chemical fractions at different doses were administered orally to the male rats for 40 days. Effects of different treatments on various male reproductive endpoints and contraceptive efficacy were evaluated. Oral administration of both organic (methanol soluble at 50 and 75 mg/kg BW) and aqueous soluble *A. precatorius* seed extracts caused infertility in studied subjects at varying degrees. At necropsy, average weights of testes, epididymis, ventral prostate gland and seminal vesicles were decreased significantly. Histology of testes revealed marked atrophy of the seminiferous tubules characterized by disruption of the germinal epithelium and atrophy of the Leydig cells. Epididymis also showed histological alterations. Hormonal assay revealed a significant decrease in serum levels of testosterone, follicle stimulating hormone (FSH) and luteinizing hormone (LH) that possibly resulted in suppressed spermatogenesis of male rats. These effects lead to the reduction of pregnancy rate of untreated fertile female rats while mated with the methanol extract (50 and 75 mg/kg BW) and aqueous extract-treated male rats. The results show that *A. precatorius* seed extract causes suppression of spermatogenesis and fertility, thereby suggesting the potential of this plant in the regulation of male fertility.

©2013 PVJ. All rights reserved

**To Cite This Article:** Talukder S, S Sarker, MA Hossain, MAH Khan, MA Hannan and MT Islam, 2014. Evaluation of fertility disrupting potentials of *Abrus precatorius* seed extracts in male rats for arresting spermatogenesis and suppressed fertility *in vivo*. Pak Vet J, 34(1): 18-23.

#### INTRODUCTION

From times immemorial, humans have relied on plants and their products as agents of therapeutic, industrial and environmental utilities (Anand *et al.*, 2010; D'cruz *et al.*, 2010; Munir *et al.*, 2013; Oh *et al.*, 2013). Over 75% of the world's population depends on herbal medicine for the fundamental health care (Herrera *et al.*, 2008; Bah *et al.*, 2012; Kim *et al.*, 2012). In addition, as being a cost-effective and having low toxic effect, use of plants for developing an antifertility agent appears to be an attractive proposition (Qureshi *et al.*, 2005; Mishra and Singh, 2009).

*Abrus precatorius* commonly known as precatory bean/rosary pea/ratti, and its roots, seeds and leaves are used in traditional and folklore medicine (Chaudhari *et al.*, 2012; Priya *et al.*, 2012). The seeds of *A. precatorius* have been used in eye disease, jaundice, pain, poisoning, fainting, arthritis, nephritis, diabetes and leucoderma (Monago and Akhidue, 2003; Monago and Alumanah, 2005). Previous studies reported the antifertility activity of *A. precatorius* seed extracts in female rats (Hannan *et al.*, 2006; 2010; Ini-Ibehe *et al.*, 2010) and also in male rats (Jahan *et al.*, 2009a; Talukder *et al.*, 2011) where these researchers used either the crude seeds, steroidal fractions or alcoholic extract of *A. precatorius* seeds for

testing the antifertility effect. The aim of the current study was to investigate the antifertility effect of different extracts (*n*-hexane, ethyl acetate, methanol and water) of *A. precatorius* seeds prepared by chemical fractionation of ground seeds in terms of hormonal profiling, histological study of the male reproductive organs and fertility testing using proven fertile female rats. We are not aware of any investigation conducted for evaluating the anti fertility potential of different chemical extracts of *A. precatorius* seeds.

## MATERIALS AND METHODS

**Plant material and chemical fractionation:** Dried seeds of *A. precatorius* L. were obtained from a local Ayurvedic Medicine Store. The seeds were authenticated by a Botanist from National Herbarium, Mirpur, Dhaka, Bangladesh and the voucher specimen was deposited in the laboratory of Department of Biochemistry, Bangladesh Agricultural University. The seeds were pulverized in microgrinder (Tekmark, Germany). The finely ground seeds were extracted according to the method developed by Islam (2005) and Hannan *et al.* (2006).

**Experimental design and treatments:** Twenty seven fertile mixed albino male rats were randomly allocated into nine groups (3 rats in each group) viz. control, *n*-hexane soluble at 25 and 50 mg/kg BW; ethyl acetate soluble at 25 and 50 mg/kg BW; aqueous soluble at 50 and 100 mg/kg BW; methanol soluble at 50 and 75 mg/kg BW. The rats were given the extracts on daily basis for 40 days.

**Sample collection and analysis:** After 40 days of study period, BWs of all rats were recorded. Then rats were exposed to mild ether anesthesia. Blood was then collected with a syringe and needle directly through cardiac puncture and separated serum samples were stored at  $-15^{\circ}\text{C}$  until assay. Serum hormonal levels were measured by radioimmunoassay using commercial kits, according to manufacturer's guide (Beijing Atom Hightech Co. Ltd, Beijing). The intra-assay and inter-assay coefficients of variation were  $<10\%$  and  $<15\%$  respectively for each test. The sensitivity of FSH, LH and testosterone assay was 50, 80 and 75%, while the specificity of these tests was 75, 95 and 95%, respectively.

**Fertility trial:** Twenty seven adult (2 months old) male rats of proven fertility were used for fertility test. Fertility was evaluated by allowing each male to mate with two proestrus females for overnight. Females were checked the next morning for the presence of vaginal plug for an indication of mating. The females becoming pregnant were then allowed to deliver at term.

**Necropsy and histological studies of reproductive organs:** The rats were sacrificed with decapitation. The reproductive organs such as testes, epididymis, prostate gland and seminal vesicles were trimmed to remove adhered fat, weighed and recorded. The collected testes and epididymis were excised, fixed in Bouin's fluid.

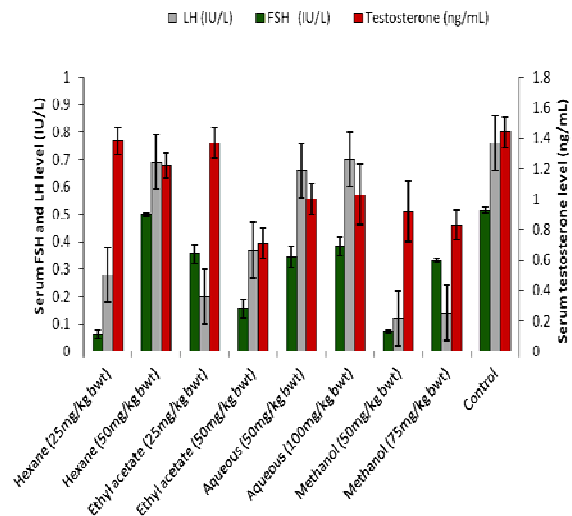
Tissues were sectioned at 5  $\mu\text{m}$ , and then stained with hematoxylin and eosin (Luna, 1968).

**Sperm counting:** To determine sperm count, 100 mg of cauda epididymis was minced in 2 ml RPMI-1640 containing 10% calf serum and incubated for 4 hours. One drop of homogenized sample was transferred to a Neubauer's counting chamber beneath a cover slip. The sperm counts of cauda epididymis were performed according to the procedure mentioned by Prasad *et al.* (1972).

**Statistical analysis:** Student's *t*-test and ANOVA were conducted to identify the significant change of various parameters (hormonal level, sperm counting, BW and reproductive organ weight) among control and different extract treated groups. All the numerical data are expressed as mean $\pm$ SE.

## RESULTS

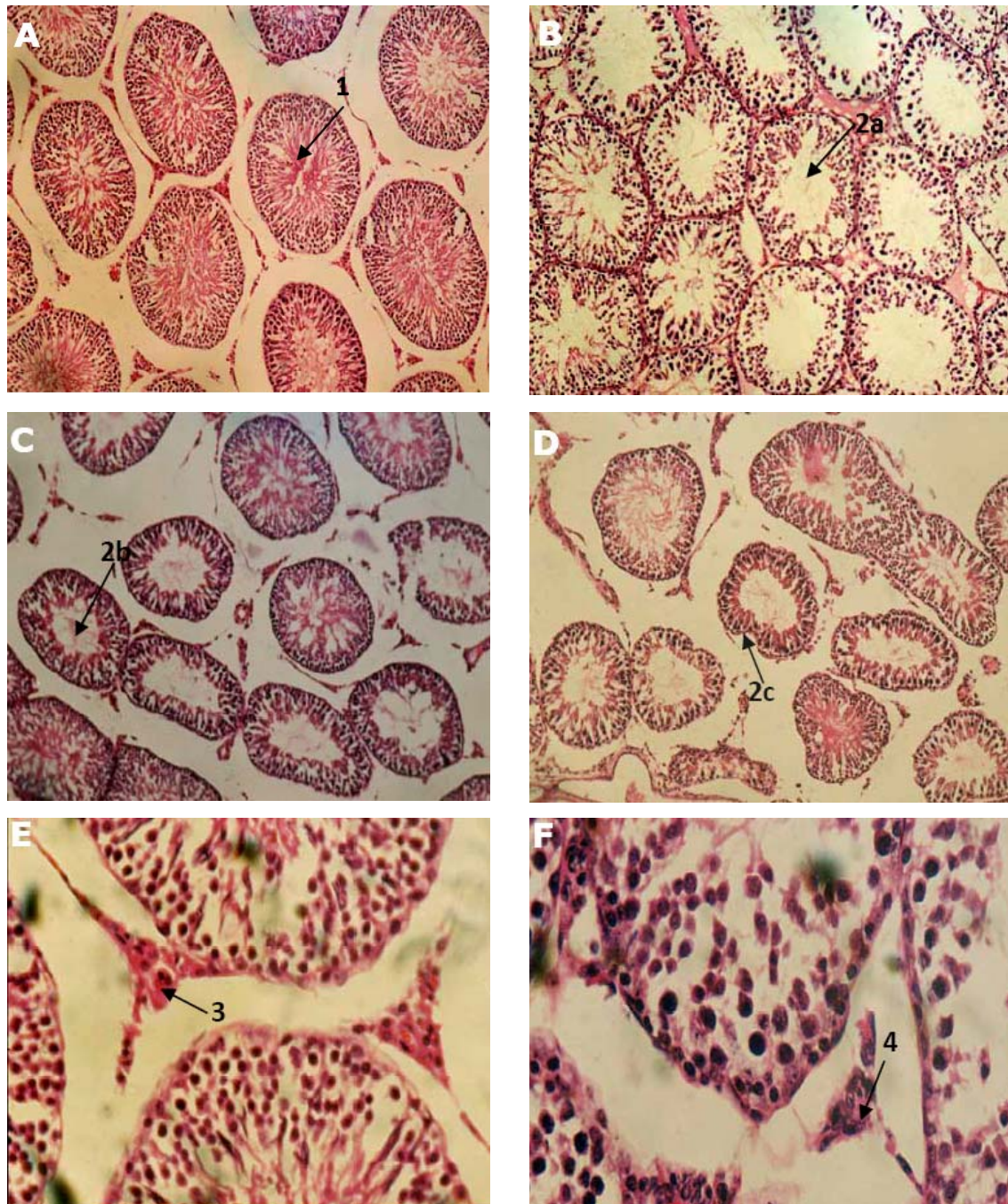
**Effect on hormonal profiles:** Serum levels of testosterone, LH and FSH were reduced significantly together in methanol soluble (50 and 75 mg/kg BW) and ethyl acetate soluble (50 mg/kg BW) treated groups compared to control. Ethyl acetate soluble at 50 mg/kg BW, methanol soluble at 50 and 75 mg/kg BW significantly ( $P<0.05$ ) reduced the levels of testosterone, LH and FSH in serum of treated rats as compared to control (Fig. 1).



**Fig. 1:** Effect of *Abrus precatorius* seed extracts on serum levels of FSH, LH and testosterone in male rat (mean $\pm$ SE).

**Effect on sperm count (dynamics):** Ethyl acetate soluble at the rate of 100 mg/kg BW, aqueous soluble at 50 and 100 mg/kg BW, methanol soluble at 50 and 75 mg/kg BW induced significant ( $P<0.05$ ) reduction of sperm count compared to control. The lowest sperm count (1.39 million/ml) was noted in methanol soluble at 75 mg/kg BW (Table 1).

**Effects on histoarchitecture of reproductive organs:** The seminiferous tubules of control rat testes exhibited normal histological morphology (Fig. 2A and 2E). On the other

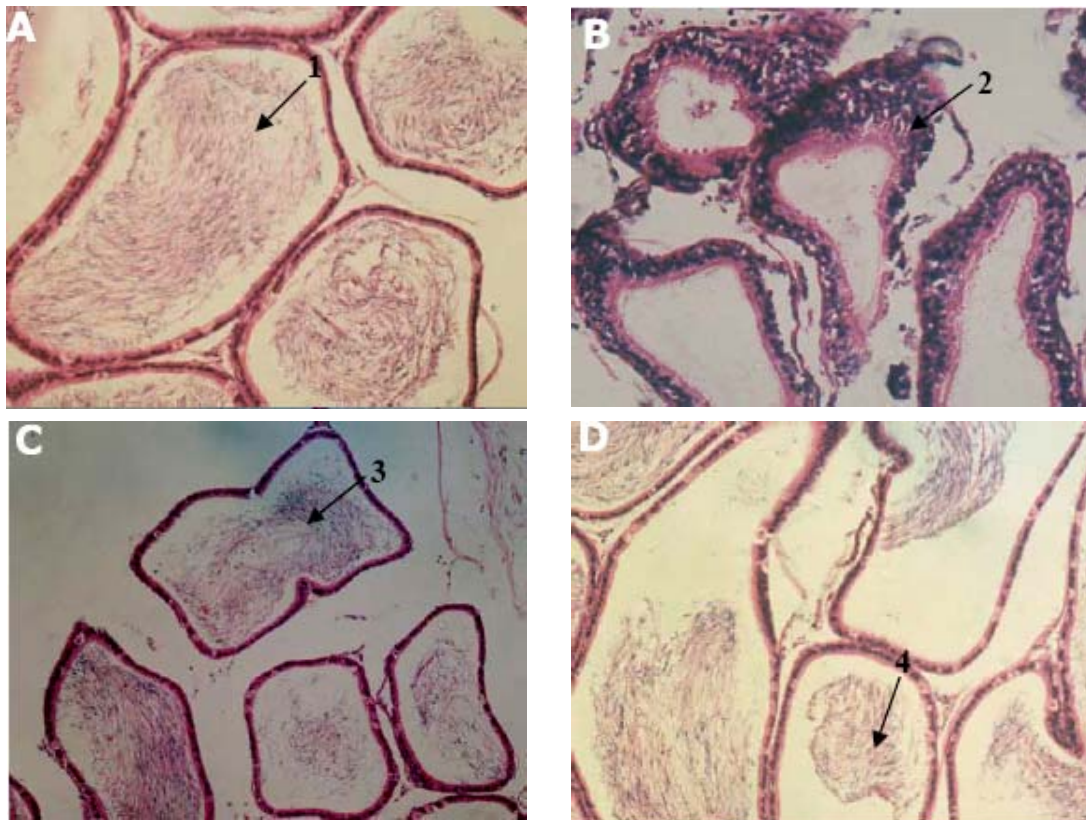


**Fig. 2:** Histology of testes of rat. A, section of testis (control) showing convoluted seminiferous tubules containing regularly organized germ cells and spermataids in the lumen (1); B, C and D, sections of testes (*n*-hexane soluble, methanol soluble and ethyl acetate soluble treated, respectively), showing lack of spermataids in the lumen of seminiferous tubules and disorganized germ cells (2a), tail piece of spermatazoa but lacking spermataid in the seminiferous tubules (2b), atrophy of tubular epithelium (2c) (H & E: 80X); E, section of testis (control) showing normal Leydig cell in intertubular space (3); F, section of testis (methanol soluble) showing cytoplasmic atrophy of Leydig cell & darker nuclei (4) (H & E:  $\times 300$ ).

hand, distinct degenerative changes were observed in the histomorphology of *A. precatorius* seed extract-treated groups. Histological section of testes of the methanol soluble-treated rats showed degeneration of germinal epithelium. Primary and secondary spermatocytes, and sperm cells were markedly reduced in the lumen of convoluted seminiferous tubules, only very few tubules contained dead or degenerating tail piece of spermatazoa and most of them lacking spermataids (Fig. 2C). Leydig cells were present around the small capillaries in the intertubular space, but the

number and size were greatly reduced. Interstitial cells exhibited cytoplasmic atrophy with dark nuclei (Fig. 2C). The testes of rats treated with 25 or 50 mg/kg BW of *n*-hexane soluble, 25 mg/kg BW of ethyl acetate soluble and 50 mg/kg BW of aqueous soluble also showed disorganization of the seminiferous epithelium while Leydig cells appeared normal compared to control (Fig. 2F).

Histoarchitecture of cauda epididymis of treated groups showed noticeable histological alterations compared to epididymis of control rats (Fig. 3A). The epididymis of



**Fig. 3:** Histology of tail of epididymis of rat. A, section of tail of epididymis (control) showing mature and conspicuous spermatozoa in the lumen (1); B, C and D, sections of tail of epididymis (n-, hexane soluble, ethyl acetate soluble and methanol soluble treated, respectively), showing tubules lacking spermatozoa (2), lining epithelium turned to stratified columnar epithelium (3), degeneration of sperm in lumen (4) and partially empty tubules with degenerated sperm in the lumen (H & E:  $\times 300$ ).

**Table 1:** Sperm counting of cauda epididymidis of rats after *Abrus precatorius* seed extract treatment

Groups	Dose regimen (mg/kg BW/day)	Sperm count (million/ml)
n-Hexane soluble	25	3.49 $\pm$ 0.17
	50	3.21 $\pm$ 0.15
Ethyl acetate soluble	25	2.35 $\pm$ 0.5
	50	1.72 $\pm$ 0.17*
Aqueous soluble	50	1.61 $\pm$ 0.18*
	100	1.55 $\pm$ 0.19*
Methanol soluble	50	1.43 $\pm$ 0.12 <sup>†</sup>
	75	1.39 $\pm$ 0.15 <sup>†</sup>
Control	No treatment	7.87 $\pm$ 0.24

Results are expressed as mean $\pm$ SE. Three male rats were included in each group. Mean having asterisk indicates significant ( $P < 0.05$ ) difference in contrast to control group.

methanol soluble-treated rats were containing degenerated spermatozoa or lacking of spermatozoa. The cytoplasmic component of the lining epithelial cells showed apical atrophy and turned into stratified columnar epithelium. Infiltration of the mononuclear cells, macrophage in the lumen of the tubules of epididymis was seen (Fig. 3D). The epididymis of rats treated with both 25 and 50 mg/kg BW of n-hexane, 25 mg/kg BW of ethyl acetate and 50 mg/kg BW of aqueous soluble showed degeneration of sperm cells in the lumen while the lining epithelial tissues appeared normal (Fig. 3B and 3C).

**Fertility test:** Methanol soluble (50 and 75 mg/kg BW), aqueous soluble (50 and 100 mg/kg BW) elicited maximum antifertility (100%) in treated male rats and failed to induce

**Table 2:** Fertility of male rats after treatment with *Abrus precatorius* seed extracts or distilled water

Groups	Dose regimen (mg/kg BW/day)	Number of male rats			Number of female rats		
		Tested	Mated	Fertile (%)	Tested	Mated	Pregnancy rate (%)
n-Hexane soluble	25	3	3	100	6	6	100
	50	3	3	100	6	6	100
Ethyl acetate soluble	25	3	3	100	6	6	100
	50	3	3	100	6	6	100
Aqueous soluble	50	3	3	0	6	6	0
	100	3	3	0	6	6	0
	75	3	3	0	6	6	0
Control	No treatment	3	3	100	6	6	100

pregnancy in female rats of proven fertility (Table 2), while males treated with other extracts were able to produce pregnancies in all tested females.

**Effects on BW and reproductive organ weight:** BW of *A. precatorius* seed extract-treated rats was not significantly different compared with control rats. On the other hand, reproductive organ weight of testes, cauda epididymis, seminal vesicle and prostate gland in extract-treated rats reduced significantly compared with control (Table 3).

## DISCUSSION

In the current study, methanol soluble (75 mg/kg BW), aqueous soluble (100 mg/kg BW) extract elicited

**Table 3:** Reproductive organ weights in *Abrus precatorius* seed extract-treated and control male rats

Groups	Dose regimen (mg/kg BW/day)	Testes	Epididymis	Seminal vesicle	Prostate gland
n-Hexane soluble	25	1279.00±17.96*	497.66±15.86*	0.32±0.02	0.17±0.03
	50	1452.00±23.55	509.66±24.25**	0.22±0.03**	0.11±0.02**
Ethyl acetate soluble	25	1335.33±19.89*	523.33±17.23**	0.23±0.02**	0.12±0.07**
	50	1525.33±20.83	425.66±22.65**	0.26±0.15**	0.15±0.04**
Aqueous soluble	50	1210.66±25.01**	531.00±23.60**	0.20±0.04**	0.11±0.08**
	100	1266.00±27.29**	451.66±20.00**	0.31±0.08*	0.16±0.09*
Methanol soluble	50	1533.66±29.27	559.00±8.68**	0.32±0.15	0.17±0.02
	75	1436.66±22.04	471.00±6.30**	0.24±0.02**	0.13±0.06**
Control	No treatment	1711.00±17.02	637.00±23.51	0.40±0.02	0.19±0.05

Results are expressed as mean±SE. Three male rats were included in each group. Mean having different superscript \* indicates P<0.05, \*\* indicates P<0.01 which significantly differ in contrast to control group.

the maximum antifertility potentials overall in treated male rats considering all the parameters evaluated, though for some parameters (reproductive organs weight) other organic extracts also showed significant changes.

Serum levels of testosterone, LH and FSH were reduced significantly in rats treated with ethyl acetate soluble at 50 mg/kg BW, methanol soluble at 50 and 75 mg/kg BW compared to control. In addition, rats treated with aqueous soluble and methanol soluble showed a significant decline in sperm concentration that is consistent with the findings of another report (Jahan *et al.*, 2009b). These authors observed significant decrease of serum testosterone in mice treated with ethanolic seed extract of *Abrus precatorius* at 60 mg/kg BW compared to controls. Testosterone plays a fundamental role in the maintenance of spermatogenesis (O'Donnell *et al.*, 2006; Mishra and Singh, 2009) and it is probable that the *A. precatorius* seed extract-induced suppression of spermatogenesis or alteration of sperm production in the current study was caused due to deficiency of testosterone.

Methanol soluble extract at 50 and 75 mg/kg BW caused marked degenerative changes in the histological appearance of testes and epididymis. Moreover, the number of Leydig cells were greatly reduced and interstitial cells exhibited cytoplasmic atrophy with dark nuclei. Such histological alterations have also been described in other reports with ethanolic extract of *A. precatorius* seeds (Jahan *et al.*, 2009b), aqueous leaf extracts of *Azadirachta indica* (Mishra and Singh, 2005) and *Allamanda cathartica* (Singh and Singh, 2008). In response to LH, testosterone is produced by Leydig cells (Chung *et al.*, 2011). Reduced level of testosterone in the methanol soluble treated groups may explain the alterations observed in the seminiferous tubule morphology.

No significant differences were noted in BWs of *A. precatorius* seed extract-treated groups compared with control group which is consistent with other reports (Hannan *et al.*, 2006). No effect on BW indicates that extracts were not related with any weight gain causing obesity or electrolyte retention. However, the organ weights of testes, cauda epididymis, seminal vesicle and prostate gland were lower in extract-treated rats compared to control rats which is consistent with findings of Vanithakumari *et al.* (1989) who investigated the ethanolic extract of *Bambusa arundinaceae* tender shoots for fertility regulation. Weight, size and the secretory function of reproductive organs are closely regulated by androgen (Choudhary *et al.*, 1990) and such decrease in

reproductive organs' weights could be attributed to a loss of spermatogenic elements in testes and absence of sperm in cauda epididymis in our study.

Methanol soluble (50 and 75 mg/kg BW) and aqueous soluble (50 and 100 mg/kg BW) extract elicited maximum antifertility (100%) potentials in treated male rats and failed to induce pregnancy in fertility proven female rats. Earlier study conducted by Abu *et al.* (2012) reported that ethanolic seed extract of *Abrus precatorius* at higher concentration (80 mg/kg BW) gave relatively more permanent antifertility activity than the lower dose (40 mg/kg BW).

The results presented here clearly suggest that *A. precatorius* seed extract reduced serum levels of reproductive hormones possibly by having an influence on hypothalamic-pituitary-gonadal axis. FSH and LH at the reduced levels might have effect on the testicular spermatogenesis. Suppressed spermatogenesis in seed extract treated groups and thereby the reduction in the number of sperm in tubular lumen might be via action of its strong toxalbumen which might be imparting the alteration of reproductive organs morphology, hormonal profile and causing suppressed pregnancy in female rats while mated with treated male rats. The organic fractions such as n-hexane, ethyl acetate and methanol extracts displayed antifertility activity of different extent that indicates the necessity of the isolation and identification of the active principles by a further bioassay-guided chromatographic separation. Moreover, antifertility mode of action and treatment of male animals with the isolated active principles of *A. precatorius* seed extracts is required to explore the comprehensive antifertility effect of *A. precatorius* seeds in male subjects.

**Acknowledgement:** The funding for this research work was supported by Ministry of Science and Information & Communication Technology, Bangladesh (to primary author). We offer special thanks to the director of Nuclear Medicine Division, Mymensingh Medical College, Bangladesh for their technical support in hormonal analysis.

## REFERENCES

- Abu SM, ABMM Hossain, MB Majid and IM Anwarul, 2012. Antifertility studies on ethanolic extract of *Abrus precatorius* L. on Swiss male albino mice. *Int J Pharm Sci Res*, 3: 288-292.
- Anand RA, VO Kishor, VS Rajkumar, CD Upasani and DN Tanaji, 2010. *Abrus precatorius* Linnaeus: A phytopharmacological review. *J Pharm Res*, 3: 2585-2587.
- Bah AA, F Wang, ZH Huang, IH Shamsi, QC Zhang, G Jilani, S Hussain and E Ali, 2012. Phyto-characteristics, cultivation and medicinal

- prospects of Chinese Jiaotou (*Allium chinense*) Int J Agric Biol, 14: 650-657.
- Chaudhari KS, R Sharma, PS Pawar and VA Kashikar, 2012. Pharmacological activities of *Abrus precatorius* Linn. – A review. Int J Ayurv Herb Med, 2: 336-348.
- Choudhary DN, JN Singh, SK Verma, and BP Singh, 1990. Antifertility effects of leaf extracts of some plants in male rats. Indian J Exp Biol, 28: 714-716.
- Chung JY, YJ Kim, JY Kim, SG Lee, JE Park, WR Kim, YD Yoon, KS Yoo, YH Yoo and JM Kim, 2011. Benzo[ $\alpha$ ] pyrene reduces testosterone production in rat Leydig cells via a direct disturbance of testicular steroidogenic machinery. Environ Health Perspec, 119: 1569-1574.
- D'cruz SC, S Vaithinathan, R Jubendradass and PP Mathur, 2010. Effects of plants and plant products on the testis. Asian J Androl, 12: 468-479.
- Hannan AM, AM Hossain, MT Islam and HE Chowdhury, 2006. Contraceptive effects of *Abrus precatorius* seed on female rats. J Bang Soc Agric Sci Technol, 3: 185-188.
- Hannan, AM, AM Hossain and MT Islam, 2010. Seed extracts of a Bangladeshi medicinal plant *Abrus precatorius* show antifertility activity in female rats. Orient Pharm Exp Med, 10: 103-110.
- Herrera DM, S Abdala, D Benjumea and JG Luis, 2008. Diuretic activity of some *Withania aristata* Ait. fraction. J Ethnopharmacol, 117: 496-499.
- Ini-Ibehe EO, AA Abraham, MB Osinubi, OO Olaleye, OK Taiwo, CN Cressie and OO Abayomi, 2010. Antioviulatory and anti-implantation potential of the methanolic extract of seeds of *Abrus precatorius* in the rat. Endoc Prac, 16: 554-560.
- Islam MT, 2005. Ecochemical interactions between plants and phytopathogenic *Aphanomyces cochlioides* zoospores. J Grad Sch Agric, 71: 123-128.
- Jahan S, S Rasoo, MAN Khan, M Ahmad, M Zafar, M Arsahd, and AM Abbasi, 2009a. Antifertility effects of ethanolic seed extract of *Abrus precatorius* L. on sperm production and DNA integrity in adult male mice. J Med Plants Res, 3: 809-814.
- Jahan S, N Saeed, F Ijlal, MA Khan, M Ahmad, M Zafar and AM Abbasi, 2009b. Histomorphological study to evaluate anti-fertility effect of *Abrus precatorius* L. in adult male mice. J Med Plant Res, 3: 1021-1028.
- Kim SH, NS Kim, KC Lee, HB Lee and MS Kim, 2012. Treatment of multiple thoracolumbar intervertebral disc disease using electroacupuncture and oriental herbal medicine in a dog. Pak Vet J, 32: 631-634.
- Luna LG, 1968. Manual of Histologic Staining Methods of the Armed Forces Institute of Pathology, 3<sup>rd</sup> Ed; McGraw Hill Book Co, New York, USA, pp: 96-99.
- Mishra, RK and SK Singh, 2005. Effect of aqueous leaf extract of *Azadirachta indica* on the reproductive organs in male mice. Indian J Exp Biol, 43: 1093-1103.
- Mishra, RK and SK Singh, 2009. Reversible antifertility effect of aqueous rhizome extract of *Curcuma longa* L. in male laboratory mice. Contraception, 79: 479-487.
- Monago CC and EO Alumanah, 2005. Antidiabetic effect of chloroform-methanol extract of *A. precatorius* Linn seed in alloxan diabetic rabbits. J Appl Sci Environ Manag, 9: 85-88.
- Monago CC, and V Akhidue, 2003. Antidiabetic effect of crude glycoside of *A. precatorius* in alloxan diabetic rabbits. Glob J Pure Appl Sci, 9: 35-38.
- Munir A, U Sultan and M Iqbal, 2013. Development and performance evaluation of a locally fabricated portable solar tunnel dryer for drying of fruits, vegetables and medicinal plants. Pak J Agric Sci, 50: 493-498.
- O'Donell L, SJ Meachem, PG Stanton and RI McLachlan, 2006. Endocrine regulation of spermatogenesis. In: Knobil and Neill's Physiology of Reproduction, JD Neill ed; vol. 1, 3rd Ed, Elsevier Academic Press, St Louis (MO), USA, pp: 1017-1069.
- Ou C, N Shi, Q Pan, D Tian, W Zeng and C He, 2013. Therapeutic efficacy of the combined extract of herbal medicine against infectious bursal disease in chickens. Pak Vet J, 33: 304-308.
- Prasad MR, NJ Chinoy and KM Kadam, 1972. Changes in succinic dehydrogenase levels in the rat epididymis under normal and altered physiologic conditions. Fertil Steril, 23: 186-190.
- Priya G, K Saravanan and C Renuka, 2012. Medicinal plants with potential antifertility activity- A review of sixteen years of herbal medicine research (1994-2010). Int J Pharm Tech Res, 4: 481-494.
- Qureshi AA, DB Sanghai and SS Padgilwar, 2005. Herbal options for contraception: a review. Pharmacog Mag, 2: 204-214.
- Singh A and SK Singh, 2008. Reversible antifertility effect of aqueous leaf extract of *Allamanda cathartica* L. in male laboratory mice. Andrologia, 40: 337-345.
- Talukder S, MA Hossain, S Sarker and MAH Khan, 2011. Investigation into effect of crude mixture of *Abrus precatorius* seed on hypothalamopituitary gonadal axis and development of antifertility in male rats. Bang J Agric Res, 36: 103-109.
- Vanithakumari G, S Manonayagi, S Padma and T Malini, 1989. Antifertility effect of *Bambusa arundinacea* shoot extracts in male rats. J Ethnopharmacol, 25: 173-80.