

openheart Predicting arrhythmias in primary prevention heart failure patients: picking up the fragments

Nathan Engstrom,¹ Hayley Louise Letson ¹, Kevin Ng,² Geoffrey Phillip Dobson¹

To cite: Engstrom N, Letson HL, Ng K, *et al.* Predicting arrhythmias in primary prevention heart failure patients: picking up the fragments. *Open Heart* 2022;**9**:e002075. doi:10.1136/openhrt-2022-002075

Accepted 16 August 2022

ABSTRACT

Identifying patients with high-risk heart failure (HF) who would benefit from an implantable cardioverter-defibrillator (ICD) remains controversial. A potential marker for arrhythmic sudden death is fragmented QRS (fQRS). fQRS is the notching and slurring of the QRS complex in a 12-lead ECG and it indicates abnormal ventricular depolarisation and myocardial scarring and fibrosis. However, before fQRS complex can be included into selection criteria for ICD therapy, more complete reporting is required on their association with malignant arrhythmias, left ventricular remodelling and myocardial scarring/fibrosis in patients with HF. The molecular basis of the fQRS-arrhythmia-fibrosis connection in HF also needs to be explored. It is not widely appreciated that changes in the QRS complex and phases 0 and 1 of the ventricular action potential occur *before contraction* and predetermine Ca²⁺ release *during contraction* and later Ca²⁺ sparks. It is currently not known whether the different zig-zag patterns of the QRS are associated with aberrant Ca²⁺ cycling and arrhythmogenic sparks in patients with HF.

INTRODUCTION

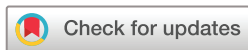Despite major advances in treating patients with severe heart failure (HF), deciding who should receive an implantable cardiac defibrillator (ICD) remains challenging. Over 200 000 ICDs are implanted globally each year; however, the major cause of death in these patients (up to 70%) is not arrhythmic sudden cardiac death (SCD).^{1–3} Current risk stratification for ICD implantation and SCD include a New York Heart Association functional classification II–III, reduced left ventricular ejection fraction (LVEF <35%) with no improvement after 3 months of maximal therapy, QRS <120 μs, a predicted survival >1 year, age and comorbidity.^{1 2 4 5} Of all these risk factors, the single most important criterion is LVEF <35%.⁵ However, a substantial number of patients with HF at risk of SCD have LVEF >35% and would not qualify for an ICD.^{1 2 5} Previous studies in patients with HF with preserved ejection fraction showed that 20–40% of cardiovascular deaths were SCD, although the underlying mechanisms remain

unknown.⁶ Clearly the current international guidelines for primary prophylaxis ICD in patients with HF are inadequate.

Fragmented QRS as a potential prognostic marker of arrhythmic sudden death

Additional prognostic criteria are urgently required to maximise the benefit of ICD therapy, and these include genetic testing, circulating biomarkers, improved knowledge of the myocardial scar and fibrosis and changes in the ECG waveform.^{2 5} In this viewpoint, we discuss the potential role of one or more fragmented QRS (fQRS) complexes to predict malignant ventricular arrhythmias and sudden death in primary prevention patients with HF. fQRS is defined as high-frequency notching and slurring within the QRS complex that reflects abnormal ventricular depolarisation and structural (anatomical) and functional (electrical) pathophysiology.^{1 7} The term fQRS was coined by Boineau and Cox in 1973, who reported the appearance of fragmented electrograms and re-entrant activity in dogs after coronary occlusion.^{1 7} Today, the most common fQRS forms include an additional R wave or notching in the lowest point of the S wave, or the presence of >1 R wave in the QRS complex measured in two contiguous leads, corresponding to a major coronary territory^{1 7} (figure 1).

The idea of linking fQRS to malignant arrhythmias is not new. It dates back to the early 1950s with Langner's electrocardiographic investigations.⁸ Langner was among the first to show notching and slurring of an expanded ECG in patients following a 'healed' myocardial infarction.⁸ The association between fQRS and cardiomyopathy did not appear, however, until 1969 in a landmark study of Flowers and colleagues.⁹ This was followed 40 years later by another important study of Das and colleagues, which included primary and secondary prevention of patients with HF.⁷ The presence of fQRS



© Author(s) (or their employer(s)) 2022. Re-use permitted under CC BY-NC. No commercial re-use. See rights and permissions. Published by BMJ.

¹College of Medicine and Dentistry, James Cook University, Townsville, Queensland, Australia
²Cardiology Clinic, Cairns Hospital, Cairns, Queensland, Australia

Correspondence to

Professor Geoffrey Phillip Dobson; geoffrey.dobson@jcu.edu.au

Type	Definition	Morphology
Narrow	QRS duration <120 ms with or without Q waves and has an additional R wave or notching at the lowest point of the S/R wave or the existence of >1 R wave in 2 or more successive leads corresponding to a coronary artery (CA) territory.	Narrow
Wide	QRS duration ≥120 ms with or without Q waves and is explained with >2 R waves or notching at the lowest point of the S/R wave or the existence of >2 R waves in 2 or more successive leads corresponding to a CA territory.	Wide
Paced	QRS >120 ms without any evidence of fusion when the beat is initiated by a pacing spike in pacemaker and ICD. Is explained with >2 R waves or notching at the lowest point of the S/R wave or the existence of >2 R waves in two or more successive leads corresponding to a CA territory.	Pacing Pacing Spike
PVC	A premature ventricular contraction (PVC) with no evidence of supraventricular fusion and is explained with >2 R waves or notching at the lowest point of the S/R wave or the existence of >2 R waves in 2 or more successive leads corresponding to a CA territory, or if 2 notches in R wave are present and > 40 ms apart.	PVC
Q wave	Notching in the Q wave can occur in any part of the Q wave. However, it must be negative (under the baseline). The exception is a Q wave occurring at the onset of the R wave (Q-R borderline-fQRS).	 Descending In Q-peak Ascending Q-R Border
R wave	Termed “notched R” classifies different RsR morphologies. A positive fragmentation must be present and can occur in any part of the ascent of the R wave. This is found at the R peak. However, the upper segment must be >50% of the declining R wave. If occurring at the peak of the R wave the difference in amplitude cannot be > 1.0 mm/0.1 mV	 Notched R Ascending Notched R in R peak Notched R in Upper Descending Notched R in lower Descending
S wave	Notched S occurs in the descent of the S wave, at the top or in the ascending part of the S wave and is termed a “notched S” and must always have a negative fQRS. The amplitude difference between the top or the peak of the S wave and the second fQRS component cannot be >1.0mm/0.1 mV. R-S borderline fQRS appears in borderline area of the R and the S wave and stretches across both sides of the baseline and can be both positive or negative.	 Descending In S-peak Ascending Q-R Border

Figure 1 Different morphologies of fragmented QRS complexes (fQRS) in the 12-lead ECG by Das *et al*¹¹ and modified fQRS Q, R and S criteria after Haukilahti *et al*.¹

has subsequently been shown to be an independent arrhythmic marker in patients with Brugada syndrome, right ventricular cardiomyopathy and other cardiac and non-cardiac pathologies.¹ The next step was to identify and quantify the underlying causes of the fQRS complex, and how this zig-zag pathology leads to dyssynchrony of LV systolic function, and possibly ventricular fibrillation or ventricular tachycardia.^{10,11} Das and colleagues suspected that the primary substrates for fQRS complexes were myocardial scarring, fibrosis or inflammation, which has subsequently been confirmed.¹¹⁰ Spatial locations of scars and non-viable myocardium are predicted from a 12-lead ECG and confirmed using a variety of methods, including single photon emission tomography (SPECT),¹⁰ magnetocardiography (MCG)¹² and late gadolinium enhancement cardiac MRI (Ga-MRI).⁵

Paucity of high-quality experimental and clinical data

Despite a growing interest in fQRS as a prognostic marker for ventricular arrhythmias, little progress has been made in assessing its clinical usefulness in patients with HF. This appears largely due to a paucity of high-quality experimental and clinical data. We recently performed a systematic review and meta-analysis of studies examining fQRS in patients with HF with or without an ICD, and with LVEF

≤40%.¹³ Outcome measures were ventricular arrhythmias and all-cause mortality.¹³ Using these search criteria, we analysed 10 studies involving 3885 patients and found that fQRS was statistically associated with ventricular arrhythmias and all-cause mortality. Furthermore, our study revealed a number of knowledge gaps in current reporting. None of the studies included all major forms of fQRS (narrow, wide, paced, premature ventricular contraction) (table 1), and only three reported on coronary artery territory.¹³ In addition, there were no uniform criteria on what constituted a ventricular arrhythmic event, which precluded post hoc assessment of what type of arrhythmia triggered ICD shocks.¹³ A further complication was the failure to separate primary and secondary prevention patients with HF as well as those with ischaemic (ICM) vs non-ICM (NICM) cardiomyopathies.¹³ There were also concerns on the reproducibility of ECG measurements, fQRS characterisation, counting of leads and intra and interobserver variability.¹⁴ Miscounting leads and subjective visual yes/no diagnoses can make some studies inaccurate and non-reproducible.¹⁴ This lack of complete reporting illustrates the current gaps in knowledge when assessing fQRS as a potential predictor of ventricular arrhythmias and sudden death.

Table 1 Gaps in knowledge to assess fragmented QRS (fQRS) as a potential prognostic candidate for primary prevention ICD placement in heart failure (HF) patients

Number	Focus areas
1.	Identify the different forms of fQRS, that is, narrow, wide, paced and PVCs, as part of routine patient screening (see figure 1).
2.	Specify location of the different fQRS forms according to coronary artery territory.
3.	Quantify proximity of fQRS to a myocardial scar/fibrosis region and functional status.
4.	Determine timing of fQRS formation during screening and post-implant follow-up.
5.	Separate ischaemic from non-ischaemic cardiomyopathy patients and investigate sex differences.
6.	Provide a full evaluation of appropriate and inappropriate ICD shocks and unresponsive ICD therapy events.
7.	Quantify the nature and type of arrhythmias that triggered ICD shocks and rate of arrhythmia (VT, VF).
8.	Provide ICD type (dual chamber, single chamber, bi-ventricular or subcutaneous).
9.	Provide ICD programming.
10.	Document status of co-morbidities (eg, obesity, diabetes, renal disease, liver disease, COPD, sleep apnoea and others).

COPD, chronic obstructive pulmonary disease; ICD, implantable cardioverter-defibrillator; PVC, premature ventricular contraction; VF, ventricular fibrillation; VT, ventricular tachycardia.

Towards a functional linkage between fQRS, myocardial scar/fibrosis and arrhythmias

There is an urgent need for more complete and accurate reporting on the number, type, location and timing of formation of fQRS and its association with myocardial scar/fibrosis and arrhythmias during patient screening and after ICD implantation¹ ([table 1](#)). Location and

timing of formation of non-viable myocardium are important because 38–50% of patients with ICM have a myocardial scar (replacement fibrosis after necrosis),⁷ and up to 75% patients with NICM have patchy or diffuse fibrosis from different secondary remodelling events.¹

Triggering arrhythmias in patients with HF depends on many factors, including spatial variation, location and density of the scar and/or fibrotic architecture in the myocardium.⁵ For example, the onset of arrhythmias around a scar and/or ICM regions largely result from heterogeneous activation due to regional conduction slowing or block ([figure 2](#)),^{1,5,7} whereas arrhythmias triggered from a failing myocardium with more diffuse fibrosis involves a more spiral wave formation from myocyte–fibroblast interfaces, particularly where fibrosis encircles preserved myocytes ([figure 2](#)).⁵ Diffuse fibrosis also appears to be more strongly associated with arrhythmias than scar tissue secondary to myocardial infarction and may help explain why patients with NICM with fQRS have a significant 2-fold to 3-fold increased incidence of death compared with patients with ICM.¹³ The sensitivity and specificity of fQRS to predict a scar in patients with ICM or NICM is around 80–90% using SPECT, MCG or Ga-MRI,^{5,7,12,15} and future studies could benefit from including these quantitative assessments.

Recently, late gadolinium enhancement was used in the prospective multicentre study of Klem and colleagues, and they showed in over 1000 patients with NICM that myocardial fibrosis was independently and strongly correlated to arrhythmic events and SCD.⁵ In this landmark study, no significant prognostic association was found between LVEF \leq 35% and risk of sudden death, which provides further evidence why LVEF $<$ 35% should not remain a major driver for determining a patient's eligibility for an ICD.^{5,6} Unfortunately, fQRS, myocardial fibrosis and sudden death were not included in their study, and it again highlights the need for more studies in this area. Postimplant monitoring could include fQRS

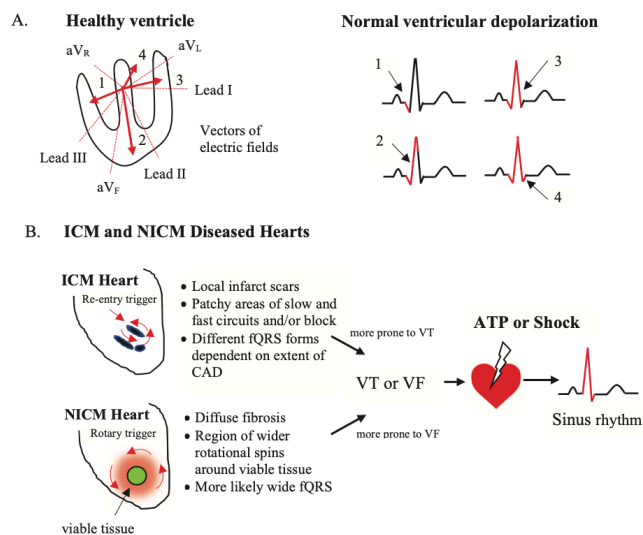


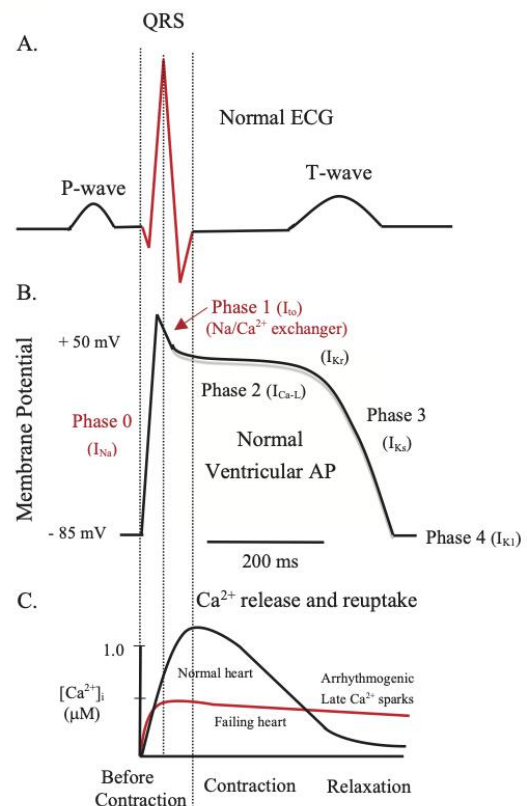
Figure 2 (A) In the healthy heart, the vector nature of the electric field provides visualisation of the timing of the QRS complex and helps to identify the extent and location of non-viable myocardium in diseased hearts, including those regions responsible for fQRS. (B) Differences in arrhythmia generation in ICM and NICM patients. ICM patients have more localised scarring compared with more diffuse fibrosis in NICM patients. These different pathologies generate different mechanisms to form different fQRSs and to initiate VT or VF (see text). Other mechanisms of VF and VT initiation include afterdepolarisations and enhanced automaticity (not shown). ATP, antitachycardia pacing; CAD, coronary artery disease; fQRS, fragmented QRS complexes; ICM, ischaemic cardiomyopathy; NICM, non-ischaemic cardiomyopathy; VF, ventricular fibrillation; VT, ventricular tachycardia.

and its proximity to the scar/fibrosis, fibrotic density, left ventricular geometry, nature and type of arrhythmias, the number of appropriate and inappropriate shocks, sex differences and disease progression (table 1). With this new information, the prognostic value of fQRS can be more fully assessed.

Molecular basis of fQRS, delayed Ca^{2+} cycling and arrhythmias

Alongside wider and more accurate reporting, there are other gaps in knowledge on the mechanisms responsible for QRS notching and slurring in the viable myocardium itself, beyond scar formation and/or fibrosis. Questions include examining whether the different types of zig-zag patterns in the QRS complex generated *before contraction*, alter Ca^{2+} cycling events *during or following contraction*? The answer appears to be yes. The QRS complex represents the depolarisation wave as it spreads through the heart prior to contraction (figure 3A).¹⁶ In the healthy heart, the three QRS waves last around 70 ms to 100 ms and comprise a rapid phase 0 upstroke and phase 1 transient repolarisation or notch of the ventricular action potential (figure 3B). Phase 0 is mediated by rapid activation and deactivation of voltage-gated Na^+ fast channels (1–2 ms), which opens a tiny window for Na^+ entry and depolarises the membrane from about -85 mV to $+50\text{ mV}$ ¹⁶ (figure 3B). This is followed by a brief period of repolarisation secondary to activation of a transient outward K^+ current (I_{to}) and the $\text{Na}^+/\text{Ca}^{2+}$ exchanger (outward Na^+ movement), which repolarises the membrane from $+50\text{ mV}$ to around $+30\text{ mV}$ or lower (phase 1). This phase ends the QRS complex (figure 3AB).

In the failing heart, changes in the ventricular action potential include a reduction in the rate of depolarisation and peak depolarisation during phase 0, and a decrease in the repolarisation (or even complete loss of the notch) in phase 1.^{17 18} The loss of the phase 1 notch is believed due to downregulation of the I_{to} . Cooper and colleagues further showed that the loss of the notch in ventricular myocytes reduces the magnitude of Ca^{2+} transient from the sarcoplasmic reticulum, alters the time course of the Ca^{2+} transient and decreases the synchrony of later Ca^{2+} spark production with loss of excitation–contraction coupling.^{17 18} Thus, changes to the QRS complex that occur *before contraction* can alter intracellular Ca^{2+} cycling *during contraction*. New therapies targeting the restoration of phase 1 repolarisation and/or other defects in phase 0 may improve cardiac function in patients with HF and reduce arrhythmias by reducing early and delayed Ca^{2+} -triggered after depolarisations.¹⁸ These drugs should protect against arrhythmias without negative inotropic effects. However, a key question remains: How are the notches and slurring in the QRS complex related to these aberrant Ca^{2+} releases, reduced late Ca^{2+} spark rates and/or increased arrhythmogenesis in primary prevention HF patients? Advances in the molecular basis of fQRS and aberrant Ca^{2+} cycling in the myocardium may also apply to other arrhythmogenic cardiomyopathies.



What are the effects of fQRS on arrhythmicity?

Figure 3 Schematic of the normal ECG (A), ventricular action potential (B) and changes in intracellular Ca^{2+} in normal and failing heart (C) over the duration of a single heartbeat. Modified after Cooper *et al.*¹⁷ Vertical lines separate the precontraction QRS complex from later contraction and relaxation phases. The molecular events underlying the different forms of fQRS, myocardial fibrosis and arrhythmias are not known (see text). I_{to} , cardiac transient outward potassium current; I_{Kr} , rapid delayed rectifier channel current for action potential repolarisation; I_{Ks} , another major outward current responsible for repolarisation; I_{K1} , inwardly rectifying potassium current that stabilises the resting membrane potential and is responsible for shaping the initial depolarisation and final repolarisation of the ventricular action potential.

CONCLUSION

Before fQRS can become a potential prognostic candidate for primary prevention ICD placement in patients with HF, wider and more accurate reporting is urgently required into the different forms of fQRS in the failing heart and their effect on the formation of an arrhythmogenic substrate, particularly encircling a scar or fibrotic architecture.

Acknowledgements The authors would like to thank the College of Medicine and Dentistry at James Cook University, Townsville, the Townsville University Hospital and Townsville Hospital and Health Service (THHS) Study, Education and Research Trust Account (SERTA) for their support of the work.

Contributors GPD, NE, KN and HLL contributed equally to literature search, study design, data interpretation and writing of the manuscript. All authors contributed to the article and approved the submitted version.

Funding The study was supported by a Townsville Hospital and Health Service (THHS) Study, Education and Research Trust Account (SERTA) research grant (2020_12). NE is also supported by a THHS SERTA fellowship (2021_12).

Competing interests None declared.

Patient consent for publication Not applicable.

Ethics approval Not applicable.

Provenance and peer review Not commissioned; externally peer reviewed.

Open access This is an open access article distributed in accordance with the Creative Commons Attribution Non Commercial (CC BY-NC 4.0) license, which permits others to distribute, remix, adapt, build upon this work non-commercially, and license their derivative works on different terms, provided the original work is properly cited, appropriate credit is given, any changes made indicated, and the use is non-commercial. See: <http://creativecommons.org/licenses/by-nc/4.0/>.

ORCID iD

Hayley Louise Letson <http://orcid.org/0000-0003-0135-134X>

REFERENCES

- Haukilahti MAE, Eranti A, Kenttä T, *et al.* QRS fragmentation patterns representing myocardial scar need to be separated from benign normal variants: hypotheses and proposal for morphology based classification. *Front Physiol* 2016;7:653.
- Breitenstein A, Steffel J. Devices in heart failure Patients-Who benefits from ICD and crt? *Front Cardiovasc Med* 2019;6:111.
- Engstrom N, Dobson GP, Ng K, *et al.* Primary prevention implantable cardiac defibrillators: a Townsville district perspective. *Front Cardiovasc Med* 2020;7:1–11.
- Klein HU, Goldenberg I, Moss AJ. Risk stratification for implantable cardioverter defibrillator therapy: the role of the wearable cardioverter-defibrillator. *Eur Heart J* 2013;34:2230–42.
- Klem I, Klein M, Khan M, *et al.* Relationship of LVEF and myocardial scar to long-term mortality risk and mode of death in patients with nonischemic cardiomyopathy. *Circulation* 2021;143:1343–58.
- S-J W, Hsieh Y-C. Sudden cardiac death in heart failure with preserved ejection fraction: an updated review. *Int J Arrhythm* 2022;23.
- Das MK, Zipes DP. Fragmented QRS: a predictor of mortality and sudden cardiac death. *Heart Rhythm* 2009;6:S8–14.
- Langner PH. Further studies in high fidelity electrocardiography: myocardial infarction. *Circulation* 1953;8:905–13.
- Flowers NC, Horan LG, Johnson JC. Anterior infarctional changes occurring during mid and late ventricular activation detectable by surface mapping techniques. *Circulation* 1976;54:906–13.
- Take Y, Morita H. Fragmented QRS: what is the meaning? *Indian Pacing Electrophysiol J* 2012;12:213–25.
- Das MK, Suradi H, Maskoun W, *et al.* Fragmented wide QRS on a 12-lead ECG: a sign of myocardial scar and poor prognosis. *Circ Arrhythm Electrophysiol* 2008;1:258–68.
- Lachlan T, He H, Sharma K, *et al.* MAGNETO cardiography parameters to predict future sudden cardiac death (MAGNETO-SCD) or ventricular events from implantable cardioverter defibrillators: study protocol, design and rationale. *BMJ Open* 2020;10:e038804.
- Engstrom N, Dobson G, Ng K, *et al.* Fragmented QRS is associated with ventricular arrhythmias in heart failure patients: a systematic review and meta-analysis. *Noninvasive Electrocardiol* 2022;27:e12910.
- Supreeth RN, Francis J. Fragmented QRS - Its significance. *Indian Pacing Electrophysiol J* 2020;20:27–32.
- Ratheendran AC, Subramanian M, Bhanu DK, *et al.* Fragmented QRS on electrocardiography as a predictor of myocardial scar in patients with hypertrophic cardiomyopathy. *Acta Cardiol* 2020;75:42–6.
- George AL. Molecular and genetic basis of sudden cardiac death. *J Clin Invest* 2013;123:75–83.
- Cooper PJ, Soeller C, Cannell MB. Excitation–contraction coupling in human heart failure examined by action potential clamp in rat cardiac myocytes. *J Mol Cell Cardiol* 2010;49:911–7.
- Fowler ED, Wang N, Hezzell M, *et al.* Arrhythmogenic late Ca²⁺ sparks in failing heart cells and their control by action potential configuration. *Proc Natl Acad Sci U S A* 2020;117:2687–92.