


# Tear of Vaginal Lobular Capillary During Micturition Resulting in Vesicovaginal Fistula: A Case Report

Raha Maroyi <sup>1,2</sup>, Ajay Rane<sup>3</sup>, Lynsey Hayward<sup>4</sup>, Chasinga Baharanyi<sup>2,5</sup>,  
Bwihangane Birindwa Ahadi <sup>2</sup>, Denis Mukwege<sup>1,2</sup>

<sup>1</sup>Department of Obstetrics and Gynecology, Panzi General Referral Hospital, Bukavu, The Democratic Republic of Congo; <sup>2</sup>Université Evangélique en Afrique (UEA), Bukavu, The Democratic Republic of Congo; <sup>3</sup>Department of Obstetrics and Gynaecology, James Cook University, Townsville, QLD, Australia; <sup>4</sup>Department of Urogynaecology, Middlemore Hospital, Auckland, New Zealand; <sup>5</sup>Department of Pathology, Panzi General Referral Hospital, Bukavu, The Democratic Republic of Congo

Correspondence: Raha Maroyi, Université Evangélique en Afrique (UEA), P.O. Box 3323, Bukavu, The Democratic Republic of Congo, Tel +243997254812, Email ken.raha01@gmail.com

**Abstract:** We report an unusual case of female genital fistula secondary to a lobular capillary hemangioma. A 35-year-old Congolese woman presented with urinary incontinence associated with a vaginal “tearing” sensation during micturition. A suburethral vascular bud and vesico-vaginal fistula were observed on examination. Over 2 weeks, the fistula enlarged to involve the trigone and bladder neck, resulting in a semi-circumferential urethro-vesico-vaginal fistula. Histology revealed a lobular capillary hemangioma. During fistula repair, the edges with vascular clusters were freshened, the genital fistula was closed and the woman became continent of urine.

**Keywords:** vesico-vaginal fistula, female genital fistula, lobular capillary hemangioma, etiology, surgical procedure

## Introduction

Lobular capillary hemangioma (LCH), previously termed pyogenic granuloma, is a benign proliferative vascular lesion of unknown etiology.<sup>1,2</sup> It is a common disease characterized by the rapid growth of vascular tissue on cutaneous and mucosal surfaces and is most commonly found in the oral cavity.<sup>3,4</sup> LCH can occasionally be associated with lesions of the respiratory, digestive and genital tracts.<sup>3</sup> Nevertheless, it is rarely cited as an etiology of female genital fistula. Histologically, there is a proliferative and pedunculated vascular lesion of the capillaries which are arranged in a lobular fashion. There are central ectatic vessels without endothelial atypia.<sup>3,4</sup>

We present a case of LCH which resulted in the development of a rapidly enlarging semi-circumferential vesico-urethro-vaginal fistula which was successfully repaired.

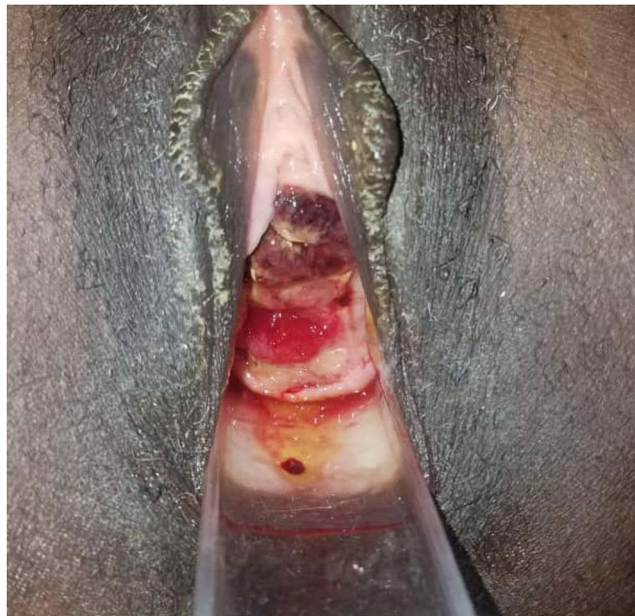
## Case Presentation

A 35-year-old African (Congolese) woman was admitted to the Panzi Hospital with a 4-day history of continuous urinary incontinence and dysuria, having previously been continent. The patient described a violent sensation of tearing whilst voiding and a popping sensation akin to the opening of a bottle cap immediately prior to becoming incontinent with blood-stained urine.

## Clinical Findings and Diagnostic Investigations

The patient was G9/P9 with her last normal childbirth 18 months prior to presentation. There was no evidence of genital prolapse and otherwise she had no significant medical or surgical history. On arrival, she looked unwell. Her BP was 95/64 mmHg, pulse rate at 126 beats per minute, temperature 36°C and BMI 17.6.

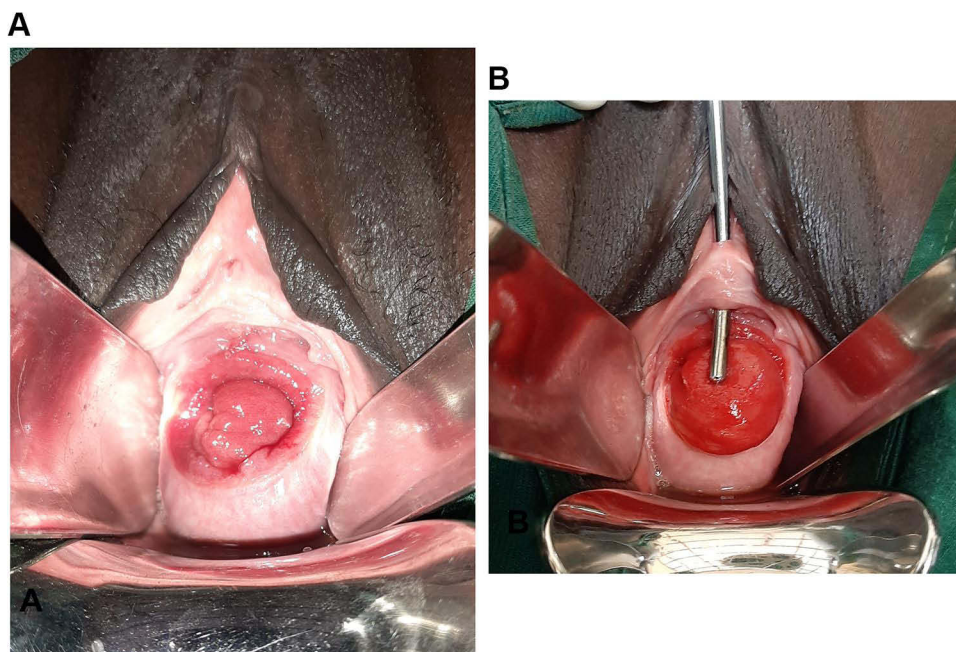
Initial vaginal examination revealed labia stained with urine and blood. There was a suburethral haematoma above a 2 cm vesico-vaginal fistula (Figure 1). We noted severe anemia (Hb: 6.4 g/dL). In addition, her urine culture was negative.



**Figure 1** Suburethral haematoma above the vesico-vaginal fistula.

## Management

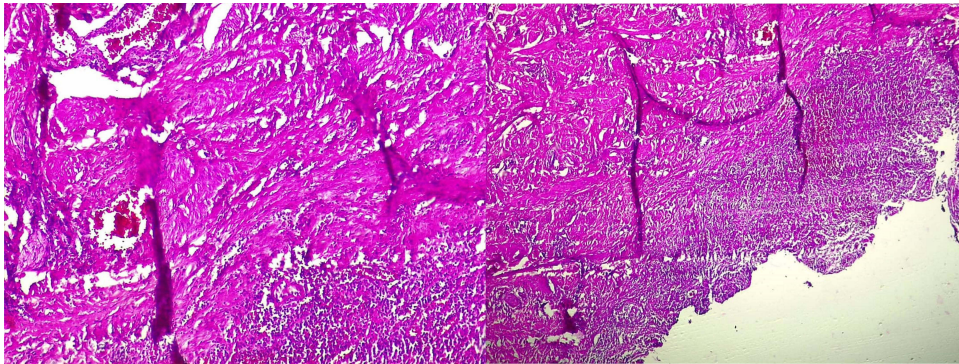
She was treated immediately on arrival with two units blood transfusion and became hemodynamically stable antibiotic therapy, hygienic and dietary measures were instituted. After two weeks of conservative measures, the edges of the fistula became clean and rosy, delineating a semi-circumferential fistula involving a portion of the trigone, the bladder neck and the urethra (Figure 2). The urethral length was 1.3cm, the vesico-vaginal fistula size was 3.5cm with the ureters situated 0.5 cm from the edge (Figure 2). She underwent an examination under anaesthetic after initial resuscitation and biopsies were taken for the edge of the fistula. A double check analysis was done in two regional pathology laboratories. Biopsy results revealed a squamous mucosa with an epithelium without notable histological lesions. The dermis was



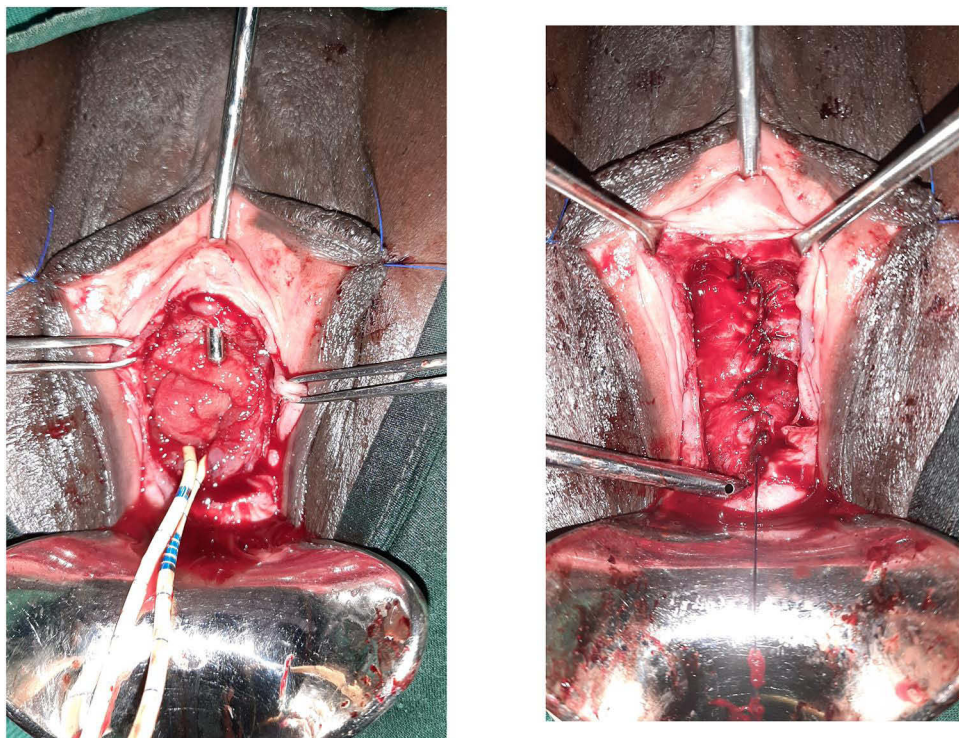
**Figure 2** (A) Disappearance of the sub urethral haematoma. (B) Semi-circumferential vesico-urethrovaginal fistula.

characterized by extensive angiogenic activity, congestion and mixed moderate inflammatory infiltrates diagnostic of lobular capillary hemangioma (Figure 3).

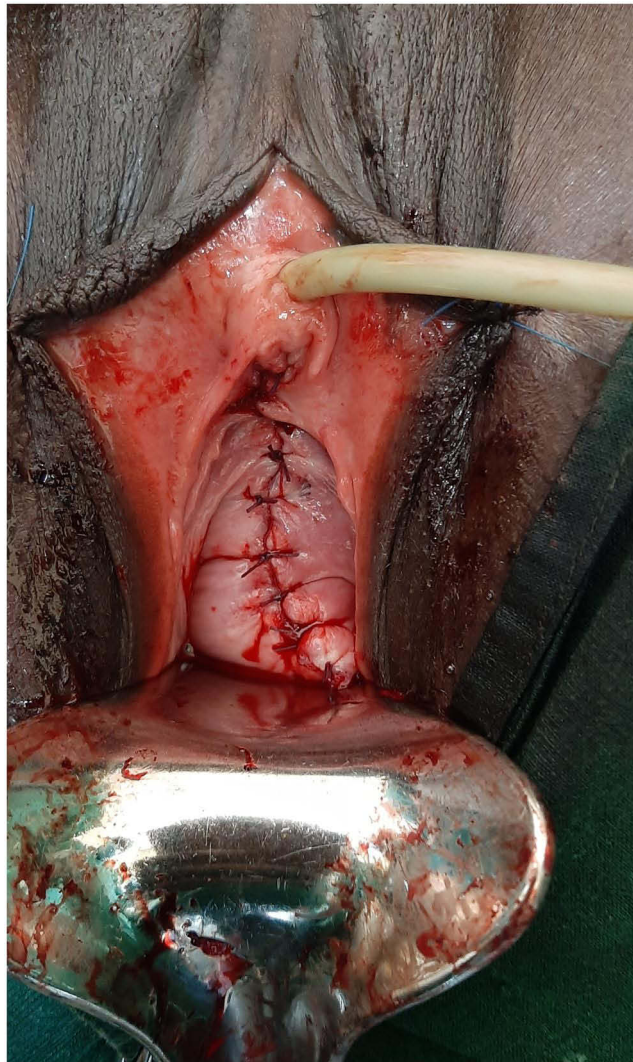
We performed a repair of the vesico-urethro-vaginal fistula (Figure 4), using sharp dissection after the incision around the edge of the fistula. The ureters were protected with ureteric stents. The bladder was mobilized and the edge of the fistula trimmed. In contrast to classic obstetrical and gynecological traumatic fistula repair, the bladder wall on this fistula was found to be haemorrhagic and friable. Haemostasis was obtained using diathermy. Interrupted sutures in one layer were performed using vicryl 2/0 with longitudinal approximation of the fistula edges and the reconstruction of the vesico-urethral junction by lengthening the urethra (narrowing) under a metallic catheter. The urethral length established was approximately 3.5cm. A size 12 French Foley bladder indwelling catheter was left for 14 days. After a negative dye test, the vaginal mucosa was closed (Figure 5). A vaginal pack was placed for 24 hours.



**Figure 3** Microscopic aspect of lobular capillary hemangioma.



**Figure 4** Surgical management of the fistula.



**Figure 5** Final aspect after fistula repair (vaginal closure).

## Outcome

Following her catheter removal, the patient was able to void normally with no stress or urge incontinence. She received counseling on fistula prevention as well as contraception. Genital examination was normal and she was discharged 48 hours later. We reviewed the patient 3 months post operatively and found that she was continent with no voiding dysfunction.

## Discussion

The most well-known cause of urogenital fistula is obstetric. However, there are other causes. A lobular capillary hemangioma has never been reported as the cause of vesico-vaginal fistula.

LCH is well known as a very common benign vascular tumor. It frequently develops at the expense of epithelial tissue, such as skin and mucous membranes. Subcutaneous and intravenous variants have also been described.<sup>1</sup> Histologically, we note a hyperplastic capillary cluster separated by a lobule containing a feeder vessel in the center.<sup>4</sup>

Its etiology is unknown. Nevertheless, it is considered to be a reactive tumor lesion caused by various stimuli such as chronic low-grade irritation, traumatic injury, hormonal effect or drug-induced reaction.<sup>4</sup> LCH most commonly appears lobular capillary hemangioma appears in early childhood and in the second decade of life in women, probably as a result of the vascular effects of hormonal changes.<sup>1</sup>

To our knowledge, this is the first case of lobular capillary hemangioma reported in isolation and primary form as the cause of genital fistula. A case of vesico-vaginal fistula has been described on a vaginal sling, associated with granuloma.<sup>5</sup>

Our case is specific with regard to his history describing sudden vaginal urine loss during voiding effort with a sensation of vaginal tearing. Initial breakdown within the LCH resulted in a small fistula with a suburethral vascular bud and this process progressed over the following weeks to a semi-circumferential urethro-vesico-vaginal fistula involving partially the trigone and the urethra including the bladder neck. The involvement of the LCH into the bladder trigone may be explained by the trigones susceptibility to vascular effects secondary to hormonal changes.<sup>1</sup>

Generally, to treat a vesico-vaginal fistula properly, it is necessary to understand the etiology. Thus, particularly in this context, the biopsy was of great significance in tailoring our surgical repair. The specificity in the treatment of a genital fistula secondary to a lobular capillary hemangioma is the sharpening of the banks presenting clusters of vascular vessels, but the steps of the surgical technique for vesico-vaginal fistula are respected. The outcome has been good with a closed fistula and the woman has returned to being urinary continent.

## Conclusion

Lobular capillary hemangioma is extremely rare cause of urogenital fistula. A histological diagnosis and an understanding of the natural history of LCH are imperative to the use of precise surgical techniques that can result in the successful primary closure in fistulae secondary to LCH.

## Abbreviations

LCH, lobular capillary hemangioma; BMI, body mass index; Hb, hemoglobin; B-HCG, beta-human chorionic gonadotropin; VVF, vesico-vaginal fistula.

## Consent

Written informed consent was obtained from the patient for publication of this case report and any accompanying images. A copy of the written consent is available for review by the Editor-in-Chief of this journal.

## Acknowledgments

The authors would like to thank the patient.

## Author Contributions

All authors made a significant contribution to the work reported, whether that is in the conception, study design, execution, acquisition of data, analysis and interpretation, or in all these areas; took part in drafting, revising or critically reviewing the article; gave final approval of the version to be published; have agreed on the journal to which the article has been submitted; and agree to be accountable for all aspects of the work.

## Disclosure

The authors report no conflicts of interest in this work.

## References

1. Gameiro A, Cardoso JC, Calonje E, Tellechea O. Intravascular lobular capillary hemangioma in the corpus spongiosum. *Am J Dermatopathol*. 2016;38(1):e15–e17. PMID: 26730699. doi:10.1097/DAD.0000000000000376
2. Akamatsu T, Hanai U, Kobayashi M, Miyasaka M. Pyogenic granuloma: a retrospective 10-year analysis of 82 cases. *Tokai J Exp Clin Med*. 2015;40(3):110–114. PMID: 26369264.
3. Barasoain-Millán A, Rodríguez-Contreras FJ, Guerrero-Fernández J, Merino MB, González-Casado I. Pyogenic granuloma, an unusual presentation of peripubertal vaginal bleeding. Case report and review of the literature. *J Pediatr Endocrinol Metab*. 2015;28(3–4):443–744. doi:10.1515/jpem-2014-0029
4. Sparsa A, Bonnetblanc JM, Roux C, et al. Botriomycomes révélant une fistule et un foyer infectieux profond: cinq cas [Pyogenic granuloma revealing fistula and deep infection: five cases]. *Ann Dermatol Venerol*. 2006. 133(10):763–766. French. PMID: 17072190. doi:10.1016/s0151-9638(06)71039-0
5. Lim YN, Rane A. Suburethral vaginal erosion and pyogenic granuloma formation: an unusual complication of intravaginal slingplasty (IVS). *Int Urogynecol J*. 2004;15:56–58. doi:10.1007/s00192-003-1092-x

**International Medical Case Reports Journal**

Dovepress

**Publish your work in this journal**

The International Medical Case Reports Journal is an international, peer-reviewed open-access journal publishing original case reports from all medical specialties. Previously unpublished medical posters are also accepted relating to any area of clinical or preclinical science. Submissions should not normally exceed 2,000 words or 4 published pages including figures, diagrams and references. The manuscript management system is completely online and includes a very quick and fair peer-review system, which is all easy to use. Visit <http://www.dovepress.com/testimonials.php> to read real quotes from published authors.

Submit your manuscript here: <https://www.dovepress.com/international-medical-case-reports-journal-journal>