



Intestinal Perforation Due to Adult Tapeworm of *Taenia*: A Case Report and Review of the Literature

Raju Bhandari^{1,2} , Rajan Chamlagain³, Edward Sutanto⁴ , Hammad Adam^{1,2}, Anil Dhungana², Aishnath Azna Ali², Bimochan Piya², Abdulla Ubaid² and Andreas Neumayr^{5,6,7}

¹Department of General and GI Surgery, Tribhuvan University Teaching Hospital, Institute of Medicine, Kathmandu, Nepal. ²Department of Surgery, Indira Gandhi Memorial Hospital, Male, Maldives. ³Tribhuvan University Teaching Hospital, Institute of Medicine, Kathmandu, Nepal. ⁴Roswell Park Comprehensive Cancer Center, Buffalo, New York, USA. ⁵Department of Medicine, Swiss Tropical and Public Health Institute, Basel, Switzerland. ⁶University of Basel, Basel, Switzerland. ⁷Public Health and Tropical Medicine, College of Public Health, Medical and Veterinary Sciences, James Cook University, Townsville, Australia.

Clinical Medicine Insights: Case Reports
Volume 15: 1–5
© The Author(s) 2022
Article reuse guidelines:
sagepub.com/journals-permissions
DOI: 10.1177/11795476211072670


ABSTRACT: Taeniasis is an intestinal helminth infection due to adult tapeworms belonging to the genus *Taenia*. Taeniasis remains a major burden in low-income countries in Asia. We present a case of intestinal perforation caused by adult tapeworm of *Taenia* in a 50-year-old Nepali male. The patient presented to the hospital with severe abdominal pain and intermittent vomiting. Following clinical presentations and imaging features, gastrointestinal perforation was suspected. Surgical removal of adult tapeworm of *Taenia*, suspected to be *T. saginata* or *T. asiatica*, was carried out during exploratory laparotomy, which was followed by an uneventful postoperative period. In addition to case presentation, we systematically review published case reports on taeniasis-related intestinal perforation. A learning point from this case is clinician should maintain a clinical suspicion of taeniasis as a possible cause of intestinal perforation in endemic areas.

KEYWORDS: Case report, *Taenia saginata*, taeniasis, intestinal perforation, ileum

RECEIVED: October 11, 2021. **ACCEPTED:** December 3, 2021.

TYPE: Case Report

FUNDING: The author(s) received no financial support for the research, authorship, and/or publication of this article.

DECLARATION OF CONFLICTING INTERESTS: The author(s) declared no potential conflicts of interest with respect to the research, authorship, and/or publication of this article.

CORRESPONDING AUTHOR: Raju Bhandari, Department of General and GI Surgery, Tribhuvan University and Teaching Hospital (TUTH), Institute of Medicine, Kirtipur-2, Tyanglaphat Chowk, Kathmandu 44600, Nepal. Email: rbiom27@gmail.com

Introduction

Taeniasis is an intestinal infection caused by adult tapeworms. Three parasite species cause taeniasis in humans: *Taenia solium* (pork tapeworm), *Taenia saginata* (beef tapeworm), and *Taenia asiatica* (a species phylogenetically closely related to *T. saginata*).¹ The human definitive host gets infected with *T. saginata* and *T. solium* by eating undercooked meat of the parasites' respective intermediate host (*T. saginata*: cattle; *T. solium*: pigs) harboring the infective larval stage of the parasite (cysticerci).^{2,3} The life cycle of *T. asiatica* differs from that of *T. saginata* in its intermediate host (pigs vs cattle) as well as in the infected organs (liver vs muscle).¹

Most human taeniasis infections are asymptomatic and the only noticeable sign of infection is the passing of proglottids in the stool.⁴ Nevertheless, unspecific gastrointestinal symptoms like nausea, vomiting, vague abdominal discomfort or pain, increased appetite, weight loss, or pruritus ani may be present.^{4,5}

The diagnosis of taeniasis is made through the patient's history (passing of proglottids), macroscopic identification of proglottids, or the microscopic detection of eggs in stool samples. Confirmation of *Taenia* species is conducted by morphological examination of tapeworm (adult tapeworm length, scolex [presence of rostellum], neck, and proglottid).³ While *Taenia* eggs are microscopically indiscriminable, proglottids allow morphological species determination by assessing the number

of primary uterine branches. Fewer than 13 primary uterine branches correspond to *T. solium*, more than 13 uterine branches correspond to either *T. saginata* or *T. asiatica*.³ The proglottids morphology of *T. saginata* and *T. asiatica* is practically the same and, although the 2 species may be differentiable based on morphological features by experts,¹ the differentiation of the 2 species is mostly done by molecular diagnostic methods like polymerase chain reaction (PCR).⁶ Taeniasis is easily treated by application of a single oral dose of praziquantel (10–20 mg/kg body weight) or niclosamide (adults: 2 g; children: 50 mg/kg body weight).⁷

We report and discuss the case of ileal perforation due to adult tapeworm of *Taenia* in an academic hospital in low-resource setting and systematically review published case reports on taeniasis. The SCARE 2020 Guideline was used to guide the writing of this case report.⁸

Case Description

A 50-year-old male from Gorkha district of Gandaki Province, Nepal presented to the emergency room of the Tribhuvan University Teaching Hospital (Kathmandu, Nepal) with increasingly severe abdominal pain for a day and a history of generalized abdominal pain, intermittent vomiting, and fever for 15 days. The patient denied history of traveling to any foreign countries. At admission, he was afebrile, hypotonic, and tachycardic with a blood pressure of 80/60 mmHg and a pulse



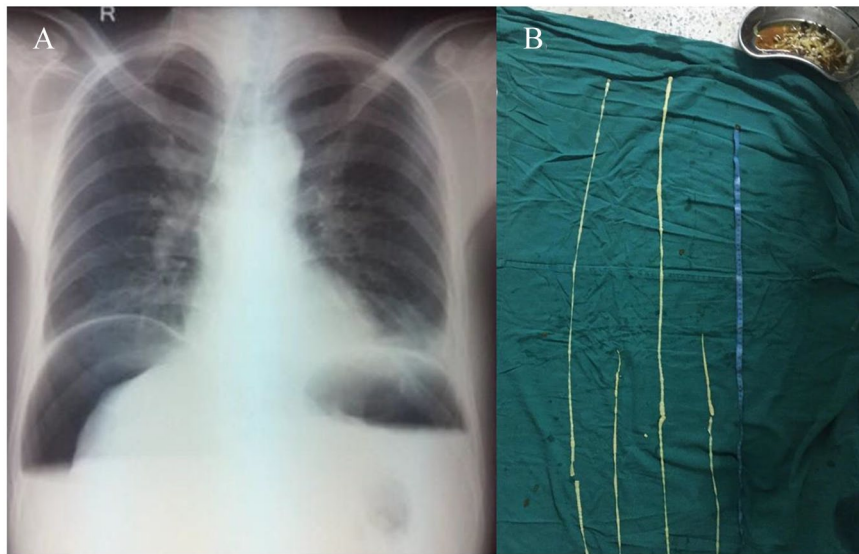


Figure 1. (A) Chest X-ray at hospital admission showing free air under the diaphragm. (B) Removed *Taenia saginata* tapeworms (two worms measuring approx. 2 and 3 m [laid out on surgical drape] and strobila parts [in metal kidney dish]).

rate of 100/min. The physical examination revealed generalized abdominal tenderness, guarding, and rebound tenderness but was otherwise unremarkable. Abdominal ultrasonography showed free intraperitoneal fluid in the left upper quadrant and a thickened small bowel wall and the chest X-ray revealed free air under the diaphragm on both sides establishing the diagnosis of pneumoperitoneum (Figure 1A). The full blood count showed leukocytosis (WBC 17400/mm³; 78% neutrophils, 20% lymphocytes).

With the provisional diagnosis of gastrointestinal perforation, the patient was taken to the operation theater and an exploratory laparotomy was performed. The exploratory laparotomy showed approximately 200 ml of pus in the peritoneal cavity, dilated small bowel loops, a single ileal perforation measuring $\sim 2 \times 2$ cm at the antimesenteric border ~ 20 cm proximal of the ileocaecal junction. Through the perforation site 2 large *Taenia* tapeworms, measuring approximately 2 and 3 m, as well as several smaller *Taenia* worms protruded through the perforation site (Figure 1B). After cleaning of the peritoneal cavity, removal of the *Taenia* worms, and closure of the perforation site, a loop ileostomy was performed. The rationale behind the loop ileostomy was that it was impossible to rule out the presence of additional *Taenia* tapeworms possibly leading to obstruction in the postoperative period. To eradicate any possibly remaining *Taenia* tapeworms, the patient received a single oral dose of praziquantel (400 mg).

The patient denied any history of passing proglottids, however, based on microscopic analysis of the morphology of scolex and proglottids (number of uterus branches observed), it may be concluded that this parasite is suspected to be *T. saginata* or *T. asiatica*. Due to resource limitations in our hospital, we are not able to conduct PCR test to further differentiate the parasite. The histopathological examination of the excised margin of the perforation site showed granulation tissue with signs of acute and chronic inflammation involving the full thickness of

the bowel wall. No atypical cells or granulomas were seen. When the culture of the peritoneal fluid revealed the presence of extended-spectrum beta-lactamase-producing *Klebsiella pneumoniae* and *Escherichia coli*, the patient was treated, according to the susceptibility testing results, with meropenem (1 g i.v. 3 times per day) for 7 days. The remainder of the post-operative period was uneventful, and the patient was discharged on the eighth post-operative day. After 1 year of follow-up, no additional complaint or recurrence was reported.

Discussion

Although *Taenia* has a worldwide distribution, its occurrence is more common in low-income countries. Substantial prevalence of *T. saginata*, considered the most common zoonotic tapeworm, has been reported throughout East, Southeast, and South Asia due to lack of adequate sanitation, food safety measures, and health education standards.⁹ As the consumption of beef is extremely uncommon in Nepal due to socio-cultural context (cow is considered sacred and existing ban for cow slaughter), it is more likely that the patient's infection is due to *T. asiatica*. We speculate consumption of pig liver would be the most likely source of infection in this case.

Although rare, several intestinal as well as extra-intestinal complications due to taeniasis have been reported. A systematic literature review conducted in 2017 on surgical abdominal pathologies caused by helminths identified following numbers of case reports on *T. saginata* related complications: appendicitis (n=11), gastrointestinal perforation (n=5), migration of biliary tract (n=3), intestinal obstruction (n=2), acute cholecystitis (n=2), and duodenal stump leakage (n=2).¹⁰ Other complications (n=1) reported include acute abdomen, gallbladder perforation, colonic anastomosis leakage, esophageal leak, acute cholangitis, acute pancreatitis, Meckel's diverticulitis, and acute intestinal bleeding.¹⁰ Of note, no case reports on

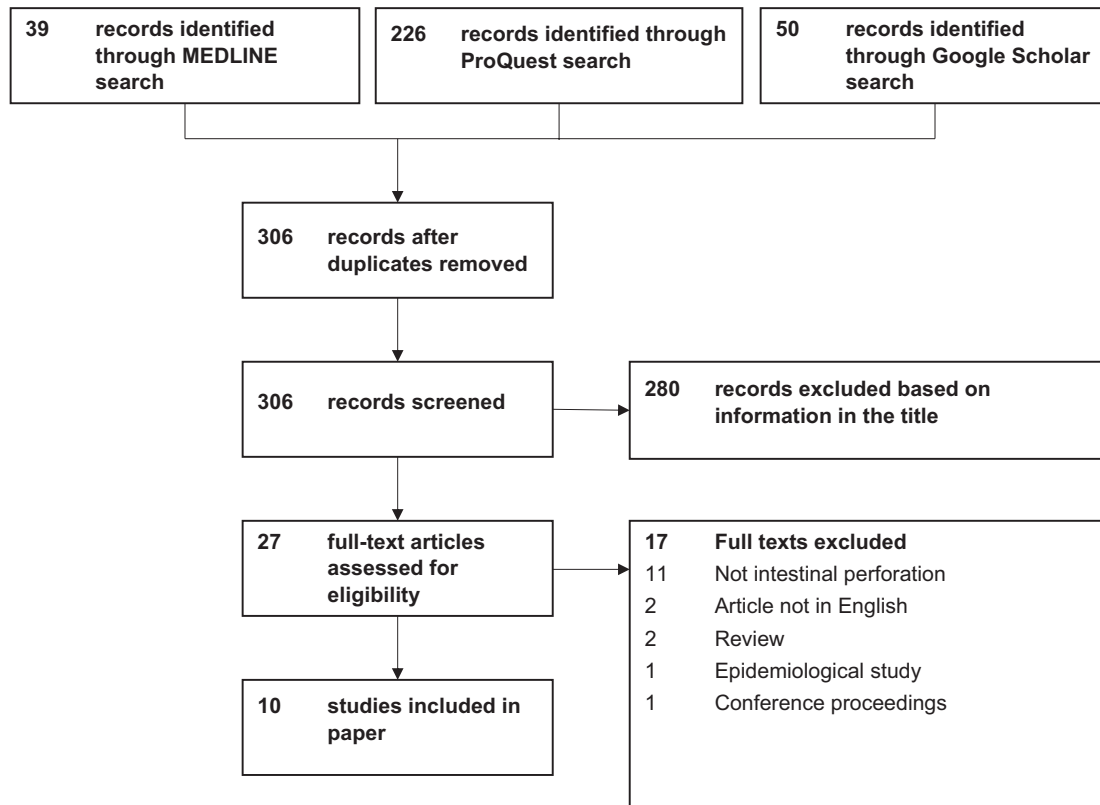


Figure 2. Flow diagram of literature review.

surgical abdominal complications due to *T. solium* were identified in this review.

We systematically conducted a review of published case reports on taeniasis-related intestinal perforation. A search was conducted on 14 April 2021 of Medline, ProQuest, and Google Scholar (first 50 results only) using the following broad search string: “(taenia*) AND (case report* OR case series) AND (gastrointestinal perforation OR intestinal perforation OR peritonitis).” Initial 306 records were screened by title and narrowed down to 10 case reports (as detailed in Figure 2). Details of the included case reports are displayed in Table 1.

The underlying pathophysiology of taeniasis-related intestinal perforation is not entirely clear. The most often quoted theory is that the impaction/mechanical obstruction of the gut lumen, by a bulk formed by the parasite’s strobila, enhances the parasite’s mucosal contact.¹⁹ This parasite-mucosa contact is considered to cause a local irritative inflammatory reaction that predisposes to perforation. As seen in Table 1, the observation that the most frequent perforation site is the small bowel indirectly supports this theory, since there the intestine’s luminal diameter is narrowest which provides favorable conditions.²¹

In line with this mechanical theory, the absence of reports on *T. solium* taeniasis related intestinal perforation (Table 1) may be explained by the overall smaller average size/length of the adult parasite (*T. solium*: 2–7 m vs *T. saginata*: 4–12 m),⁷ which lowers the likelihood of the worm’s impaction. Based on mechanical theory, a high number of worms would also

predispose to perforation. While the finding of two large and several smaller tapeworms in our case would support this assumption, the majority of case reports report only a single worm (Table 1). However, since it is impossible to inspect the entire length of the intestinal lumen, the presence of multiple worms can never be excluded.

Regarding extraintestinal complications, *T. solium* shows also considerably less potential for complications. Yu et al²² reported a case of cholecystitis caused by *T. solium* and reviewed the published literature in 2019. They found that previously only 16 case reports of hepato-pancreatico-biliary taeniasis have been published (reporting *Taenia* tapeworms in the gallbladder [n = 10], the pancreatic duct [n = 3], the bile duct [n = 2], and as a cause of a liver abscess [n = 1]) and that all 16 cases were related to *T. saginata* or *T. asiatica*.²² This disproportionate finding may be explained by the fact that the proglottids of *T. saginata* and *T. asiatica* show active motility, thus allowing for extraintestinal migration of the parasite, while *T. solium* proglottids lack active motility.²³ The active motility of *T. saginata* tapeworms may also explain their reported emergence from an anastomotic leakage site and a post-appendectomy fecal fistula.^{24,25}

Interestingly, when reviewing the literature on complications related to *Diphyllobothrium latum* (fish tapeworm), which is the largest tapeworm that can infect humans (up to 25 m in length),²⁶ massive infections have been reported to cause intestinal obstruction and aberrant migrating proglottids may cause cholangitis or cholecystitis.²⁶ However, we were only able to

Table 1. Case reports on intestinal perforations related to taeniasis.

AUTHORS	NO. OF CASE	AGE	SEX	TAENIA SPECIES	NUMBER OF WORMS	SITE OF PERFORATION	COUNTRY	SPECIFIC PATHOLOGY
Soosaraei et al ¹¹	1	54	F	<i>T. saginata</i>	1	Ileum	Iran	Intestinal obstruction and perforation leading to necrosis, and volvulus
Bekraki and Hanna ¹²	1	69	M	<i>T. saginata</i>	1	Jejunum	Lebanon	Perforation
Scorza et al ¹³	1	60	F	<i>T. saginata</i>	1	Duodenum	Uruguay	Perforation
Sozutek et al ¹⁴	1	49	M	<i>T. saginata</i>	1	Caecum	Turkey	Perforation
Singh et al ¹⁵	1	35	M	<i>T. saginata</i>	2	Ileum	India	Perforation 20 cm proximally to the ileocaecal junction
Jongwutiwes et al ¹⁶	1	32	F	<i>T. saginata</i>	1	Jejunum	Thailand	Perforation 20 cm distally to the ligament of Treitz
Jain et al ¹⁷	1	4	F	<i>T. saginata</i>	1	Ileum	India	Perforation
Demiriz et al ¹⁸	1	n.d.	n.d.	<i>T. saginata</i>	1	Colon	Turkey	Perforation
Lenoble and Dumontier ¹⁹	1	40	F	<i>T. saginata</i>	1	Ileum	India	Perforation
Dev ²⁰	1	13	M	<i>T. saginata</i>	1	Appendix	India	Perforation

Abbreviations: F, female; M, male; n.d., no data.

identify 3 case reports, which reported occlusion,²⁷ intermittent obstructive symptoms,²⁸ and subacute appendicitis,²⁹ and we could not find any case report on intestinal perforation or biliary complications related to human diphyllobothriasis.

Conclusion

Taeniasis remains prevalent in low-income countries with *T. saginata* as the most common zoonotic tapeworm. *T. saginata* and *T. asiatica* tapeworms are more likely to cause intestinal and extraintestinal complications compared to *T. solium* tapeworms. Due to similarity in a morphological feature, a PCR test is needed to provide definitive specimen confirmation for *Taenia spp.* In an endemic region, clinician should maintain a clinical suspicion of taeniasis as a possible cause of intestinal perforation.

Acknowledgements

We thanked Dr. Dhruba Narayan Sah and Dr. Ranjut Sah for their support in this study.

Author Contribution

R.B: conceptualization, methodology, formal analysis, investigation, writing—original draft, visualization. R.C: writing—original draft. E.S: formal analysis, writing—review and editing, visualization. H.A: investigation, writing—review and editing. A.D: writing—review and editing. A.A.A: writing—review and editing. B.P: writing—review and editing. A.U: writing—review and editing. A.N: formal analysis, writing—review and editing, visualization, supervision. All authors approved the final version of the manuscript.

Ethical Approval

This study is exempted from ethical approval from Tribhuvan University Teaching Hospital.

Informed Consent

Written informed consent was obtained from the patient for publication of this case report and accompanying images.

ORCID iDs

Raju Bhandari  <https://orcid.org/0000-0003-0692-1786>

Edward Sutanto  <https://orcid.org/0000-0002-8852-5770>

REFERENCES

- Eom KS, Rim H-J, Jeon H-K. *Taenia asiatica*: historical overview of taeniasis and cysticercosis with molecular characterization. *Adv Parasitol.* 2020;108:133-173.
- World Health Organization. Taeniasis/cysticercosis. 2020. Accessed April 10, 2021. <https://www.who.int/news-room/fact-sheets/detail/taeniasis-cysticercosis>
- United States Centers for Disease Control and Prevention. Taeniasis. 2017. Accessed March 28, 2021. <https://www.cdc.gov/dpdx/taeniasis/index.html>
- Fan PC, Chung WC, Lin CY, Chan CH. Clinical manifestations of taeniasis in Taiwan aborigines. *J Helminthol.* 1992;66:118-123.
- Karanikas ID, Sakellariadis TE, Alexiou CP, Siaperas PA, Fotopoulos AC, Antsaklis GI. *Taenia saginata*: a rare cause of bowel obstruction. *Trans R Soc Trop Med Hyg.* 2007;101:527-528.
- Galán-Puchades MT, Fuentes MV. *Taenia* species, uterine branches and capsule endoscopy. *Am J Gastroenterol.* 2019;114:356-357.
- Neumayr A. *Antiparasitic Treatment Recommendations: A Practical Guide to Clinical Parasitology.* tredition GmbH; 2016.
- Agha RA, Franchi T, Sohrabi C, Mathew G, Kerwan A. The SCARE 2020 guideline: updating consensus Surgical CAse REport (SCARE) guidelines. *Int J Surg.* 2020;84:226-230.
- Eichenberger RM, Thomas LF, Gabriël S, et al. Epidemiology of *Taenia saginata* taeniasis/cysticercosis: a systematic review of the distribution in East, Southeast and South Asia. *Parasit Vectors.* 2020;13:234.
- Uysal E, Dokur M. The helminths causing surgical or endoscopic abdominal intervention: a review article. *Iran J Parasitol.* 2017;12:156-168.

11. Soosaraei M, Alizadeh S, Fakhar M, Banimostafavi ES, Hezarjaribi HZ. Intestinal perforation and peritonitis due to *Taenia saginata*: a case report from Iran. *Ann Med Surg*. 2017;24:74-76.
12. Bekraki A, Hanna K. Peritonitis caused by jejunal perforation with *Taenia saginata*: report of a case. *J Parasit Dis*. 2016;40:203-204.
13. Scorza VM, Zeoli M, Andreoli G, Valiñas R. [Duodenal perforation associated with *Taenia saginata* infestation]. *Cir Esp*. 2015;93:e63-e64.
14. Sozutek A, Colak T, Dag A, Turkmenoglu O. Colonic anastomosis leakage related to *Taenia saginata* infestation. *Clinics*. 2011;66:363-364.
15. Singh RB, Bakshi N, Pavithran NM. Taenia-induced ileal perforation. *Trop Doct*. 2005;35:243.
16. Jongwutiwes S, Putaporntip C, Chantachum N, Sampatanukul P. Jejunal perforation caused by morphologically abnormal *Taenia saginata* infection. *Infect J*. 2004;49:324-328.
17. Jain PK, Budhwani KS, Gambhir A. Bowel perforation with *Taenia saginata*. *Indian Pediatr*. 1998;35:797.
18. Demiriz M, Günhan O, Celasun B, Aydin E, Finci R. Colonic perforation caused by taeniasis. *Trop Geogr Med*. 1995;47:180-182.
19. Lenoble E, Dumontier C. Perforations of the small intestine and intestinal parasitic diseases. Apropos of a case of peritonitis caused by the perforation of the small intestine combined with *Taenia saginata* infection. *J Chir*. 1988;125:350-352.
20. Dev PG. Acute abdomen due to Taenia. *J Indian Med Assoc*. 1981;76:63-64.
21. Bordon LM. Intestinal obstruction due to *Taenia saginata* infection: a case report. *J Trop Med Hyg*. 1992;95:352-353.
22. Yu HJ, Ahn C-S, Lim S, et al. Biliary taeniasis with cholecystitis: an unusual case of *Taenia solium* infection with a literature review. *Am J Trop Med Hyg*. 2019;100:135-139.
23. King CH. Cestodes (tapeworms). In: Dell G, Douglas R, Bennett J, Dolin R, eds. *Principles and Practice of Infectious Diseases*. 6th ed. Churchill Livingstone; 2005:3285-3293.
24. Dural AC, Celik MF, Temizgonul B, et al. Unusual clinical case: extraluminal manifestation of a tapeworm from the eviscerated midline incision in a post-surgery patient. *J Infect Dev Ctries*. 2015;9:428-430.
25. Najih M, Laraqui H, Njoumi N, et al. *Taenia saginata*: an unusual cause of post-appendectomy faecal fistula. *Pan Afr Med J*. 2016;25:200.
26. Scholz T, Garcia HH, Kuchta R, Wicht B. Update on the human broad tapeworm (genus diphylobothrium), including clinical relevance. *Clin Microbiol Rev*. 2009;22:146-160.
27. Viikari SJ. Occlusion due to the fish tapeworm. *Ann Chir Gynaecol Fenn*. 1951;40:199-201.
28. Vindigni SM, Hahn H, Zhang Q. Intermittent obstructive symptoms in a patient with diphylobothriasis. *Gastrointest Endosc*. 2017;86:1185-1186.
29. Sharma K, Wijarnpreecha K, Merrell N. *Diphylobothrium latum* mimicking sub-acute appendicitis. *Gastroenterol Res*. 2018;11:235-237.