

Arthroplasty in patients with rare conditions

Total knee arthroplasty in patients with extra-articular deformity

Kaushik Hazratwala, MBBS, FRACS, Brent Matthews, MBBS^{*},
Matthew Wilkinson, MBBS, FRACS, Sergio Barroso-Rosa, MD

The Orthopaedic Research Institute of Queensland (ORIQL), Townsville, Queensland, Australia

ARTICLE INFO

Article history:

Received 10 September 2015

Received in revised form

10 November 2015

Accepted 10 November 2015

Available online 12 January 2016

Keywords:

Computer navigation

Corrective femoral osteotomy

Total knee arthroplasty

Distal femoral deformity

ABSTRACT

Multiple acceptable options are available for the correction of distal femoral deformity associated with knee arthritis. The treatment modality should be chosen based on the extent of deformity and attention to preservation of the collateral ligaments. Surgical options range from osteotomy alone, arthroplasty with intra-articular correction, or arthroplasty with extra-articular correction. Different implant choices and fixation methods for the osteotomy possess advantages and disadvantages which need to be considered carefully. In addition to discussing principles of management based on current literature, this article includes a case report using a previously undescribed technique using corrective osteotomy, intramedullary nail fixation, and total knee arthroplasty with computer navigation.

Copyright © 2016 The Authors. Published by Elsevier Inc. on behalf of American Association of Hip and Knee Surgeons. This is an open access article under the CC BY-NC-ND license (<http://creativecommons.org/licenses/by-nc-nd/4.0/>).

Introduction

Distal femoral fractures are rare and often associated with severe injury with an incidence of only 0.4% of the population. The distribution is bimodal with an initial peak seen in males in their 30s and a subsequent peak in elderly females [1].

Internal fixation has been the treatment of choice for most femoral fractures for decades. Before this, skeletal traction was frequently complicated by malunion. Distal femoral fractures were particularly prone to recurvatum deformities owing to tension from the proximal gastrocnemius insertions on the distal fragment.

Malunion is a common complication which most often results in a distal femoral recurvatum with varus deformity. This can predispose the patient to the development of osteoarthritis, which has reported incidence of up to 50% [2]. Painful osteoarthritis, not responsive to nonoperative measures, usually requires total knee arthroplasty (TKA) or osteotomy with correction of the deformity.

When the deformity is not corrected adequately, there is some evidence to show early failure of the procedure [3].

Correction of deformity can be achieved by osteotomy alone, arthroplasty with intra-articular correction, or combined with extra-articular corrective osteotomy. The options for fixation have expanded considerably in the past 25 years, to include long-stemmed revision prosthesis, antegrade and retrograde intramedullary (IM) nails, locking distal femoral plates all of which can be combined with patient-specific or computer navigation–assisted arthroplasty.

Based on an article by Wolff et al., [4] preoperative malalignment in the coronal plane is considered clinically significant when it exceeds 5°, resulting in genu varum or genu valgum. Deformity in the sagittal plane is regarded as significant when it exceeds 10°, resulting in procurvatum or recurvatum [5].

Available literature consists of a number of retrospective cohort series which report good functional outcomes overall in the short term to midterm; however, many studies lack long-term follow-up, the average follow-up revealed from our literature review was 44.9 months. Those that do have long-term data have shown survivorship rates of 93% at 10 years or more [6]. Although there is agreement that the mechanical axis of the limb needs to be restored and the soft tissues balanced, there is no clear consensus in the literature regarding what degree of residual deformity after arthroplasty is acceptable with reports of up to 8° varus [7] to 13° valgus [3]. A guiding principle is that the limb alignment should be corrected by extra-articular osteotomy if intra-articular correction would result in violation of the collateral ligaments.

One or more of the authors of this paper have disclosed potential or pertinent conflicts of interest, which may include receipt of payment, either direct or indirect, institutional support, or association with an entity in the biomedical field which may be perceived to have potential conflict of interest with this work. For full disclosure statements refer to <http://dx.doi.org/10.1016/j.artd.2015.11.002>.

^{*} Corresponding author. 7 Turner Street, Townsville, Queensland 4812, Australia. Tel.: +61747550564.

E-mail address: Research_Coordinator@oriql.com.au

<http://dx.doi.org/10.1016/j.artd.2015.11.002>

2352-3441/Copyright © 2016 The Authors. Published by Elsevier Inc. on behalf of American Association of Hip and Knee Surgeons. This is an open access article under the CC BY-NC-ND license (<http://creativecommons.org/licenses/by-nc-nd/4.0/>).

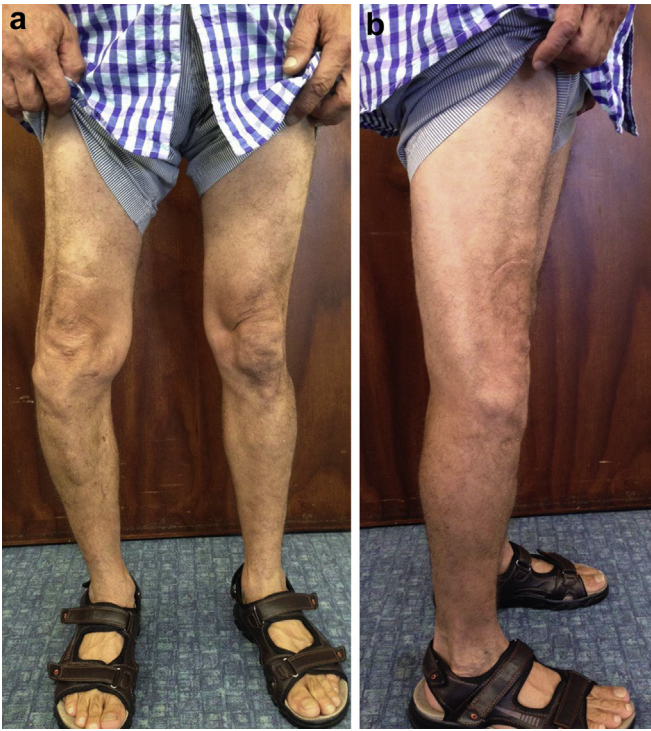

Figure 1. (a) A standing frontal plane photograph, taken preoperatively. (b) A standing lateral plane photograph taken preoperatively.

This article reviews the current literature and describes a surgical technique for single-stage extra-articular anterior femoral opening wedge corrective osteotomy, stabilized with a retrograde IM femoral nail. The subsequent anterior defect was bone grafted with TKA offcuts mixed with bone morphogenetic protein OP-1. This was followed by a computer navigation–assisted primary TKA as a single procedure.

Case history

The procedure was performed on a 53-year-old male. He had been involved in a motor bike accident 34 years prior, in which he sustained a closed distal femoral supracondylar A3-type fracture of the right femur. This fracture was managed in traction with subsequent recurvatum and varus malunion.

The patient was otherwise well, an ex-smoker with a body mass index of 23. He was in a full-time, manual-laboring occupation and experienced significant knee pain every day. He had previously undergone 2 knee arthroscopies by another surgeon with minimal improvement of symptoms.

Preoperative range of motion of the knee was 3° – 82° . His Hospital for Special Surgery (HSS) knee score preoperatively was 49 and his Western Ontario and McMaster Universities Arthritis Index (WOMAC) score was 51. Preoperative workup included routine preoperative blood tests for hemoglobin level, renal function, and liver function which were all within normal limits.

Anterior-posterior and lateral long-leg radiographs of both knees were obtained with the patient standing. A lateral radiograph

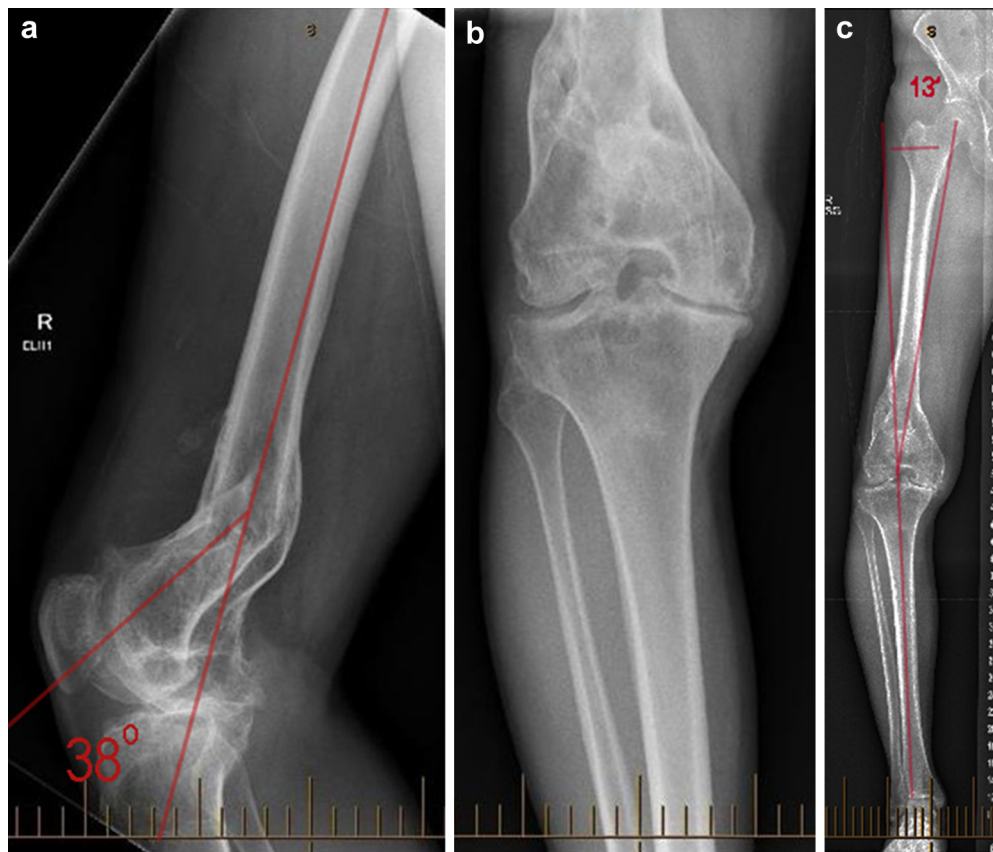


Figure 2. (a) A lateral radiograph of the right knee, demonstrating 38° of recurvatum, taken preoperatively. (b) An anterior-posterior radiograph of the right knee taken preoperatively. (c) A long-leg standing anterior-posterior radiograph taken preoperatively, demonstrating 13° varus alignment.

Table 1
Summary of published literature on correction of distal femoral deformity.

Author	n	Intervention	Preoperative deformity range	Follow-up (mo)	Postoperative outcome	Comments
Wang and Wang [8]	15	Conventional TKR	<ul style="list-style-type: none"> Coronal average valgus 15.1° Sagittal average 8.1° (up to 25°) 	38	<ul style="list-style-type: none"> Alignment average varus 0.3° ROM 103.7° KSS 91.7 	
Ritter et al. [9]	82	Conventional TKR	<ul style="list-style-type: none"> ≥20° of Valgus to ≥20° varus 	78	<ul style="list-style-type: none"> Alignment valgus 4.9° ± 3° KSS 87.8 ± 16.4 Survival 98.75%^a 	
Klein et al. [10]	5	Navigated TKR	<ul style="list-style-type: none"> Valgus 16.2° to varus 13.3° 	Not reported	<ul style="list-style-type: none"> Alignment average varus 1.1° Range varus 1.8° to valgus 0.4° 	<ul style="list-style-type: none"> PCL implants
Kubiak et al. [11]	111	Conventional TKR	<ul style="list-style-type: none"> ≥20° Valgus to varus 10° 	144	<ul style="list-style-type: none"> ROM 100° (70°–120°) KSS 92.2 (67–100) Survival 93%^a 	
Bottros et al. [12]	9	Navigated TKR	<ul style="list-style-type: none"> Average valgus 5° Range (valgus 2° to varus 14°) 	18.9	<ul style="list-style-type: none"> Alignment average valgus 1.3 ± 0.9° ROM 98° KSS 92 (83–97) 	
Lustig et al. [7]	28	Osteotomy only	<ul style="list-style-type: none"> Valgus 15° to varus 15° 	24	<ul style="list-style-type: none"> Alignment range valgus 1° to varus 8° KSS pain 34.2 KSS function 81.1 Survival 92.8%^a ROM 94° (60°–128°) 	<ul style="list-style-type: none"> Unicompartmental osteoarthritis Ahlbäck II-III
Deschamps et al. [13]	18	Conventional TKR + osteotomy	<ul style="list-style-type: none"> Valgus 21° to varus 24° 	48		<ul style="list-style-type: none"> 16 One-stage and 2 two-stage interventions Results mixed up with conventional TKR only
Kim et al. [14]	4	Minimally invasive navigated TKR	<ul style="list-style-type: none"> Average valgus 15.1° Maximum valgus 21.5° 	14	<ul style="list-style-type: none"> Alignment average varus 0.3° Average ROM 110° Range (105°–120°) KSS 95 	
Tigani et al. [15]	9	Navigated TKR	<ul style="list-style-type: none"> ≥10° of Valgus to ≥10° varus (maximum valgus 20° to varus 24°) Up to 15° recurvatum 	28	<ul style="list-style-type: none"> Alignment 0° ± 3° Average ROM 81° Range (65°–120°) KSS 72 	
Xiao-Gang et al. [16]	9	Conventional TKR ± osteotomy (n = 2)	<ul style="list-style-type: none"> Coronal 8°–22° Sagittal recurvatum 6°–15° 	29	<ul style="list-style-type: none"> Alignment 1° Average ROM 100.6° HSS 89.8 	
Rhee et al. [3]	13	Navigated TKR	<ul style="list-style-type: none"> Average 7.15° –13° to 25° 26° Antecurvatum to 18° recurvatum 	37	<ul style="list-style-type: none"> Alignment average 0.23° valgus Average ROM 118.46° Range (105°–135°) KSS 89.62 	
Liu et al. [17]	8	Navigated TKR	<ul style="list-style-type: none"> Average valgus 10.7° Range (valgus 13.2° to varus 8.4°) 	24	<ul style="list-style-type: none"> Alignment varus 1.2° Range (valgus 1.5° to varus 4.5°) ROM average 106.2° Range (95°–120°) KSS average 84 Range (77–94) 	
Marczak et al. [6]	35	Conventional TKR + preoperative computer planning	<ul style="list-style-type: none"> Average varus 21.4° to valgus 18.6° Range valgus 40° to varus 50° 	57	<ul style="list-style-type: none"> Alignment 4°–7° ROM average 90.1° Range (40°–120°) KSS average 80.5 Range (60–85) 	<ul style="list-style-type: none"> 5 Hinged implants

HSS, Hospital for Special Surgery Score; KSS, Knee Society Score; OA, osteo arthritis; PCL, posterior cruciate ligament; ROM, range of motion.

^a Survival percentage at the end of the follow-up period.

revealed the recurvatum deformity of the malunion site of the distal femoral fracture to be 38°. The long-leg anterior-posterior radiograph revealed a 13 varus deviation from the mechanical of the limb (Figs. 1 and 2; Table 1).

When recurvatum exceeds 15°, functional complaint is common because of stretching of the posterior capsule-ligamentous structures, leading to impairment of the extensor mechanism, weakness, and pain.

Informed consent for the procedure and publication was obtained and documented. A general anesthetic augmented with a spinal regional anesthetic was administered. Two grams of intravenous cefazolin antibiotic prophylaxis was given. One gram of intravenous tranexamic acid was given 10 minutes before skin incision. The patient was positioned supine with a lateral support placed against the right thigh, and a tourniquet was applied but not inflated. The entire right lower limb was prepped and isolation

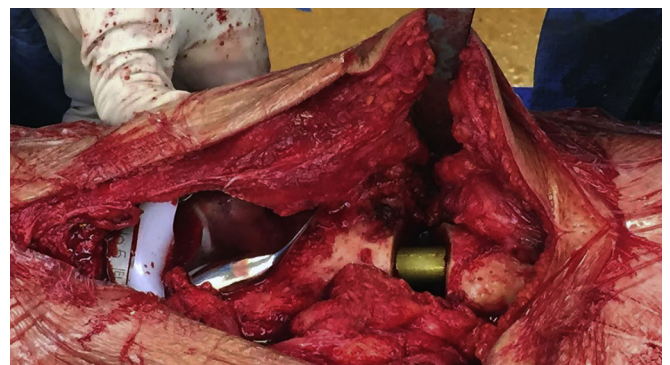


Figure 3. Intraoperative photograph of the osteotomy with the IM nail in situ.

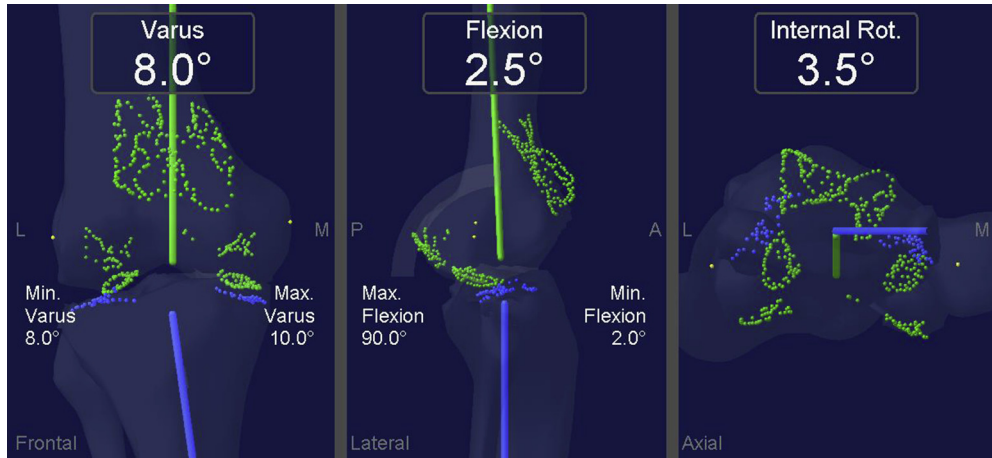


Figure 4. Stryker Precision navigation system native knee parameters before any bony resections.

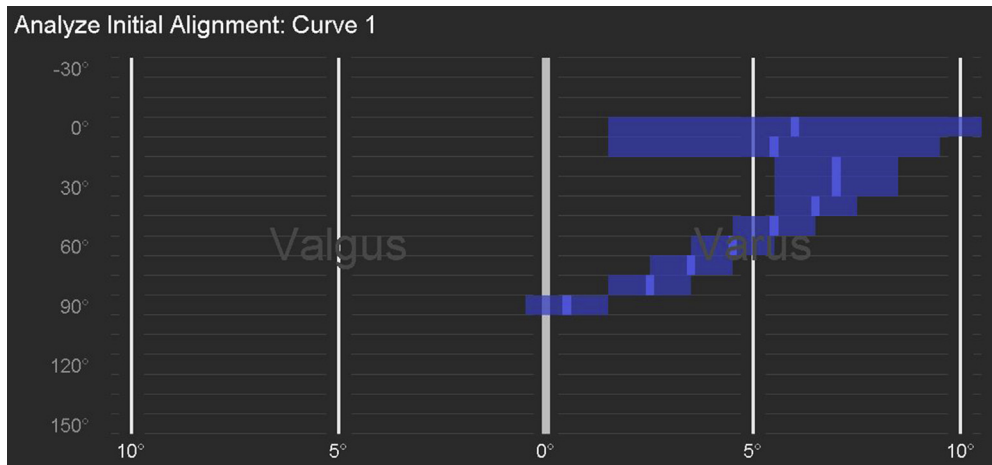


Figure 5. Stryker Precision navigation system recording the dynamic preoperative knee assessment graph.

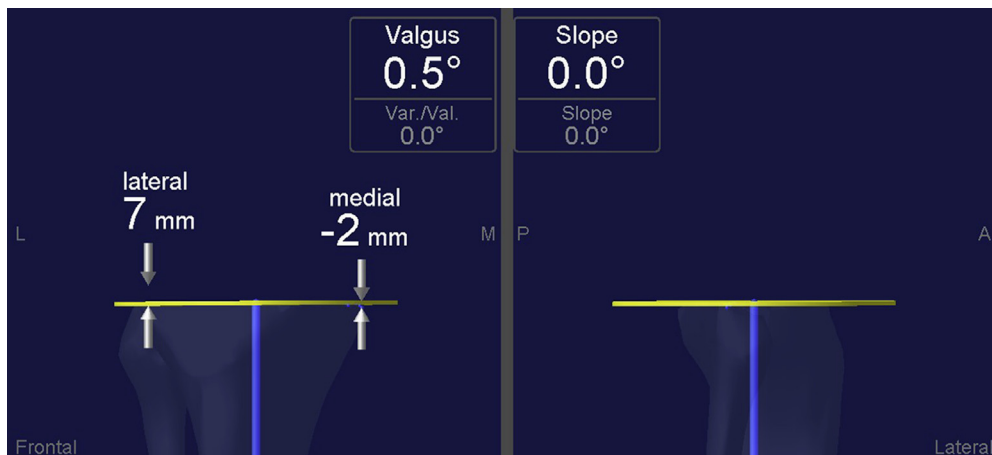

Figure 6. Stryker Precision navigation system navigation image of the resection level of the proximal tibia.

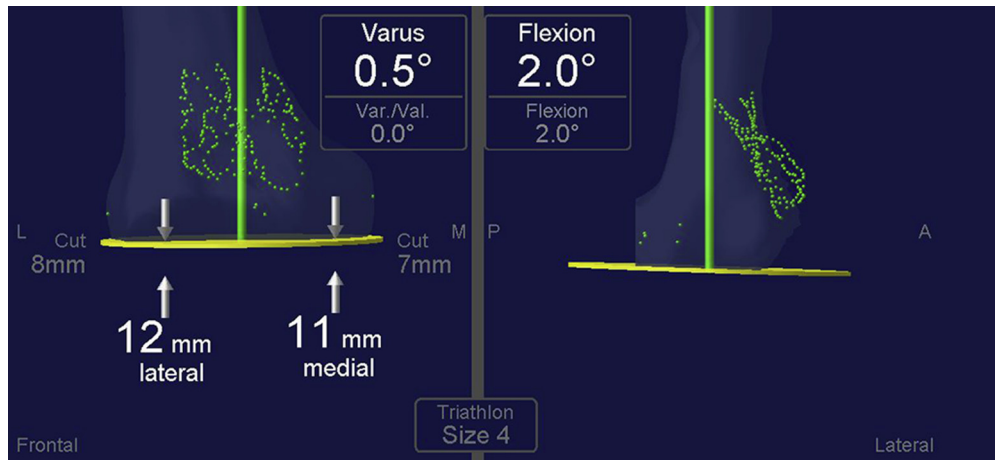


Figure 7. Stryker Precision navigation system recording the distal femoral resection.

draped. The right leg was secured in a Robb leg holder (Innomed, Savannah, GA).

A medial parapatellar approach was used and extended proximally to gain access to the distal femur malunion, 8 cm above the joint line. A Stryker Precision saw was used to perform a controlled osteotomy of the anterior cortex and cancellous bone of the femur at the center of the abnormality. The position of the osteotomy was identified under direct vision and confirmed via an image intensifier (Fig. 3).

The posterior cortical bone was left intact to improve stability and function as a hinge. The wedge was opened anteriorly using 2 laminar spreaders; adequate correction was confirmed with fluoroscopy. A retrograde Smith and Nephew Trigen femoral nail (Smith & Nephew, Inc., Cordova, TN) (11.5 mm × 320 mm) was then inserted under fluoroscopic control. Two distal locking screws and a single proximal locking screw were used to lock the nail in position.

Bicortical navigation pins were inserted into the medial flare of distal femur avoiding the IM Nail. The tibial pins were positioned as usual without any difficulty into the anteromedial subcutaneous border 20 cm distal to the joint. The knee parameters were registered using the Stryker Precision navigation system (Stryker Navigation, Kalamazoo, MI). The usual registration protocol was utilized without any difficulty.

The postosteotomy and prearthroplasty measurements indicated the knee was in 8° of varus and had a range of motion of +2°–90° (Fig. 4).

Initial examination of the dynamic tibiofemoral alignment revealed a varus curve pattern with a coronal plane laxity window ranging from 2°–10° of varus with valgus and varus stress, respectively. This reflected some increased lateral laxity which was predictable (Fig. 5).

The medial soft tissue structures were correctable to within 2° varus suggesting no medial-side contracture. The knee was 1° valgus to 1° varus at 90° of knee flexion. There was no coronal plane laxity or contracture in 90° of flexion.

The proximal tibia was cut to resect 7 mm of the lateral side with minimal resection from the medial proximal tibia aligning the cut in 0.5° valgus (Fig. 6).

The anterior cruciate ligament and meniscal remnants were resected, whereas the posterior cruciate ligament and popliteus tendon were preserved.

The aim of the distal femoral resection level was to take 3–4 mm more bone to prevent a postoperative fixed flexion deformity. The native joint line had been elevated because of recurvatum

deformity. Twelve millimeters was resected off the lateral condyle, and 11 mm was resected off the medial femoral condyle. This gave us a lateral extension gap of 21 mm and the medial extension gap was 20 mm. The knee was balanced in extension requiring no medial soft tissue release (Fig. 7).

The posterior condyles had 8 mm resected medially and 5 mm laterally. The femoral rotation was 2° external relative to the epicondylar axis.

The flexion gaps were recorded at 20 mm lateral and 19 mm medial (Figs. 8 and 9).

Patelloplasty was performed but it was not resurfaced.

The optimal position of the femoral component covered the entry point for the IM nail, which would necessitate its removal if the IM nail were to be later removed. Trial of a size 4 femur and size 5 tibia with a 11-mm polyethylene tray insert confirmed a balanced knee on both navigation and clinical assessment. The aforementioned components in the trialed sizes were subsequently cemented in place with a 11-mm condylar-stabilized fixed-bearing polyethylene tray.

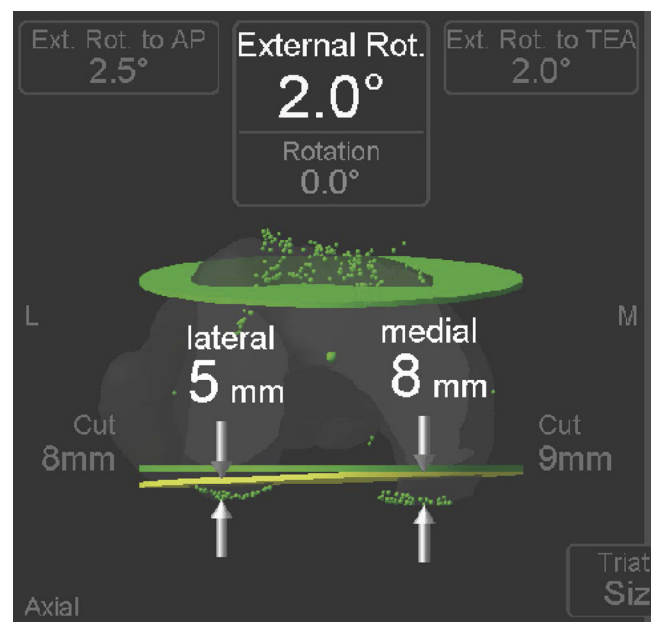


Figure 8. Stryker Precision navigation system recording the posterior condyle resection. AP, anterior posterior axis; TEA, trans epicondylar axis.

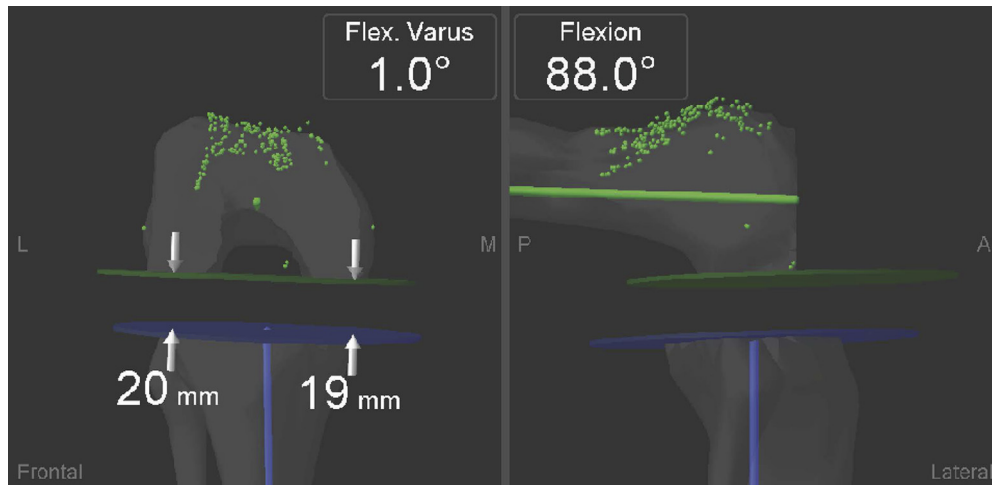


Figure 9. Stryker Precision navigation system recording the flexion gap balance.

The bone resected from the distal tibia and proximal femur was milled into small pieces, combined with OP-1 bone morphogenetic protein and packed into the distal femoral osteotomy wedge. Ropivacaine, ketorolac, and adrenalin were infiltrated as part of a local block, and the wounds were closed in layers using V-Loc sutures over a reinfusion drain.

Postarthroplasty computer-navigated measurements revealed limb alignment to be 3° varus, 5.5° of hyperextension with 6.5° of internal rotation.

Postarthroplasty dynamic assessment of the tibiofemoral alignment throughout the range of motion revealed normalization of the prearthroplasty varus knee deformity. In extension, the alignment was 3° of varus to a 2° valgus when placed in 90° of flexion [Figs. 10-12](#).

Postoperatively, the patient received 1 g of tranexamic acid at 6 hours and 8 mg of dexamethasone at 12 hours. The patient was allowed to weight bear as tolerated immediately. His recovery was uneventful and he discharged home on day 5, with the aid of a walking stick.

Patient results are presented in [Table 2](#) in the following.

At 6 weeks, the patient's postoperative range of motion was 0°–100°. The patient's WOMAC and HSS scores at 6 weeks postoperatively were 27 and 59, respectively ([Figs. 13 and 14](#)).

At the sixth month review, the range of motion was 0°–115°, and the WOMAC and HSS scores were 4 and 76, respectively ([Table 2](#)).

Postoperative sagittal plane alignment was 0° and 3° in the coronal plane after definitive implant ([Figs. 15-18](#)).

Discussion

Surgical treatment of knee osteoarthritis (OA) in the context of severe extra-articular deformity remains one of the most challenging management situations for orthopaedic surgeons. Such deformities are rare, mainly occurring secondary to fracture malunion and bony metabolic disease. High standards of orthopaedic treatment for traumatic and metabolic conditions have contributed to a declining incidence of severe deformity in recent decades. Nonetheless, it remains a potential management hurdle for any arthroplasty surgeon. A thorough review of the literature demonstrates that scant publication exists in this subject area. Two of the list authors BM and SBR conducted an independent literature review using Ovid, PubMed, and Medline, using the search headings TKA, extra-articular deformity, and their synonyms. Articles were included if they had described the intervention clearly, had preoperative and postoperative limb alignment values, functional outcome scores, and duration of follow-up. The article by Klein et al. [\[10\]](#) was included despite not have a duration of follow-up specified ([Table 1](#)).

Traditionally, most efforts toward correcting these deformities have focused on the use of total knee replacement (TKR). However,

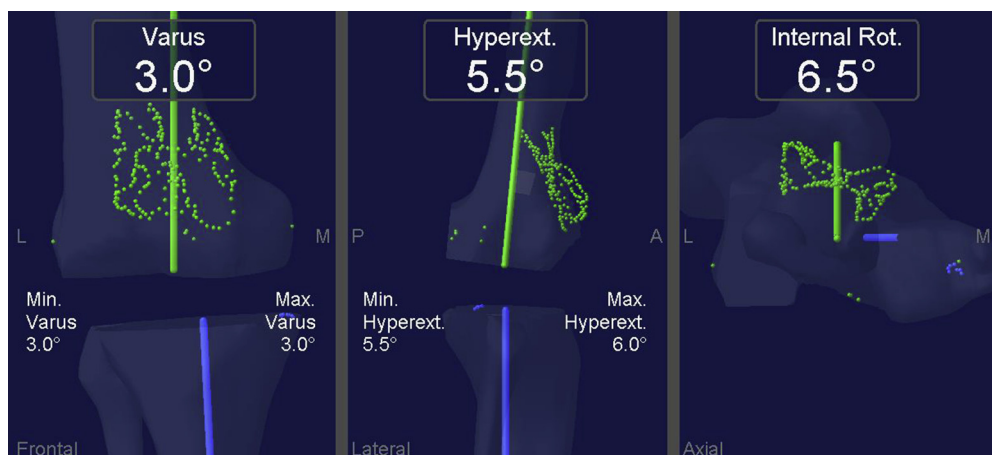


Figure 10. Stryker Precision navigation system confirming alignment with definitive implants.

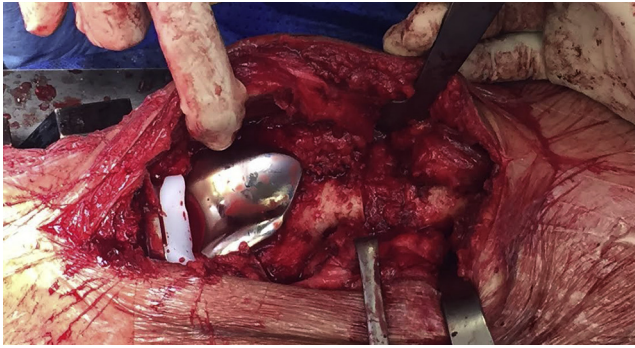


Figure 11. Intraoperative photograph after osteotomy, arthroplasty, and bone graft.

some authors have suggested alternative management techniques in specific circumstances. Lustig et al.'s [7] study of a multicenter series of 28 knees affected by early OA (Ahlbäck grades 2 and 3) and extra-articular deformity of up to 10° managed with isolated realignment osteotomy demonstrated good pain control and functional outcomes. Lustig et al.'s findings suggest that realignment osteotomy is a good alternative to TKR in young patients with moderate deformities and early stages of OA.

Several authors have proposed basic principles for the use of TKR in the correction of severe extra-articular deformity, and there has been some support for these methodologies in the literature. Wolf et al. [4] suggested that the addition of extra-articular osteotomy would aid in achieving appropriate limb alignment in gross femoral or tibial angular deformities, thus allowing routine TKR to be performed without compromise to the intrinsic joint stability provided by the collateral ligaments. Further exploration of the literature demonstrates consensus support for the preservation of the collaterals. It has been further proposed by Wang and Wang [8] that intra-articular correction of deformities should be limited to those of <20° on the femoral side and <30° on the tibial side in the coronal plane. Beyond these limits, Wang and Wang advocates for the addition of extra-articular corrective osteotomy.

Less has been written about deformities in planes other than sagittal. Xiao-Gang et al. [16] reported an example of a successful TKR using intra-articular resection only in a case of 15° retrocurvatum. Liu et al. [17] were able to address a 30° femoral ante-curvatum deformity in the same fashion. In regard to rotational malalignment, Deschamps et al. [13] stated that external rotation of

up to 10° and internal rotation of up to 20° can be addressed without extra-articular adjustment, with no compromise to functional outcomes.

Isolated conventional instrumented TKR have had a role in the management of patients with severe deformity. Ritter et al. [9] published a series of 82 TKRs in patients with at least 20° of joint line deviation. Kubiak et al. [11] reported 111 posterior cruciate ligament retained prostheses in patients with at least 15° of deviation from the mechanical axis, with a 10-year survival rate of 93%.

More recently, the routine use of navigation has become a valuable tool in approaching TKR in patients with severe alignment deformity. Klein et al. [10] first reported successful use of navigation in a knee with a deformity of 16° valgus and 12° recurvatum; no additional osteotomy was used. Subsequent series have demonstrated the feasibility of correcting gross deformities with navigated TKR and without the need for extra-articular osteotomy. Tigani et al. [15] demonstrated correction of up to 24° of valgus, whereas Rhee et al. [3] obtained good results in patients with severe deformities such as 26° of ante-curvatum in addition to 10° of valgus. Kim et al. [14] reported a series of 4 navigated TKRs performed through a minimally invasive approach, in patients with an average deformity of 15° varus (up to 21°), with good alignment and functional outcomes.

Marczak et al. [6] performed 33 TKRs in patients with deformities as severe as 50° of varus and 40° of valgus without the requirement for extra-articular osteotomy, aided by preoperative computer-assisted surgical planning. Despite achieving poor post-operative ROM in this series, pain relief and functional scores were good.

The use of additional osteotomies to achieve correct alignment of TKR in severely deviated limbs has been scarcely documented. The largest series found by the author was published by Deschamps et al., [13] which includes 16 single-stage TKRs with associated corrective osteotomy. This approach has been presented as an alternative in the surgical management of cases of severe malalignment. However, within this series, 2 patients demonstrated nonunion of the osteotomy and the average functional outcome scores were lower than those of the control group, managed with isolated intra-articular balancing. The reported higher incidence of complications is generally noted to be the predominant disadvantage of performing TKR in association with extra-articular osteotomy. Further limitations include the greater technical demand of such procedures.

To our knowledge, our case demonstrates the first published case of a TKR prostheses being implanted under navigation

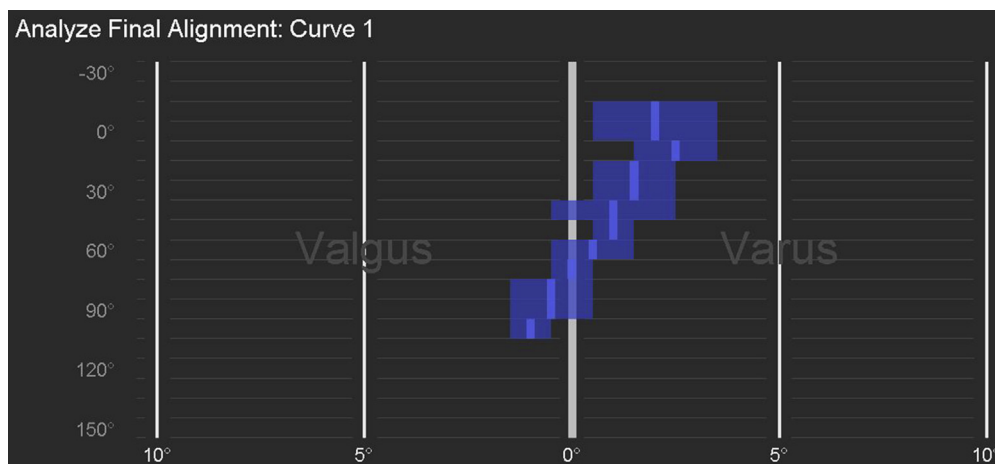


Figure 12. Final alignment curve - post osteotomy and post arthroplasty.

Table 2
Functional scores and range of motion.

Assessment timepoint	WOMAC	HSS	Flexion
Preoperative	51	49	3°–82°
6 Weeks	27	59	0°–100°
6 Months	4	76	0°–115°

assistance with the addition of extra-articular osteotomy, performed in a single-stage procedure.

It was the opinion of the authors that physiological alignment at the level of the joint line could not be achieved without osteotomy in this case because of the severity of the patient's biplanar deformity at the malunion site. Although the coronal deformity could have been managed easily with intra-articular resection, the remarkable recurvatum could not. The accurate and precise information provided by the navigation system allowed for optimal implant placement. Results at midterm follow-up have revealed good radiological, functional, and ROM outcomes, comparable to those of uncomplicated primary TKRs. We are aware of the limitations of a single case report in proving the benefits of a novel surgical technique. However, experience with the present case is encouraging and has prompted consideration of the use of this combination technique in the management of similar future presentations. Positive results of larger series are required before it is appropriate to suggest the use of this technique more universally. We anticipate that this could only be achieved through multicenter collaboration.

The patient underwent temporizing procedures in the form of knee arthroscopy in the past which predictably did not yield a satisfactory outcome. Although the patient was in his 50s, he was

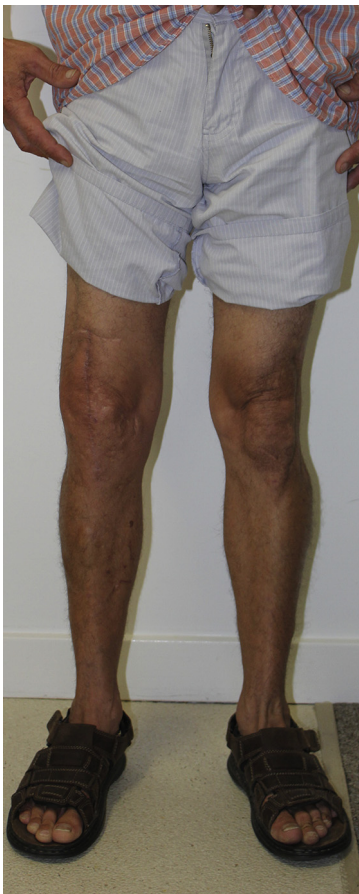

Figure 13. Photograph taken in frontal plane at 6 months postoperatively.

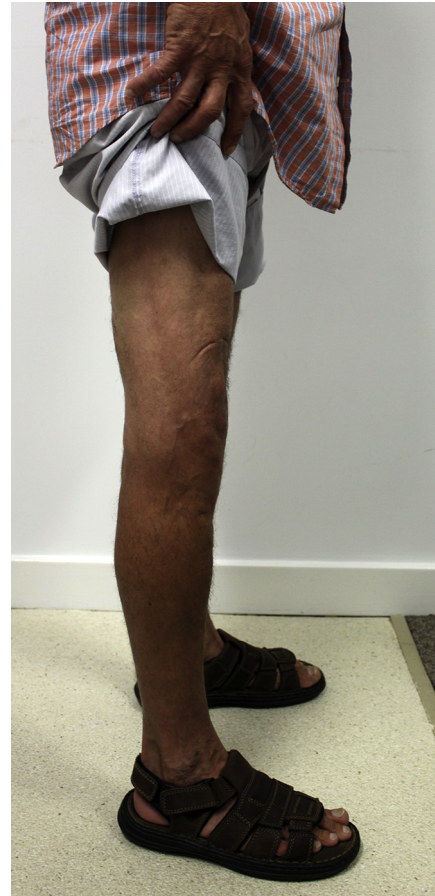

Figure 14. Photograph taken in the sagittal plane at 6 months postoperatively.

severely incapacitated owing to pain, unable to carry out activities of daily living and earn a living. The only procedure that would give him a satisfactory midterm-to-long-term outcome was a TKA.

When planning a TKA in this setting, it is important to acknowledge the presence of the extra-articular deformity. If the extra-articular deformity is $>10^\circ$ in the coronal plane or exceeding 20° in the sagittal plane, then it is inappropriate to rely on standard intra-articular bone resection and soft-tissue balancing to perform a primary knee replacement [18]. Wolff et al. [4] reported that 2 primary factors determine whether intra-articular or extra-articular correction is indicated. They are the degree of the deformity and the distance the deformity is from the joint line. The maximum limits generally accepted for intra-articular correction are 20° in the coronal plane and 25° in the sagittal plane.

The patient's deformity was outside the acceptable range that could be corrected with intra-articular bone resection. An extra-articular distal femoral osteotomy was required to align the femur to balance the soft tissue envelope without extensive releases.

A previous report by Wang and Wang [8] successfully corrected deformity in 7 cases with deformities ranging up to 25° in the sagittal plane using intra-articular resection only.

The patient in this case report had almost 40° of recurvatum, and an attempt at intra-articular correction is considered not viable. The femoral component would have been required to be flexed to a degree which would potentially have caused posterior notching and overstuffing to the patellofemoral joint. The anterior flange of the femoral component would not allow smooth tracking of the patella. If the femoral component were to be positioned with reference to the distal malaligned segment, then this could

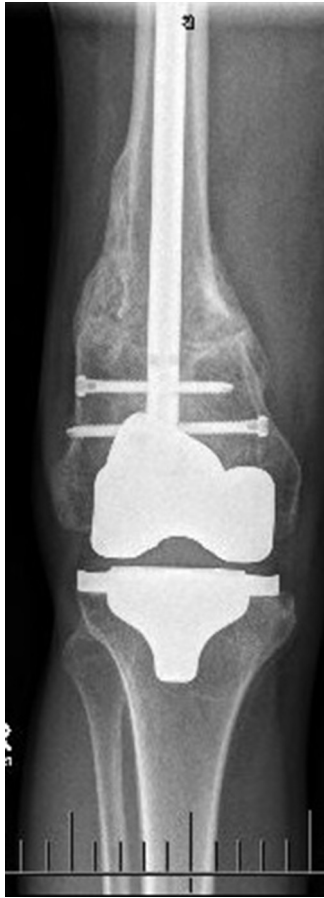

Figure 15. Anteroposterior knee radiograph taken at 6 months postoperatively.

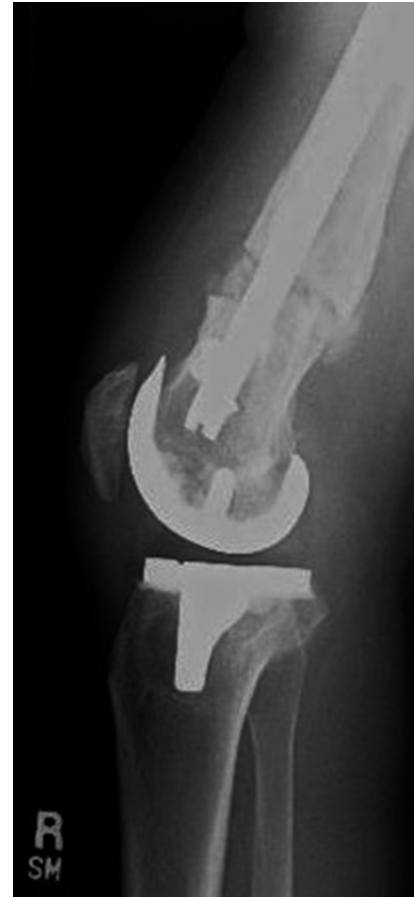

Figure 16. Lateral knee radiograph taken at 6 weeks postoperatively.

potentially restrict the flexion range. Collectively, the change in the biomechanical function of the posterior cruciate, extensor mechanism, hamstrings, and gastrocnemius and soleus complex could not be reliably predicted with TKA alone.

Computer-navigated knee replacement provides the surgeon with a valuable real-time verification of the planned and realized bone resections. In Australia in 2013, 23.8% of all primary knee replacements used computer navigation systems. National registry data indicate that there is a promising trend toward a decreased revision rate for loosening and/or lysis in younger patients when the primary operation uses computer navigation [19].

Computer navigation significantly increases the precision of the bone cuts and improves the assessment of limb alignment in the setting of a primary knee arthroplasty and extends to include complicated malunion. Computer navigation eliminates the requirement for IM or extramedullary alignment guides, where the former would have been difficult to pass through the IM canal after a previous fracture. Furthermore, unnecessary instrumentation of the IM canal increases the risk of fat embolism.

Review of literature preoperatively revealed only a small number of case reports using computer navigation knee replacement in association with corrective osteotomy. These case reports used either an IM nail with a proximal third osteotomy of the femur [20] or a distal femoral locking plate and distal osteotomy. A long-stemmed prosthesis was an option; however, previous case reports of single-stage femoral osteotomy and knee replacement with long-stemmed femoral prosthesis have resulted in nonunion [18].

In this case, IM nailing provides the required stability and allowed for micromotion at the fracture site to facilitate bony

union. The biology of the osteotomy healing was further augmented with the use of bone graft and OP-1.

The ability to precisely control the femoral osteotomy and limit bone cuts to the cancellous and anterior cortex is of high importance. The Stryker Precision saw was used to produce a well-controlled, opening wedge osteotomy, and this contributed to the stability by leaving the posterior cortex intact. This subsequently enabled the femur to be stabilized by an IM nail and hinged posteriorly.

In a similar case report by Kuo et al., [21] in which their patient had a severe distal femoral malunion, computer navigation was used to plan the bony resection for the TKR. They did not perform an osteotomy to correct the deformity, instead relying on intra-articular resection, and postoperatively, their patient achieved good knee range of motion of 0°–120°.

In our case, we were able to stabilize the osteotomy independent of the knee replacement. We were able to use an IM nail as opposed to a revision-type constrained knee prosthesis with stems, both avoiding potential nonunion at the osteotomy site and avoiding the additional distal femoral bone resection required to position a long stem. Our technique negated a second operation, and the patient commenced rehabilitation the following day with full weight bearing.

Current controversies and future considerations

After review, it is clear that controversy exists when considering distal femoral deformity in TKA. Osteotomy alone may be sufficient in some cases; the question which should be asked is “does the

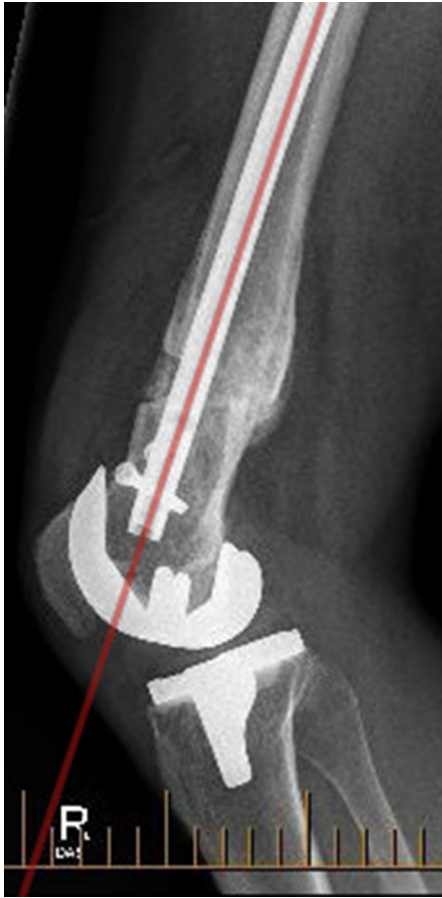

Figure 17. Lateral knee radiograph taken at 6 months postoperatively, with evidence of osteotomy union.

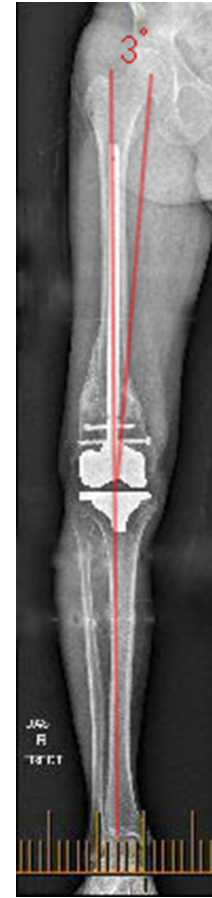

Figure 18. Anterior-posterior long-leg radiograph taken at 6 months postoperatively.

patient require a TKR or will a less-extensive procedure such as corrective osteotomy alone provide good outcomes?" We suggest, as indicated by Lustig et al.'s[7] study, that mild-to-moderate osteoarthritis (Ahlbäck grade, 2-3) can potentially be managed by osteotomy alone, especially in a younger patient.

Another controversial topic is whether to perform an osteotomy and knee arthroplasty as a single-stage or as a 2-stage procedure. Careful consideration of the extent of osteoarthritis is also relevant here. A patient with only mild-to-moderate osteoarthritis may have good pain relief and function after osteotomy alone; thus, selecting a 2-stage operation may eliminate the requirement for a second procedure. Severe osteoarthritis is likely to cause ongoing pain and loss of function even after osteotomy; the single-stage procedure will negate a second anesthetic and surgery proving an attractive option. Ultimately the decision should be made based on the case at hand in consultation with the patient pertaining to the risk versus benefit of each approach.

Also, controversial is the method of fixation when extra-articular correction and osteotomy are performed. In the literature, numerous methods are described, varying from distal femoral plate, IM nail, and long-stemmed prosthesis. Lateral femoral plate requires a large incision and disruption of the soft tissue envelope. It is also associated with a high rate of nonunion resulting in implant removal. IM nail requires instrumenting the IM canal and risks fat embolism; in addition, if the nail requires extraction in revision surgery, the femoral component must also be removed. Long-stemmed prosthesis is associated with greater distal femoral bone loss and additionally requires the removal of the femoral

prosthesis in the event of nonunion. Furthermore, long-stemmed prostheses are often more constrained reducing the life span of the implant.

Looking forward, it is likely that evidence will continue to be drawn from case series analyzed by meta-analysis owing to the infrequent nature of this condition. We anticipate that computer navigation and potentially patient-specific instrumentation will continue to add guidance for the surgeon intraoperatively. Modern femoral fracture management continues to reduce the incidence of malunion; ultimately, this will make this presentation more infrequent in the future.

Summary

Distal femoral deformity with knee osteoarthritis remains a challenging problem. In the literature, multiple methods are described, observing similar principles of management, most with reasonable outcomes.

When considering single-stage, opening wedge osteotomy with IM nail and computer-navigated arthroplasty, our technique had 3 major benefits. First, single-stage surgery enabled more rapid rehabilitation and eliminated the risk associated with a second procedure. Second, the use of a more physiological osteotomy fixation along with a minimally constrained knee prosthesis resulted in minimal distal femoral resection and bone loss. Finally, computer navigation allowed us to greater define the intra-articular resection and balance the knee without major soft tissue release.

KEY POINTS

Effective management requires the following:

- Careful consideration of the extent of osteoarthritis to determine if arthroplasty is indeed warranted after osteotomy.
- Preoperative planning to determine whether intra-articular correction will violate the collateral ligaments, necessitating the need for extra-articular correction. In sagittal plane deformity, osteotomy may be required if it is $>25^\circ$.
- Fixation method to be selected with consideration of soft tissues around the knee, the degree of femoral bone resection, component constraint required, and future management of potential complications.

Acknowledgments

The authors thank A. Grant, P. McEwen, and L. Murphy for article preparation assistance.

Appendix A. Supplementary data

Supplementary data related to this article can be found at <http://dx.doi.org/10.1016/j.artd.2015.11.002>.

References

1. Enninghorst N, McDougall D, Evans JA, Sisak K, Balogh ZJ. Population-based epidemiology of femur shaft fractures. *J Trauma Acute Care Surg* 2013;74(6):1516.
2. Ehlinger M, Ducrot G, Adam P, Bonnomet F. Distal femur fractures. Surgical techniques and a review of the literature. *Orthop Traumatol Surg Res* 2013;99(3):353.
3. Rhee SJ, Seo CH, Suh JT. Navigation-assisted total knee arthroplasty for patients with extra-articular deformity. *Knee Surg Relat Res* 2013;25(4):194.
4. Wolff AM, Hungerford DS, Pepe CL. The effect of extraarticular varus and valgus deformity on total knee arthroplasty. *Clin Orthop Relat Res* 1991;(271):35.
5. Bansi P, Tetsworth K. Total-knee replacement for the management of peri-articular knee fractures in the elderly. *Curr Opin Orthop* 2006;17(1):51.
6. Marczak D, Synder M, Sibiński M, Okoń T, Kowalczewski J. One-stage total knee arthroplasty with pre-existing fracture deformity. Post-fracture total knee arthroplasty. *J Arthroplasty* 2014;29:2104.
7. Lustig S, Khiami F, Boyer P, et al. Post-traumatic knee osteoarthritis treated by osteotomy only. *Orthop Traumatol Surg Res* 2010;96(8):856.
8. Wang JW, Wang CJ. Total knee arthroplasty for arthritis of the knee with extra-articular deformity. *J Bone Joint Surg Am* 2002;84-A(10):1769.
9. Ritter MA, Faris GW, Faris PM, Davis KE. Total knee arthroplasty in patients with angular varus or valgus deformities of $>$ or $=$ 20 degrees. *J Arthroplasty* 2004;19(7):862.
10. Klein GR, Austin MS, Smith EB, Hozack WJ. Total knee arthroplasty using computer-assisted navigation in patients with deformities of the femur and tibia. *J Arthroplasty* 2006;21(2):284.
11. Kubiak P, Archibeck MJ, White RE. Cruciate-retaining total knee arthroplasty in patients with at least fifteen degrees of coronal plane deformity. *J Arthroplasty* 2008;23(3):366.
12. Bottros J, Klika AK, Lee HH, Polousky J, Barsoum WK. The Use of Navigation in Total Knee Arthroplasty for Patients With Extra-Articular Deformity. *J Arthroplasty* 2008;23(1):74.
13. Deschamps G, Khiami F, Catonné Y, et al. Total knee arthroplasty for osteoarthritis secondary to extra-articular malunions. *Orthop Traumatol Surg Res* 2010;96(8):849.
14. Kim KI, Ramteke AA, Bae DK. Navigation-assisted minimal invasive total knee arthroplasty in patients with extra-articular femoral deformity. *J Arthroplasty* 2010;25(4):658.e17.
15. Tigani D, Masetti G, Sabbioni G, et al. Computer-assisted surgery as indication of choice: total knee arthroplasty in case of retained hardware or extra-articular deformity. *Int Orthop* 2012;36(7):1379.
16. Xiao-Gang Z, Shahzad K, Li C. One-stage total knee arthroplasty for patients with osteoarthritis of the knee and extra-articular deformity. *Int Orthop* 2012;36(12):2457.
17. Liu Z, Pan X, Zhang X. Total knee arthroplasty using navigation system for severe osteoarthritis with extra-articular deformity. *Eur J Orthop Surg Traumatol* 2011;23(1):93.
18. Lonner JH, Siliski JM, Lotke PA. Simultaneous femoral osteotomy and total knee arthroplasty for treatment of osteoarthritis associated with severe extra-articular deformity. *J Bone Joint Surg Am* 2000;82(3):342. <http://www.ncbi.nlm.nih.gov/pubmed/10724226> [accessed 29.07.15].
19. Graves S. Hip and knee arthroplasty annual report 2014. Adelaide, Australia: Australian Orthopaedic Association; 2014.
20. Fan CHJ. Case Report One-stage femoral osteotomy and computer-assisted navigation total knee arthroplasty for osteoarthritis in a patient with femoral subtrochanteric fracture malunion. *Case Reports Orthop Hindawi Publ Corp.* 2014;2014(Article ID 645927):4. <http://dx.doi.org/10.1155/2014/645927>.
21. Kuo CC, Bosque J, Meehan JP, Jamali AA. Computer-assisted navigation of total knee arthroplasty for osteoarthritis in a patient with severe posttraumatic femoral deformity. *J Arthroplasty* 2011;26(6):976.e17.