



# A Case of *Ancylostoma ceylanicum* Infection Occurring in an Australian Soldier Returned from Solomon Islands

Rick Speare<sup>1,2</sup>, Richard Stewart Bradbury<sup>3,\*</sup>, John Croese<sup>4</sup>

<sup>1</sup>College of Public Health, Veterinary and Medical Sciences, James Cook University, Townsville, Australia; <sup>2</sup>Tropical Health Solutions Pty Ltd, Topaz, Australia; <sup>3</sup>School of Medical and Applied Sciences, Central Queensland University, North Rockhampton, Australia; <sup>4</sup>Department of Gastroenterology and Hepatology, The Prince Charles Hospital, Brisbane, Australia

**Abstract:** A 26-year-old male member of the Australian Defense Force presented with a history of central abdominal pain of 4 weeks duration and peripheral eosinophilia consistent with eosinophilic enteritis. Acute hookworm disease was diagnosed as the cause. Adult worms recovered from feces after therapy with albendazole were morphologically consistent with *Ancylostoma ceylanicum*. As the patient had been deployed with the Regional Assistance Mission to Solomon Islands for 6 months prior to this presentation, it is very likely that the *A. ceylanicum* was acquired in Solomon Islands. Until now, it has been assumed that any *Ancylostoma* spp. recovered from humans in Solomon Islands is *A. duodenale*. However, this case demonstrates that human hookworm infection acquired in the Solomon Islands could be caused by *A. ceylanicum*.

**Key words:** *Ancylostoma ceylanicum*, hookworm, Solomon Islands, eosinophilic enteritis

## INTRODUCTION

Humans are infected naturally by 3 species of hookworms; *Necator americanus*, *Ancylostoma duodenale*, and *Ancylostoma ceylanicum* [1]. Individual people can be infected with 1 species, 2 species, or all 3 species of hookworms [1-5]. Although *A. ceylanicum* is often considered to be a zoonotic pathogen, since it is also found in dogs and cats, its importance as a significant soil-transmitted helminth of humans is increasingly being recognized [1]. Two haplotypes of *A. ceylanicum* have been identified; one largely found in humans and another that infects humans, dogs, and cats [5,6].

*A. ceylanicum* is considered to be of emerging importance as a helminth of humans in the Asia Pacific region [1]. A fourth hookworm also reported from humans, *Ancylostoma caninum* represents a canine species with zoonotic potential. This species has mainly been recorded as causing eosinophilic enteritis in people in tropical Australia, but never establishes a patent infection and hence humans are regarded as accidental hosts [7].

Human hookworm is common in the Solomon Islands, with an estimated 192,000 people (36% of the population) infected [8], but the different species involved are yet to be determined [9-11]. The report to the Rockefeller hookworm campaign in 1928 described only *N. americanus* as being present on these islands [12]. The only previous report of *A. ceylanicum* from the Solomon Islands was a 5-year-old boy who imported the species in 1938 from the Shortland Island group of the Solomon Islands to Australia [13].

The Solomon Islands is a small Pacific nation to the North East of Australia, with a predominantly Melanesian population. The Regional Assistance Mission to Solomon Islands (RAMSI) occurred between 2003 and 2013, at the request of the Solomon Island's government, to assist in stabilizing internal troubles occurring within the nation. RAMSI consisted of 2,200 police and soldiers from many Pacific Island nations and was led by Australia. This case report describes the finding of *A. ceylanicum* in an Australian soldier who developed symptomatic disease after returning from a deployment in Solomon Islands with RAMSI.

•Received 15 May 2016, revised 17 June 2016, accepted 20 June 2016.

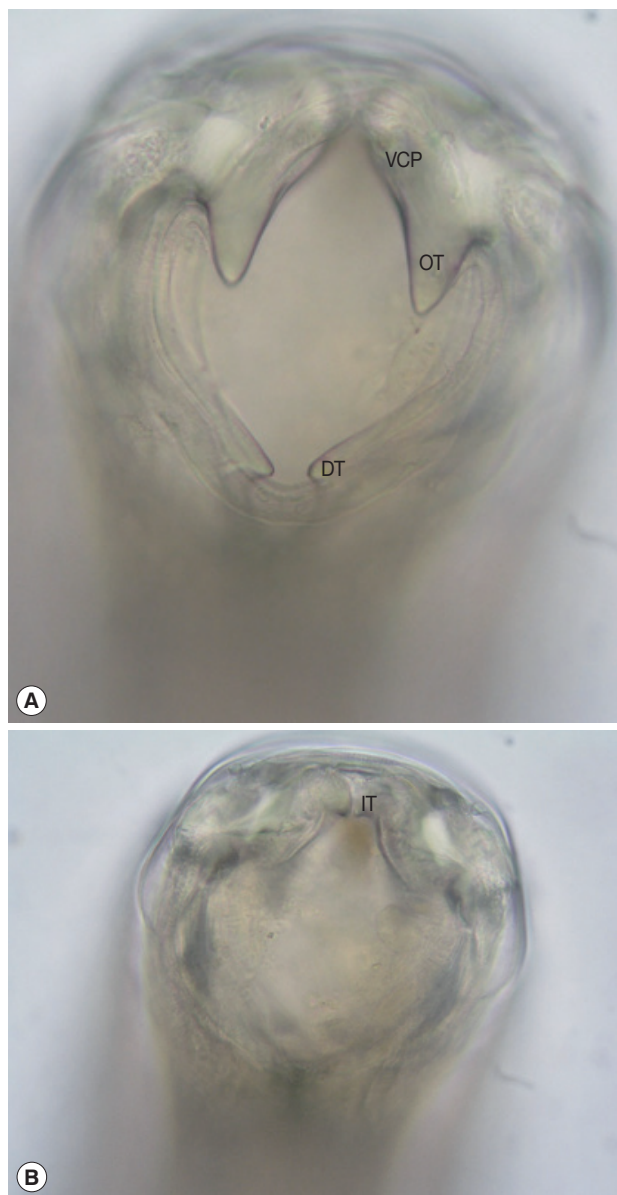
\*Corresponding author (r.bradbury@cqu.edu.au)

© 2016, Korean Society for Parasitology and Tropical Medicine

This is an Open Access article distributed under the terms of the Creative Commons Attribution Non-Commercial License (<http://creativecommons.org/licenses/by-nc/4.0>) which permits unrestricted non-commercial use, distribution, and reproduction in any medium, provided the original work is properly cited.

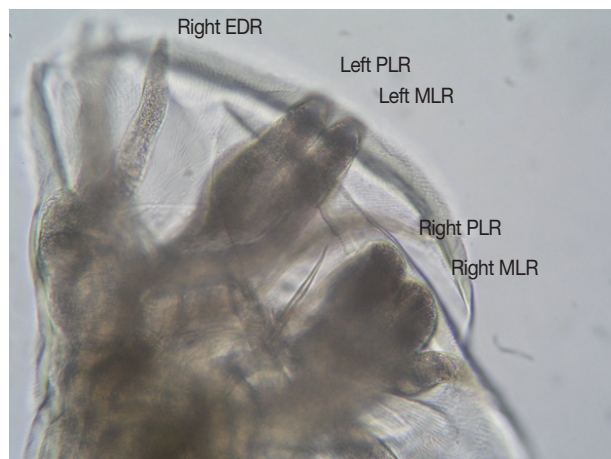
## CASE RECORD

The patient was a 26-year-old male living in Townsville, north Queensland, Australia who presented in March 2004



**Fig. 1.** En face view of the mouth part of an adult female *Ancylostoma ceylanicum* recovered from feces. (A) Robust ventral cutting plate with prominent outer tooth. (B) Optical section through a more posterior plane to show the smaller inner tooth on cutting plate. VCP, ventral cutting plate; OT, outer tooth; DT, dorsal tooth; IT, inner tooth.  $\times 400$  magnification.

with central poorly defined abdominal pain of 4 weeks duration and increased frequency of defecation. A peripheral eosinophilia had been noted on blood tests in February prior to symptom development, and in March, when eosinophils were  $6.20 \times 10^9/L$  whilst red blood cell indices were normal (hemoglobin 146 g/L, MCV 93 fL, hematocrit 0.44, red cell count  $4.7 \times 10^{12}/L$ ). The patient had served with RAMSI in the Solo-



**Fig. 2.** Lateral view of the bursa of an adult male *Ancylostoma ceylanicum*. Note the parallel mediolateral and posteriolateral rays. EDR, externodorsal ray; MLR, mediolateral ray; PLR, posteriolateral ray.  $\times 400$  magnification.

mon Islands from late July to early December 2003. His duties involved travel to various remote areas and provided multiple opportunities to become infected with hookworms. Routine treatment with albendazole had been given by the Australian Defense Force on return to Townsville in December, 2 months prior to development of symptoms. Initially, in March 2004 no parasite eggs were detected in feces by formalin-ethyl acetate concentration, but infective larvae of hookworms were found on Harada-Mori culture. Subsequently, typical thin-shelled hookworm eggs were detected on direct fecal smears. Infective larvae were sheathed, had inconspicuous buccal spears, the intestine was narrower than the esophageal bulb, and inconspicuous transverse striations were noted on the sheath in the tail region. The infective larvae, measured after preservation in hot formalin, had the following dimensions, mean  $\pm$  SD (range): length  $657.1 \pm 9.6 \mu m$  (633-669  $\mu m$ ), width  $21.4 \pm 0.9 \mu m$  (20.2-22.2  $\mu m$ ), esophagus  $156.7 \pm 3.5 \mu m$  (151-162  $\mu m$ ), tail  $77.9 \pm 3.8 \mu m$  (69-81  $\mu m$ ), length of sheath  $763.7 \pm 8.6 \mu m$  (779-746  $\mu m$ ); esophagus/length  $23.8 \pm 0.5\%$ , and tail/length  $11.9 \pm 0.6\%$ .

Due to the failure of single dose post-deployment albendazole therapy to eradicate this infection, the patient was treated with 100 mg of mebendazole twice daily for 3 days. Twelve adult hookworms (6 females and 6 males) were recovered by dissection of stools passed during the 48 hr immediately following treatment. The en face view revealed a robust ventral cutting plate bilaterally with a prominent point on the dorsal end and less obvious point on the ventral end (Fig. 1). The

width of the bursa in lateral view was greater than its length, and the mediolateral and posteriolateral bursal rays were parallel (Fig. 2). The patient responded well to the treatment and became asymptomatic.

## DISCUSSION

The morphology of the adult hookworms was consistent with *A. ceylanicum* with key features being: the large ventral cutting plates terminating at the dorsal end in a large single tooth; and in the male the parallel mediolateral and posteriolateral bursal rays [14]. Although the morphology and dimensions of the infective larvae are more consistent with *A. ceylanicum* than *N. americanus* [15], differentiating them from infective larvae of *A. duodenale* is unreliable. Although molecular taxonomy is valuable in identifying hookworm species [16], it was not available in this case and, as the specimen was subsequently accidentally disposed of, molecular taxonomic studies cannot be performed now. However, the morphological features were sufficient to identify this species as *A. ceylanicum*. This represents only the second report of human *A. ceylanicum* infection having been acquired in this nation, with the first being made almost 80 years ago [13]. This finding not only expands the known range of human *A. ceylanicum* infection but also raises the question of whether *A. ceylanicum* is in fact a common cause of human hookworm infection in some regions of the Solomon Islands, as it has recently been described as being in many parts of Asia [1]. The only previous reported description of hookworm species in the country was almost 80 years ago and was anecdotal, not providing descriptions of number of people tested or how the species identifications were arrived at [12].

*A. ceylanicum* infection has recently been reported from two people in Western Australia [17]. Prior to this, *A. ceylanicum* had been reported from dogs and cats in northern Australia, including those from Townsville [18,19]. Hence, the infection could have been acquired in north Queensland or while deployed with RAMSI. The likelihood of infection with *Ancylostoma* from humans in the Solomon Islands is high, but negligible in north Queensland since human feces are disposed of safely. However, since *A. ceylanicum* is present in dogs and cats in north Queensland, there is a possibility of a zoonotic Australian source even though this infection has not been seen in humans in this region. Many RAMSI personnel were infected with hookworms during their mission to the Solomon Islands,

and an isolated case of *A. ceylanicum* infection had been reported from this area early in the 20th century. This adds to the likelihood that the case presented here was acquired in the Solomon Islands and not elsewhere [20,21].

The clinical symptoms displayed by our patient were consistent with the phase of hookworm infection during which the host attempts to eliminate the parasite using an allergic response, manifesting morphologically as eosinophilic enteritis [22]. For *N. americanus* this response begins about 10 days after infection and persists for up to a month [22]. *A. caninum* and *A. duodenale* have a more complicated life cycle in which some infective larvae can enter a state of hypobiosis (arrested development) and can orchestrate entry to the intestine to coincide with the wet season and physiological events [23-26]. Whether *A. ceylanicum* has this capacity is unknown. The failure of a routine post-deployment albendazole treatment to eliminate the infection in our patient supports a hypothesis that the current infection was due to hypobiotic larvae activated after the anthelmintic was given. The north Queensland wet season commences in late December. Acute enteritis has been described previously in soldiers with *A. ceylanicum* acquired in West Papua (formerly Dutch New Guinea) [3] and in a traveller returning from Myanmar to France [16]. Treatment with albendazole in the latter patient cleared the gut infection but symptoms and parasites recurred after 3 months adding evidence for hypobiosis in *A. ceylanicum*. Our patient was treated after diagnosis with mebendazole due to its far greater tissue penetration and therefore greater capacity to kill hypobiotic larvae in the tissue.

The key points from this case report are: *A. ceylanicum* should be considered as a cause of acute eosinophilic enteritis in returned travellers, workers, or defense force personnel who have lived or visited tropical and subtropical countries; laboratory confirmation may require persistence to make the diagnosis of hookworms and will require special tests (morphology of adults after treatment; molecular taxonomy on stools or infective larvae) to identify the species; and human infection with *A. ceylanicum* is probably endemic in the Solomon Islands and further study of the prevalence of different hookworm species present in this country is warranted.

## CONFLICT OF INTEREST

We have no conflict of interest related to this work.

## DEDICATION

This paper is dedicated to the memory of Emeritus Professor Rick Speare, whose passing is a great loss to Parasitology in Australia, the Pacific region and the world.

## REFERENCES

1. Traub RJ. *Ancylostoma ceylanicum*, a re-emerging but neglected parasitic zoonosis. *Int J Parasitol* 2013; 43: 1009-1015.
2. Lane HC. *Ancylostoma ceylanicum*, a new human parasite. *Ind Med Gaz* 1913; 48: 216-218.
3. Anten JF, Zuidema PJ. Hookworm infection in Dutch servicemen returning from West New Guinea. *Trop Geogr Med* 1964; 16: 216-224.
4. Ngui R, Lim YA, Traub R, Mahmud R, Mistam MS. Epidemiological and genetic data supporting the transmission of *Ancylostoma ceylanicum* among human and domestic animals. *PLoS Negl Trop Dis* 2012; 6: e1522.
5. Inpankaew T, Schär F, Dalsgaard A, Khieu V, Chimnoi W, Chhoun C, Sok D, Marti H, Muth S, Odermatt P, Traub RJ. High prevalence of *Ancylostoma ceylanicum* hookworm infections in humans, Cambodia, 2012. *Emerg Infect Dis* 2014; 20: 976-982.
6. Ngui R, Mahdy MA, Chua KH, Traub R, Lim YA. Genetic characterization of the partial mitochondrial cytochrome oxidase c subunit I (cox 1) gene of the zoonotic parasitic nematode, *Ancylostoma ceylanicum* from humans, dogs and cats. *Acta Trop* 2013; 128: 154-157.
7. Croese J, Fairley S, Loukas A, Hack J, Stronach P. A distinctive aphthous ileitis linked to *Ancylostoma caninum*. *J Gastroenterol Hepatol* 1996; 11: 524-531.
8. Kline K, McCarthy JS, Pearson M, Loukas A, Hotez PJ. Neglected tropical diseases of Oceania: review of their prevalence, distribution, and opportunities for control. *PLoS Negl Trop Dis* 2013; 7: e1755.
9. Hughes RC, Sharp DS, Hughes MC, Akau'ola S, Heinsbroek P, Velayudhan R, Schulz D, Palmer K, Cavalli-Sforza T, Galea G. Environmental influences on helminthiasis and nutritional status among Pacific schoolchildren. *Int J Environ Health Res* 2004; 14: 163-177.
10. Hsiao SHM, Tsai JJ, Wu LK, Dalipanda T, Lai WT. The prevalence of skin/soil transmitted helminthiasis in Melanesian community. 16th International Congress on Infectious Diseases, Capetown, South Africa, 2-5 April 2014. Abstract 45.003. (<http://www.xcdsystem.com/icid2014/45.003.html>, accessed 28 January 2015).
11. Harrington H, Bradbury R, Taeka J, Asugeni J, Asugeni V, Igeni T, Gwalaa J, Newton L, Faanuabae CE, Kilivisi FL, Esau D, Flores A, Ribeyro E, Liku D, Muse A, Asugeni L, Telene J, MacLaren DJ, Massey PD, Muller R, Speare R. Prevalence of soil transmitted helminths in remote villages in East Kwaio, Solomon Islands. *West Pacific Surveillance Response J* 2015; 6.
12. Lambert SM. Medical conditions in the South Pacific. *Med J Aust* 1928; 2: 362-378.
13. Haydon GAM, Bearup AJ. *Ancylostoma braziliense* and *A. ceylanicum*. *Trans Roy Soc Trop Med Hygiene* 1963; 57: 76.
14. Traub RJ, Hobbs RP, Adams PJ, Behnke JM, Harris PD, Thompson RC. A case of mistaken identity--reappraisal of the species of canid and felid hookworms (*Ancylostoma*) present in Australia and India. *Parasitology* 2007; 134: 113-119.
15. Yoshida Y. Comparative studies on *Ancylostoma braziliense* and *Ancylostoma ceylanicum*. II. The infective larval stage. *J Parasitol* 1971; 57: 990-992.
16. Brunet J, Lemoine JP, Lefebvre N, Denis J, Pfaff AW, Abou-Bacar A, Traub RJ, Pesson B, Candolfi E. Bloody diarrhea associated with hookworm infection in traveler returning to France from Myanmar. *Emerg Infect Dis* 2015; 21: 1878-1879.
17. Koehler AV, Bradbury RS, Stevens MA, Haydon SR, Jex AR, Gasser RB. Genetic characterization of selected parasites from people with histories of gastrointestinal disorders using a mutation scanning-coupled approach. *Electrophoresis* 2013; 34: 1720-1728.
18. Stewart L. The taxonomy of *Ancylostoma* species in the Townsville region of North Queensland. MSc thesis, James Cook University, Australia. 1994.
19. Palmer CS, Traub RJ, Robertson ID, Hobbs RP, Elliot A, While L, Rees R, Thompson RC. The veterinary and public health significance of hookworm in dogs and cats in Australia and the status of *A. ceylanicum*. *Vet Parasitol* 2007; 145: 304-313.
20. Pattison D, Speare R. Strongyloidiasis in participants of the Regional Assistance Mission to Solomon Islands (RAMSI). *Med J Aust* 2008; 189: 203-206.
21. Visser JT, Narayanan A, Campbell B. *Strongyloides*, dengue fever, and tuberculosis conversions in New Zealand police deploying overseas. *J Trav Med* 2012; 19: 178-182.
22. Croese J, Speare R. Intestinal allergy expels hookworms: seeing is believing. *Trends Parasitol* 2006; 22: 547-550.
23. Schad GA, Chowdhury AB, Dean CG, Kochar VK, Nawalinski TA, Thomas J, Tonascia JA. Arrested development in human hookworm infections: an adaptation to a seasonally unfavorable external environment. *Science* 1973; 180: 502-504.
24. Nawalinski TA, Schad GA. *Arrested development* in *Ancylostoma duodenale*: course of a self-induced infection in man. *Am J Trop Med Hyg* 1974; 23: 895-898.
25. Prociw P, Luke RA. Evidence for larval hypobiosis in Australian strains of *Ancylostoma duodenale*. *Trans R Soc Trop Med Hyg* 1995; 89: 379.
26. Dryanovski DI, Dowling C, Gelmedin V, Hawdon JM. RNA and protein synthesis is required for *Ancylostoma caninum* larval activation. *Vet Parasitol* 2011; 179: 137-143.