

Contents lists available at [ScienceDirect](#)

International Journal of Surgery Case Reports

journal homepage: www.casereports.com

Concurrent Spigelian hernia and falciform ligament hernia in a 67-year-old female



Aaron S. Griffin^{a,*}, Nathan R. Schaefer^b, Eshwarshanker Jeyarajan^b, Trent Cross^c

^a Department of Surgery, Cairns Base Hospital, 165–171 Esplanade, Cairns 4870 Queensland, Australia

^b Griffith University, Gold Coast Department of Surgery, Gold Coast University Hospital, Australia

^c James Cook University, Cairns Base Hospital, Australia

ARTICLE INFO

Article history:

Received 2 February 2015

Received in revised form 29 May 2015

Accepted 31 May 2015

Available online 6 June 2015

Keywords:

Spigelian

Hernia

Falciform ligament

Internal hernia

Abdominal wall

ABSTRACT

INTRODUCTION: Internal abdominal hernias account for 1% of all hernias but 5.8% of all bowel obstructions and hence are of significant clinical importance. Similarly Spigelian hernias account for only 0.12–2% of all abdominal wall hernias.

CASE PRESENTATION: We present and discuss the management of a case that presented with concurrent falciform ligament internal abdominal hernia and Spigelian hernia. We believe this is the first reported case of such an occurrence in the literature.

CONCLUSION: Due to the advancements in computer topography (CT) imaging many internal and Spigelian hernias are diagnosed pre-operatively though these scan are not always available or indicated in cases of suspected small bowel obstruction. Due to the high mortality rate of undiagnosed internal hernias a high clinical suspicion must be maintained. The authors recommend laparoscopic trans-abdominal repair of Spigelian hernias in order to examine the abdominal contents and exclude rare, though potentially serious internal hernias.

© 2015 The Authors. Published by Elsevier Ltd. on behalf of Surgical Associates Ltd. This is an open access article under the CC BY-NC-ND license (<http://creativecommons.org/licenses/by-nc-nd/4.0/>).

1. Introduction

Internal abdominal hernias present a rare and challenging diagnostic dilemma for the surgeon. Although accounting for 1% of all hernias they account for up to 5.8% of all bowel obstructions and as such are of significant clinical importance [1]. Congenital internal hernias can be classified as either paraduodenal (50–55%), pericecal (10–15%), foramen of Winslow (6–10%), transmesenteric and transmesocolic (8–10%), paravesical (<4%) and intersigmoid (4–8%) according to their anatomical location [1,2]. Other causes of internal hernias include trauma either due to previous surgery or penetrating trauma and chronic inflammation such as cholecystitis [2]. Hernias occurring through the falciform ligament are a particularly rare cause of internal hernia with only 37 cases reported in the international literature [3]. These hernias are increasing in frequency due to the number of iatrogenic injuries to the falciform ligament and possibly increased prevalence of cholecystitis [3].

Spigelian hernias (or ventral hernias) are a rare abdominal wall hernia that account for 0.12–2% of all abdominal wall hernias [4]. In adults they are considered acquired and result when abdominal fat protrudes between a separation of internal oblique muscle and transversus muscle fibres. This may occur secondary to pregnancy,

chronic cough, straining and morbid obesity due to a raised intra-abdominal pressure or abdominal operations [5].

2. Presentation of case

We present a case of a 67-year-old lady who was seen in rural surgical clinic and booked for repair of a symptomatic Spigelian hernia. She reported pain in her right lower quadrant over a three-year period and had an accompanying CT scan which demonstrated the hernia containing omentum and preperitoneal fat. She had no previous surgery and nothing else to preclude laparoscopic repair and was booked for a laparoscopic mesh repair. Optical entry in the left upper quadrant was used to instil laparoscopy and two 5 mm ports were inserted on the left abdomen to allow dissection and mesh placement. At laparoscopy an incidental falciform ligament hernia was found containing small bowel. The falciform ligament was divided and a concurrent defect that continued onto anterior wall was covered with a piece of Bard Ventralex™ mesh secured with a double crown of absorbable tacks. The Spigelian hernia was repaired with a similar piece of Bard Ventralex mesh and secured in a similar fashion. She made an uneventful post operative recovery and was discharged on the second post operative day. Follow up CT imaging performed at a three month follow up showed the mesh remaining in situ with no evidence of recurrent hernia. Clinically the patient remains symptom free 12 months after the laparoscopy [Fig. 1](#).

* Corresponding author.

E-mail address: az.griffin@gmail.com (A.S. Griffin).

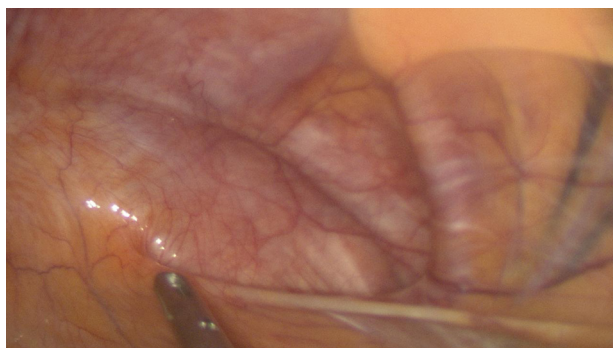


Fig. 1. Spigelian hernia defect visualised during laparoscopy.

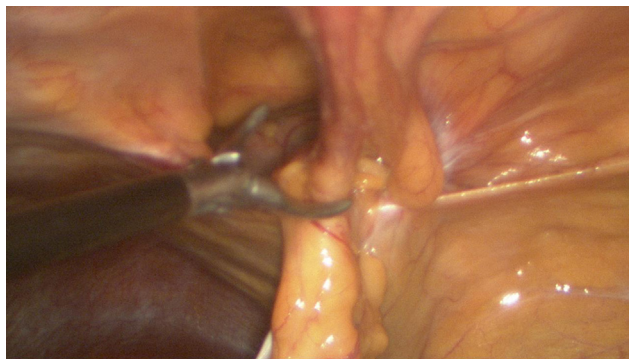

Fig. 2. A laparoscopic view of the falciform ligament defect with omentum herniated through it.

3. Discussion

Falciform ligament hernias like all internal abdominal hernias present most commonly as bowel obstructions with 50% requiring a bowel resection [3]. The largest review on falciform ligament hernias by Egle et al. illustrates perfectly the difficulty in clinically diagnosing these hernias with only five of 37 cases having a diagnosis pre-operatively [3]. Computer topography imaging (CT) has a sensitivity of 35.7% when identifying falciform ligament hernias when performed pre-operatively [3].

Spigelian hernias present as either a lateral abdominal wall mass that is reducible and has a cough impulse or if incarcerated may present as visceral abdominal pain. Palpation of a lump can be unreliable due to coverage of the hernia by the external oblique muscle [6]. A high index of clinical suspicion must be maintained as 9 out of 17 cases in a series by Artioukh and Walker were not suspected pre-operatively [7]. CT imaging of a Spigelian hernia is by far the most accurate diagnostic method of demonstrating a hernia defect passing through the muscular layers [8] though ultrasound scanning can demonstrate hernia defects in the abdominal wall and bowel contained within them in the right hands [6]. In the case of our patient the diagnosis of the falciform ligament hernia was made intra operatively and this was allowed by the laparoscopic approach, which then allowed the repair of both hernias Fig. 2.

Falciform ligament hernias are more likely to be encountered intra-operatively when operating on a patient with a small bowel obstruction rather than a known diagnosis pre-operatively and as such many differing surgical approaches have been made. In the review published by Egle et al. the majority of surgeons elected to divide the falciform ligament and ligament of teres following assessment of the herniated bowel and possible resection [3]. Unfortunately information regarding the nature of these operations (laparoscopic verses open) is not available for comparison. The likely aetiology of the falciform ligament hernia in the case of

our patient remains unknown though congenital is the most likely as there was no known iatrogenic cause.

Spigelian hernias necessitate surgical repair due to their high rates of strangulation, incarceration and intestinal obstruction [9]. Surgical repair may be either direct closure through an abdominal incision or with mesh. Recently laparoscopic repair preperitoneal of these hernias has been shown to reduce hospital stays morbidity [10]. The advantage of a trans abdominal laparoscopic repair, such as the one performed in our case, is that it allows for examination of the abdominal organs and as such surgical repair of incarcerated and strangulated hernias [10].

4. Conclusion

CT imaging has increased the diagnosis pre-operatively of rare abdominal wall and internal abdominal hernias [3,8]. Despite this fact laparoscopic examination of all possible herniation sites and examination of the abdominal organs is a valuable surgical tool when available if there is a diagnostic dilemma and the patient not critically obstructed. This case demonstrates the difficulty in diagnosing internal hernias, when suspicion is low, by CT imaging. Although laparoscopy in this case was able to diagnose and repair this internal hernia intraoperative, it remains unclear if this hernia was contributing to the presenting symptomatology. While exceedingly rare, this case demonstrates that modern imaging and surgical techniques, while essential, need to be balanced with clinical acumen and a high degree of suspicion for uncommon pathologies.

Conflicts of interest

The authors of this study declare no conflicts of interest and received no monetary benefits, or otherwise for this manuscript. This research is original and all authors have reviewed the final manuscript.

Funding

No external funding was sourced, or provided for this manuscript or research.

Ethical approval

Ethics approval was not required due to explicit patient consent.

Consent

Patients informed, written consent for use of de-identified data and photos has been obtained.

Author contribution

Aaron Griffin: Primary Author (corresponding).
Eshwarshanker Jeyarajan: Co-Author.
Nathan Schaefer: Co-Author.
Trent Cross: Supervisor, Primary Surgeon and Co-Author.

Guarantor

I, Aaron Griffin, Guarantee this manuscript as the primary, and corresponding author.

References

- [1] R.M. Gore, M.S. Levine, Textbook of Gastrointestinal Radiology, 2nd ed., W.B. Saunders, Philadelphia, 2000.

- [2] O. Salar, A.M. El-Sharkawy, R. Singh, W. Speake, Internal hernias: a brief review, *Hernia: J. Hernias Abdominal Wall Surg.* 17 (3) (2013) 373–377, <http://dx.doi.org/10.1007/s10029-012-1023-1>, PubMed PMID. 23224076.
- [3] J. Egle, A. Gupta, V. Mittal, P. Orfanou, S. Silapaswan, Internal hernias through the falciform ligament: a case series and comprehensive literature review of an increasingly common pathology, *Hernia J. Hernias Abdominal Wall Surg.* 17 (1) (2013) 95–100, <http://dx.doi.org/10.1007/s10029-012-0990-6>, PubMed PMID. 23053747.
- [4] T.J. Houlihan, A review of Spigelian hernias, *Am. J. Surg.* 131 (6) (1976) 734–735, PubMed PMID. 937655.
- [5] L. Spangen, Spigelian hernia, *World J. Surg.* 13 (5) (1989) 573–580, PubMed PMID. 2683401.
- [6] A.T. Richards, Spigelian hernias, *Oper. Tech. Gen. Surg.* 6 (3) (2004) 228–239, <http://dx.doi.org/10.1053/j.optechgensurg.2004.07.004>
- [7] D.Y. Artioukh, S.J. Walker, Spigelian herniae: presentation, diagnosis and treatment, *J. R. Coll. Surg. Edinburgh* 41 (4) (1996) 241–243.
- [8] E.J. Balthazar, B.R. Subramanyam, Radiographic diagnosis of Spigelian hernia, *Am. J. Gastroenterol.* 78 (8) (1983) 525–528, PubMed PMID. 6881121.
- [9] D.W. Larson, D.R. Farley, Spigelian hernias: repair and outcome for 81 patients, *World J. Surg.* 26 (10) (2002) 1277–1281, <http://dx.doi.org/10.1007/s00268-002-6605-0>, PubMed PMID. 12205553.
- [10] M.-E. Alfredo, C. Luis, G. Enrique, M. Juan-Gervasio, L.A. José, C. Manuel, Open vs laparoscopic repair of Spigelian hernia: a prospective randomized trial, *Arch. Surg.* 137 (11) (2002) 1266–1268, <http://dx.doi.org/10.1001/archsurg.137.11.1266>.

Open Access

This article is published Open Access at scimedirect.com. It is distributed under the [IJSCR Supplemental terms and conditions](#), which permits unrestricted non commercial use, distribution, and reproduction in any medium, provided the original authors and source are credited.