
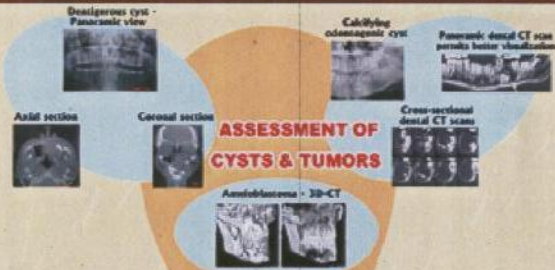



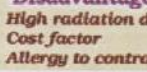
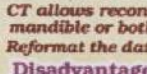
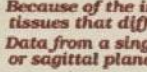
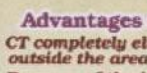





APPLICATIONS OF CT IN DENTISTRY

ASSESSMENT OF CYSTS & TUMORS

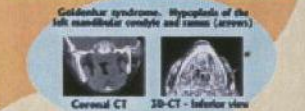



ORAL DIAGNOSIS

ASSESSMENT OF TMJ



ASSESSMENT OF DEVELOPMENTAL ANOMALIES

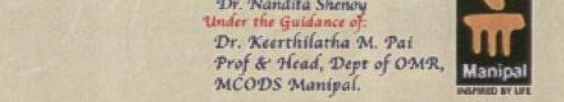



ORAL & MAXILLOFACIAL SURGERY




- OTHER USES**
- 1) 3D - CT used for planning for surgery
 - 2) Determination of new bone formation after marsupialization of jaws cysts.
 - 3) Determination of post surgical displacement of hard tissue structures in TMJ & changes in soft tissue structure such as muscles of mastication & salivary glands

ORTHODONTICS



Presented By:
Dr. Amar A. Sholapurkar & Dr. Nandita Shenoy
Under the Guidance of:
Dr. Keerthilatha M. Pai
Prof & Head, Dept of OMR, MCODS Manipal.

PERIODONTICS



Advantages of CT over Conventional Film Radiography

- CT completely eliminates the superimposition of images of structures outside the area of interest.
- Because of the inherent high-contrast resolution of CT, differences between tissues that differ in physical density by less than 1% can be distinguished;
- Data from a single CT imaging procedure can be viewed in the axial, coronal, or sagittal planes.
- CT allows reconstruction of cross-sectional images of the entire maxilla or mandible or both from a single imaging procedure
- Reformat the data acquired from axial CT scans into three-dimensional images

Disadvantages

- High radiation dose to patient
- Cost factor
- Allergy to contrast agent