Veterinary Laboratories Agency

Malignant catarrhal fever due to Caprine Herpesvirus Type-2 in a Sika deer with alopecia in England

[1]FOYLE L, [1]FULLER HE, [2]HIGGINS RJ, [3]RUSSELL G, [3]WILLOUGHBY K, [4]*FOSTER AP, [5]ROSIE WG.
[1]VLA Luddington, Stratford-on-Avon, Warwickshire, CV37 9SJ.
[2]VLA Lasswade, Pentlands Science Park, Bush Loan, Penicuik, Midlothian, EH26 OPZ.
[3] Moredun Research Institute, Pentlands Science Park, Bush Loan, Penicuik, Midlothian, EH26 0PZ.
[4]VLA Shrewsbury, Kendal Road, Harlescott, Shrewsbury, Shropshire, SY1 4HD.
[5] Vale Veterinary Group, Areley Kings, Stourport-on-Severn, Worcestershire, DY13 0LB.

AVTRW April 2008

Introduction

- Malignant catarrhal fever (MCF) is associated with signs of systemic disease and death in ruminant species belonging to the subfamilies *Bovinae*, *Cervinae*, and *Odocoileinae*
- Variety of herpes viruses implicated including Caprine herpes virus (CpVH2) - disease reports from North America in Sika deer and white-tailed deer
- OvHV-2 and CpHV-2 have been detected in wild cervids in Norway (Vikøren *et al.* 2006)

Introduction

- Serological surveys in Germany of wild cervids have demonstrated evidence of exposure to MCF viruses
- Goats - reservoir hosts for CpVH2
- Histopathological and virological findings in Sika deer with cutaneous and systemic disease compatible with MCF infection have not been reported in the UK

History

- Ante mortem skin samples had histological findings of chronic hyperplastic granulomatous dermatitis with destructive giant cell folliculitis
- Female sika deer (*Cervus nippon*) 7 years old presented for post mortem examination
- Two-month history of weight loss and diffuse alopecia
- Enclosure housing sika deer (19) with pygmy goats (50)


411

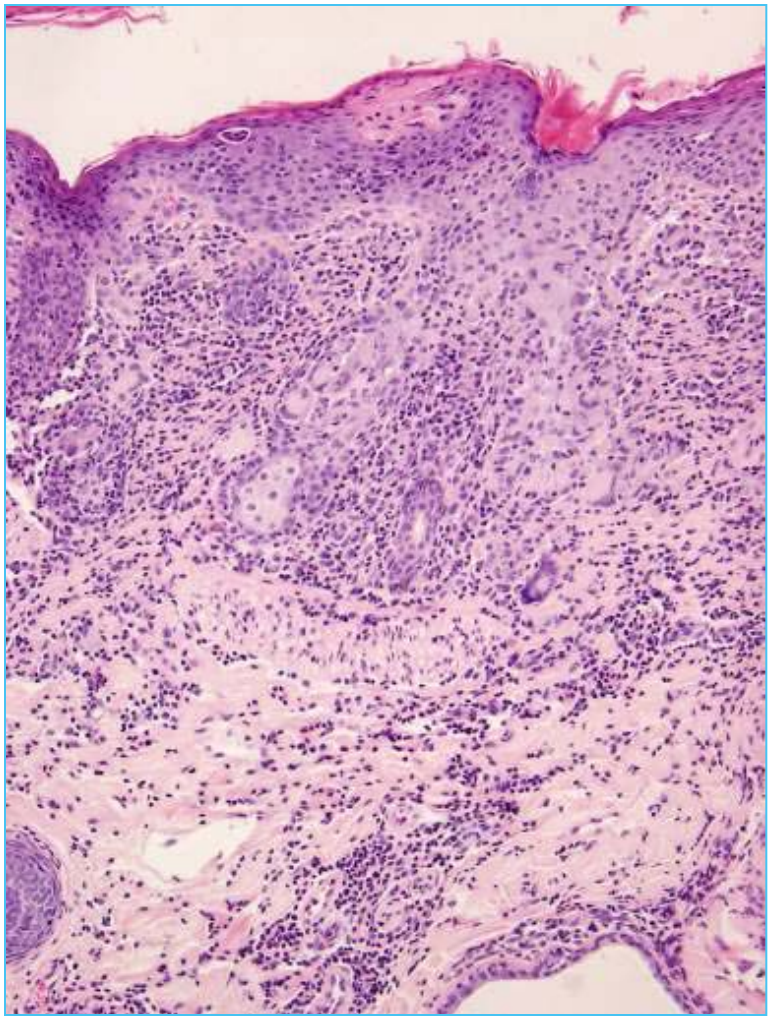

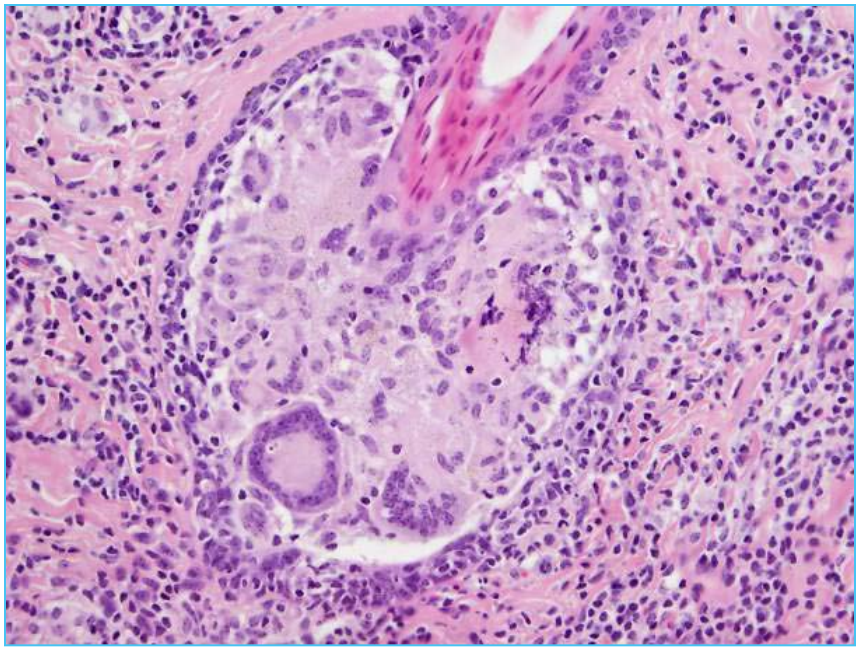

Skin - histopathological findings

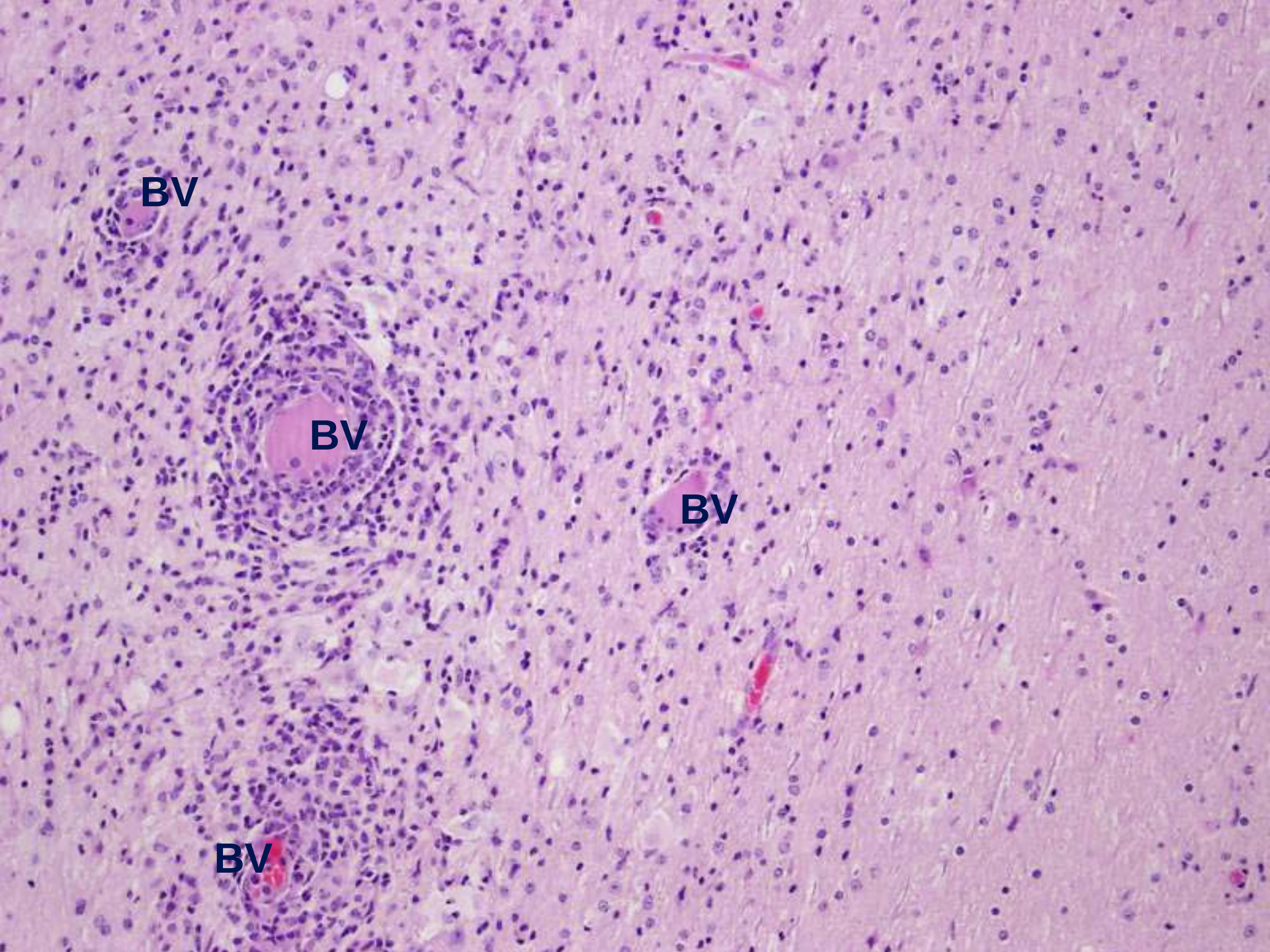
BV
BV
BV
BV

Post mortem histopathological findings

- Severe vasocentric meningoencephalitis
- Subacute hyperplastic granulomatous necrotising lymphadenitis
- Granulomatous dermatitis & giant cell folliculitis
- Sub acute non-suppurative periportal hepatitis
- Acute pulmonary congestion, oedema & haemorrhage
- Acute haemorrhagic enteropathy
- Systemic vasculitis / vasculopathy


white
matter
pia mater

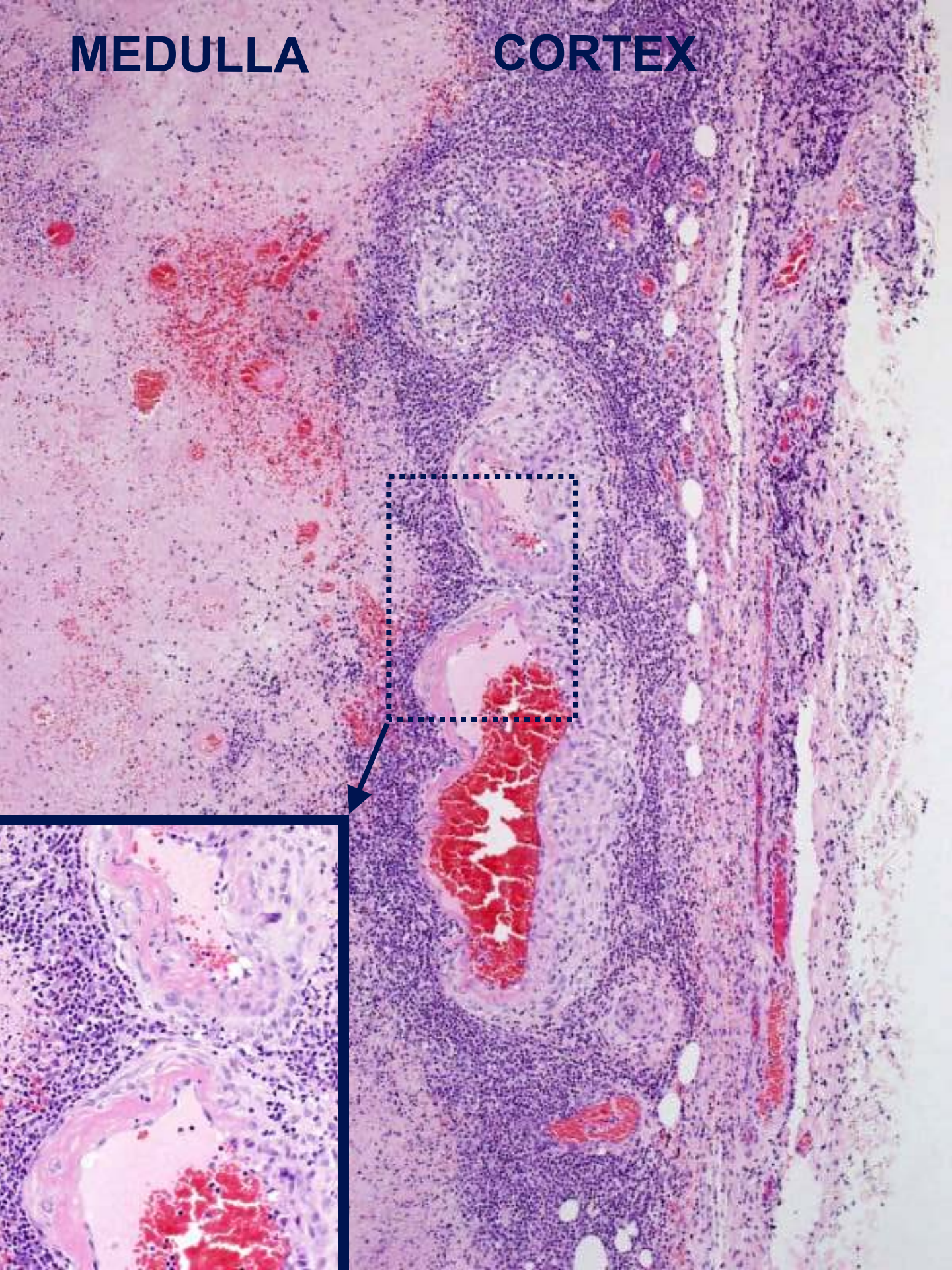
MEDULLA
CORTEX

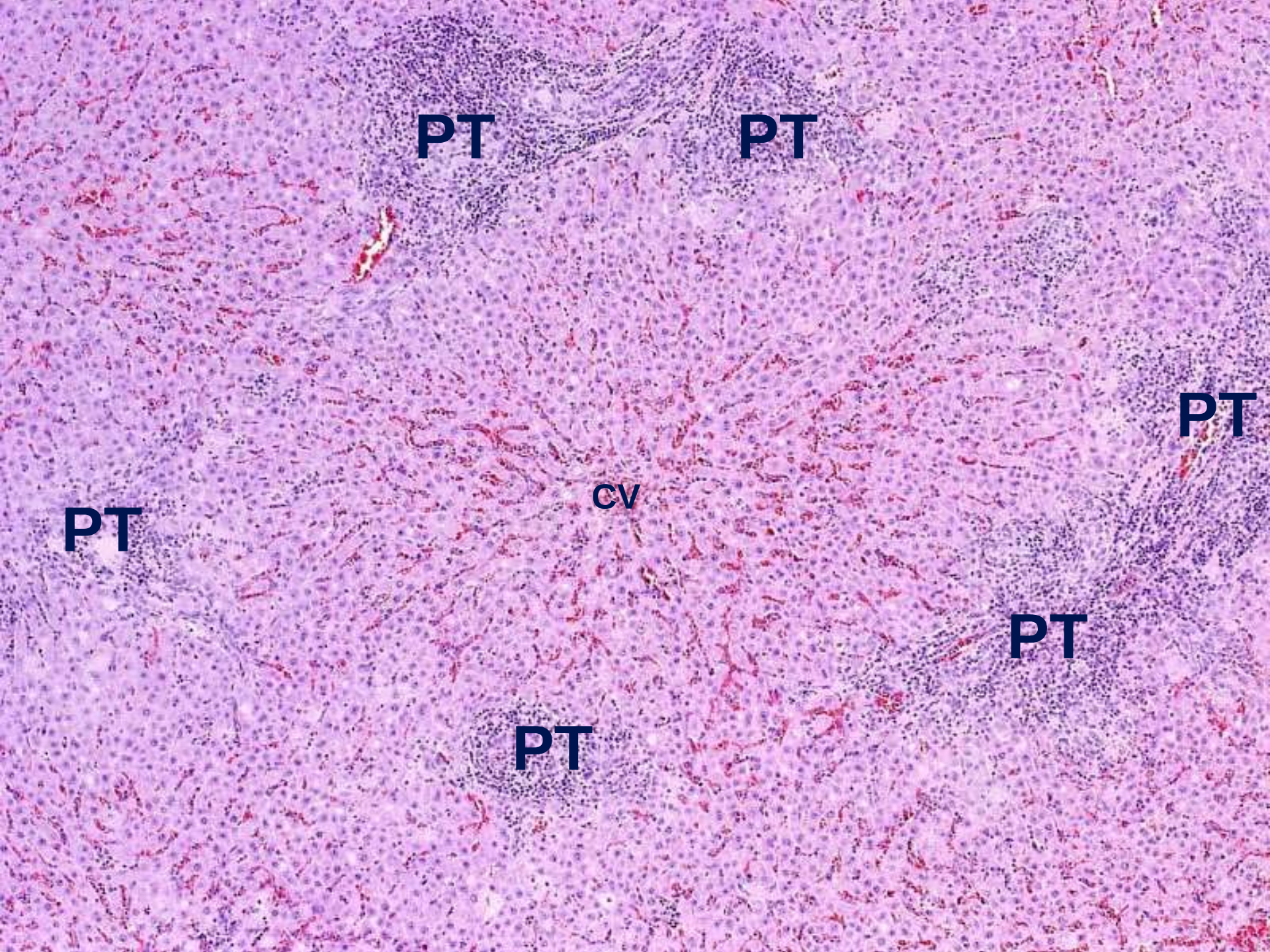
PT
PT
PT
CV
PT
PT
PT

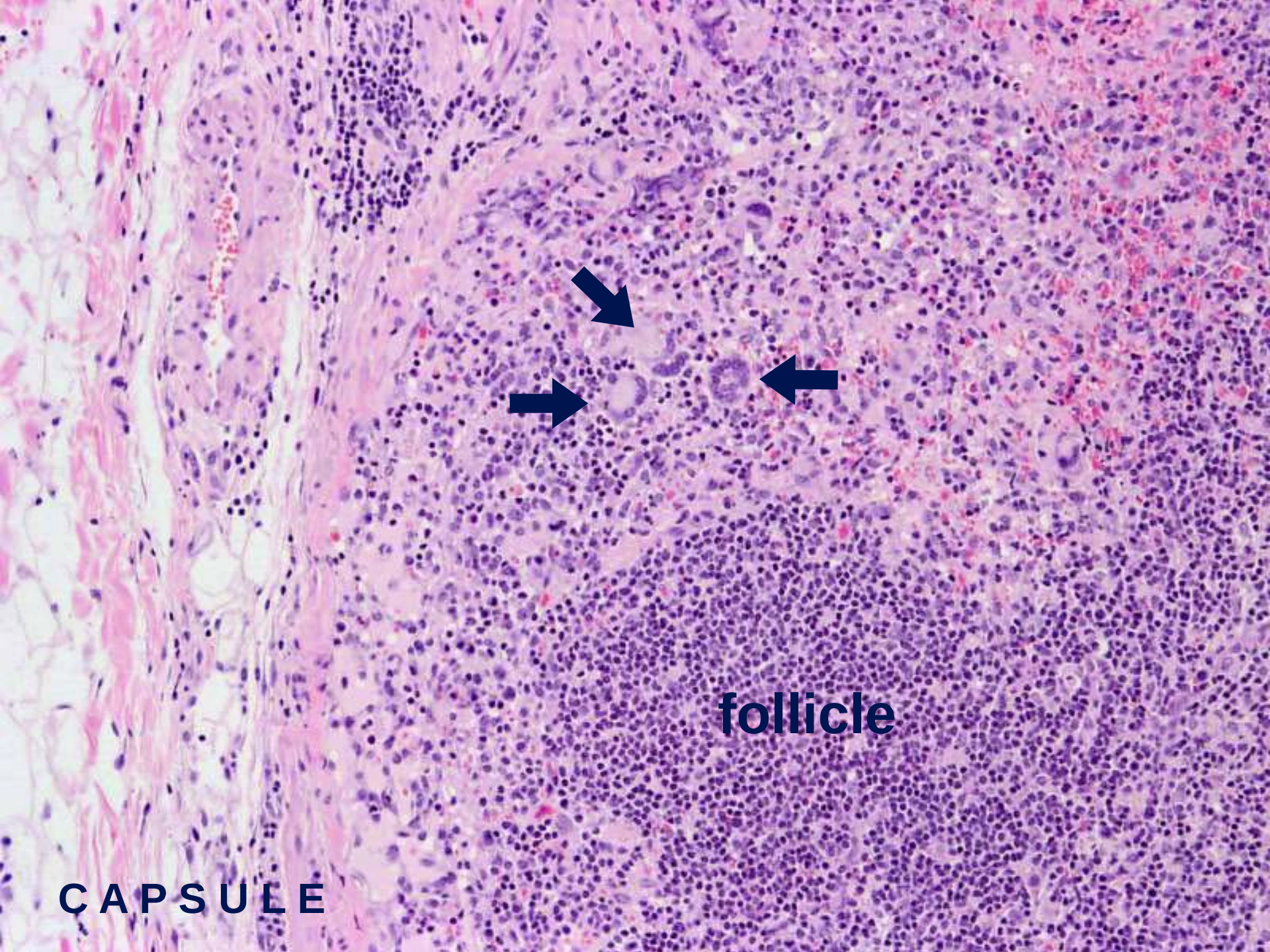
follicle
CAPSULE

Other cases of MCF-2 in Sika deer

- At least one other case of MCF like disease has been reported in another zoological collection in England
- No skin lesions
- Contact with Cashmere goat
- Fixed tissues positive for OvHV-2 in the sentinel deer, one in-contact deer and the resident Cashmere goat

Molecular studies

- Lymph node tissue (formalin-fixed) positive for CpHV-2 by PCR
- Blood samples from in contact sika deer and pygmy goats were screened by CpHV-2 PCR with negative results
  - PCR may not be sensitive enough to rule out latent infection in goats
  - Buffy coat may not be optimum sample to detect latent virus
- IFAT was not possible due to lack of validated secondary reagents for goats/sika deer

MCF and Sika Deer

Conclusions

1. Captive Sika deer collections are at potential risk of developing MCF disease if housed with goats
2. Wild cervids may be at risk of developing MCF in association with Ov-HV-2 and Cp-HV-2

Acknowledgements:
We are indebted to Alex Schock and Sandra Scholes for the histopathology images. Mark Stidworthy, Sarah Owens and David Gabriel for providing information about case material in the second zoological collection