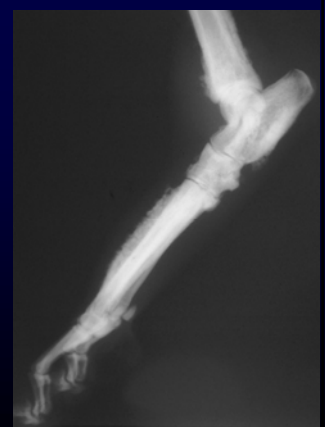

This session is sponsored by



A pot-pourri of
paraneoplastic
syndromes



The Interactivity

*In medicine, there is rarely
'one right way' to do
things. I've shaped my
questions to reflect this.*

The Interactivity

*We won't have time to delve
into every aspect of
every case.*

The Interactivity

*We shall have time to cover a
few of the many different
kinds of paraneoplastic
syndrome.*

The Interactivity

*We don't need to use five
choices in every question.*

The Interactivity

So let's try it out...



Try it out: Your demographics...



1. I graduated within the last 3 years
2. I graduated 3 - 5 years ago
3. I graduated 5 - 10 years ago
4. I graduated 10 - 20 years ago
5. I graduated >20 years ago



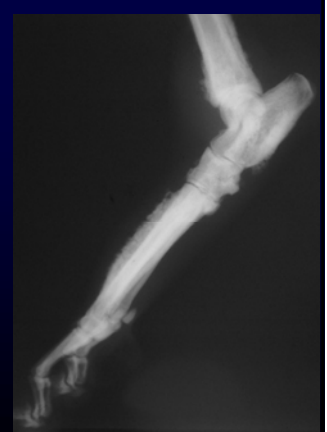Try it out: NZ



1. I plan to have a holiday in New Zealand within the next year
2. I plan to have a holiday in New Zealand within the next 3 years
3. I plan to have a holiday in New Zealand within the next 10 years
4. I do not plan to visit New Zealand



A pot-pourri of paraneoplastic syndromes



Definition

“An [unusual] consequence of a neoplasm, manifested at a distance from the primary mass(es), and often as a consequence of secretion of a hormone or hormone-like substance”

Their significance...

- Often the earliest sign of cancer
- A significant cause of morbidity and mortality in their own right
- Sometimes useful markers of remission
- Harbingers of tumour recurrence (can therefore, occasionally, be helpful)

Many are...

- Endocrinological
- Metabolic
- Haematological

Others are...

- Gastrointestinal
- Neurological
- Renal
- Cutaneous

Many of these seem to be immune-mediated

First case, let's go!



George

A 10 year-old MC black Labrador Retriever



- It is 9 am. He seized at 7.30 this morning, apparently for the first time in his life. It lasted for about 3 minutes.
- Now he's a bit quieter than usual, but otherwise normal.

George

A 10 year-old MC black Labrador Retriever



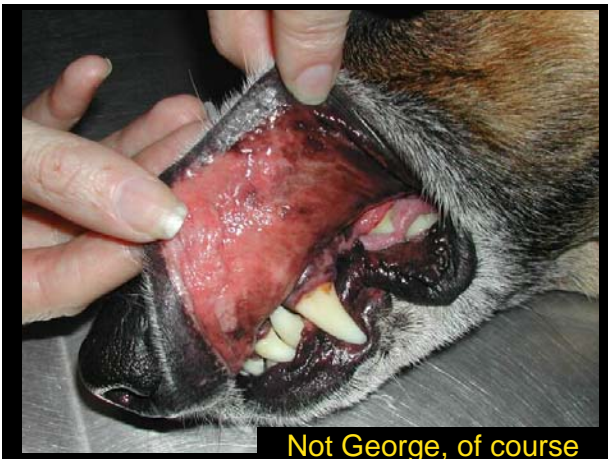- No previously detected illnesses apart from a low grade elbow lameness that has been present for several years
- He receives carprofen whenever he is thought to be uncomfortable

George


A 10 year-old MC black Labrador Retriever



- T° 39.4 °C, pulse 110, RR 24 (intermittently panting)
- Normal skin turgor
- Warm, moist, 'very' red mucous membranes



George
A 10 year-old MC black Labrador Retriever



- Large palpable mass or masses in the cranial, dorsal abdomen

George
A 10 year-old MC black Labrador Retriever





Your next step(s) 

Please discuss this with your neighbour for a few moments and come up with a shared plan...





Least appropriate next step at this stage?

1. Routine haemogram, serum chemistry profile, urinalysis
2. PCV / TPP (in-house)
3. Abdominal imaging
4. Thoracic imaging
5. Serum erythropoietin



Least appropriate next step at this stage?

1. Routine haemogram, serum chemistry profile, urinalysis
2. PCV / TPP / Dex (in-house)
3. Abdominal imaging
4. Thoracic imaging
5. **Serum erythropoietin**



Well-recognized sources of diagnostic error in 'human' medicine

“Narrowing down too soon”

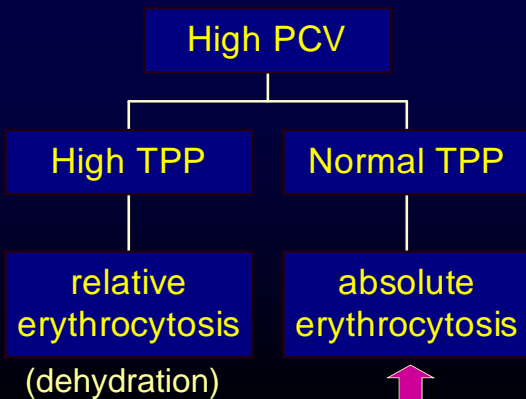
George
A 10 year-old MC black Labrador Retriever



- PCV 75 TPP 78
- Glucose not low

Does this look like a relative or an absolute erythrocytosis to you?

1. Relative
2. Absolute
3. What does that mean?
4. Neither
5. I'm just taking the micky by pressing number "5".



Does this look like a relative or an absolute erythrocytosis to you?

1. Relative
2. **Absolute**
3. What does that mean?
4. Neither
5. I'm just taking the micky by pressing number "5".

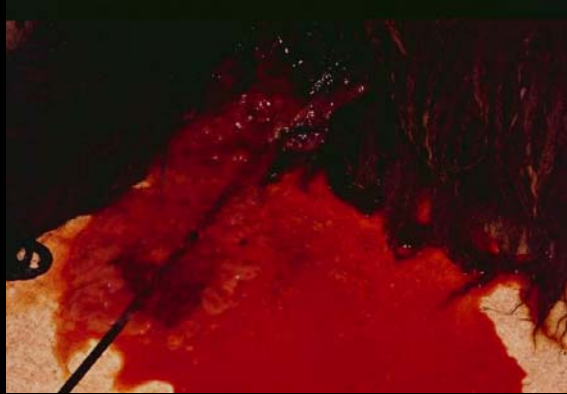

George
A 10 year-old MC black Labrador Retriever



- PCV 75 TPP 78

In another animal, could figures like these ever reflect a 'relative' erythrocytosis?



Haemorrhagic gastroenteritis

Updated problem list

- History of lameness / carprofen
- 'Seizured' this morning
- Palpable abdominal mass(es)
- Erythrocytosis (seems to be absolute)

Differential diagnoses for absolute erythrocytosis

- Relative erythrocytosis (dehydration + hypoproteinaemia)
- Breed variation
- Hyperadrenocorticism
- Some longstanding cardiovascular and pulmonary diseases

Differential diagnoses for absolute erythrocytosis

- Some non-neoplastic renal diseases (cysts, hydronephrosis)
- Polycythaemia vera (primary erythrocytosis)
- Paraneoplastic causes

Paraneoplastic erythrocytosis

Pathogenesis

- Tumour itself produces erythropoietin
- Tumour causes renal ischaemia / tissue hypoxia, leading to an increase in release of erythropoietin by the kidney(s)

Tumour-associated erythrocytosis

Pathogenesis

- Tumour causes arterial hypoxaemia (lung? heart? airways?), the kidneys respond 'appropriately' by releasing more erythropoietin.

Updated problem list

- History of lameness / carprofen
- 'Seizured' this morning
- Palpable abdominal mass(es)
- Erythrocytosis (seems to be absolute)

George
A 10 year-old MC black
Labrador Retriever



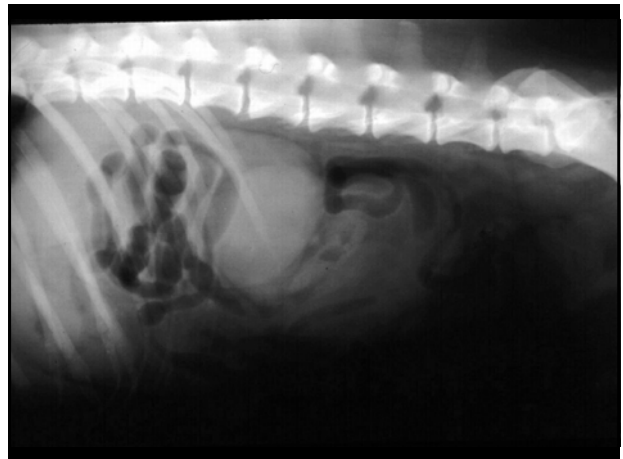
Updated plan

George
A 10 year-old MC black
Labrador Retriever



Imaging

Haem, Chem, UA



Abdominal imaging

- Bilaterally symmetrical, marked renomegaly
- Kidneys are diffusely and severely infiltrated
- Lymphoma is considered a likely diagnosis

Thoracic radiography

- No abnormalities detected

Routine haemogram, serum biochemistry and urine analysis

- USG 1.019
- Creatine kinase 1209
- Otherwise, normal

What would you most like to do now?

Another chance to share ideas with your neighbour...



What would you most like to do now?

1. Refer him
2. Hit the books and read about approaches to absolute erythrocytosis
3. Remove a unit or two of blood, replace with crystalloid, and think again
4. Biopsy one or both kidneys



Updated Plan...

- Admit and monitor
- Lower his HCT so he is in better shape for further investigations (could save the blood)
- FNAB kidney
- Check haemostatic status, blood pressure; then biopsy kidney
- \pm Serum EPO

Paraneoplastic erythrocytosis

Kinds of tumours previously associated

- Renal tumours
- Liver tumours
- Nasal fibrosarcoma
- T.V.T.
- Others

Paraneoplastic erythrocytosis

Typical clinical features

- Lethargy, depression, inappetence
- PU/PD
- Red mucous membranes
- \pm Seizures

Paraneoplastic erythrocytosis

Typical clinical features

- Lethargy, depression, inappetence
- PU/PD
- Red mucous membranes
- ± **Seizures**

So why did George seizure?

Choose the least plausible reason

1. Cerebrovascular accident
2. Cerebral hyperoxia (essentially, oxygen toxicity)
3. Increased blood viscosity
4. Poor cerebral blood flow
5. Idiopathic epilepsy



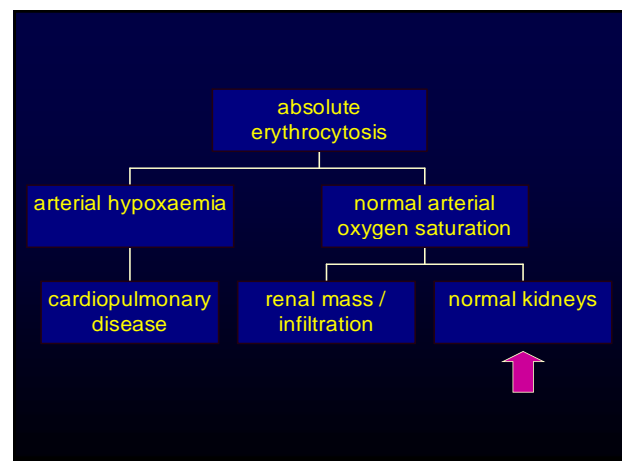
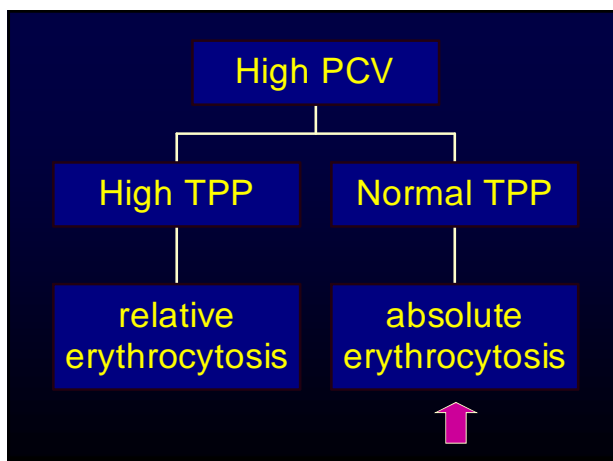
So why did George seizure?

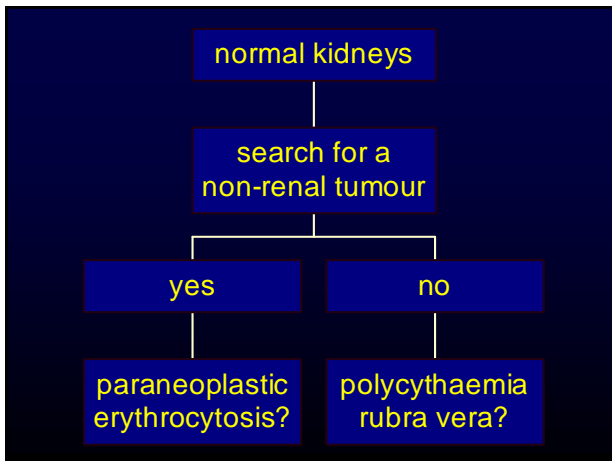
- Poor blood flow, despite high O₂ carrying capacity, leads to poor tissue oxygenation (**becomes a vicious circle**)
- Mainly affects the brain, eyes, kidneys, heart
- May also see systemic hypertension or heart failure

Paraneoplastic erythrocytosis

Management

- Identify the underlying cause and remove it (if possible) or treat it
- Periodic phlebotomy ('venesection')
- ± Hydroxyurea (40-50 mg/kg PO ÷ BID)





GUIDELINES FOR THE DIAGNOSIS, INVESTIGATION AND MANAGEMENT OF POLYCYTHAEMIA/ERYTHROCYTOSIS

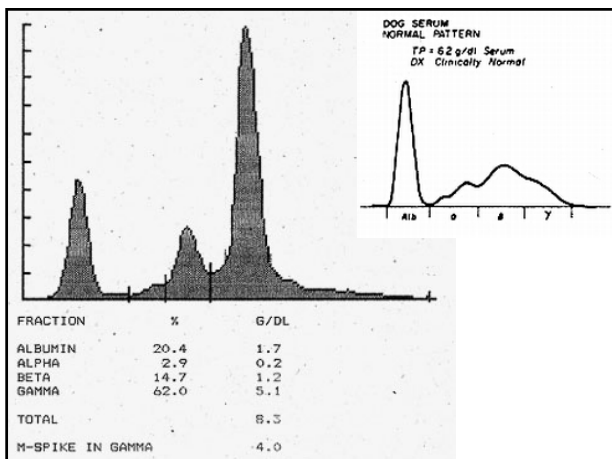
Writing Group
 Mary F. McMullin¹, D. Bareford², P. Campbell³, A.R. Green³, Claire Harrison⁴, Beverley Hunt⁴, D. Oscier⁵, M.I. Polkey⁶, J.T. Reilly⁷, E. Rosenthal⁸, Kate Ryan⁹, T. C. Pearson⁴, Bridget Wilkins¹⁰.

On behalf of the General Haematology Task Force of the British Committee for standards in Haematology

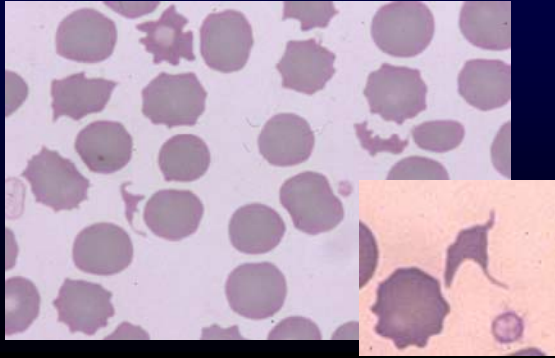
Address for correspondence:
 BCSH Secretary
 British Society for Haematology
 100 White Lion Street
 London N1 9PF
 e-mail: jules@b-s-h.org.uk

- ?** Other cause(s) of hyperviscosity?
1. Multiple myeloma
 2. Lymphoma
 3. Lymphoid leukaemia
 4. "Benign" or primary gammopathy
 5. All of the above
- ?**

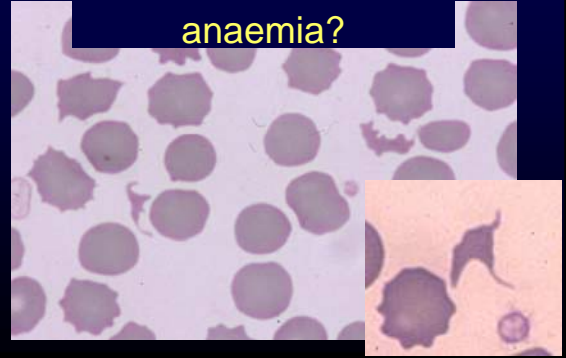
- ?** Other cause(s) of hyperviscosity?
1. Multiple myeloma
 2. Lymphoma
 3. Lymphoid leukaemia
 4. "Benign" or primary gammopathy
 - 5. All of the above**
- ?**



A tricky "quickie"



Most likely neoplastic cause of this kind of anaemia?



Most likely neoplastic cause of this kind of anaemia?

1. Sertoli cell tumour
2. Multiple myeloma
3. Large splenic haemangiosarcoma
4. Nasal fibrosarcoma
5. Bleeding caecal leiomyoma

Most likely neoplastic cause of this kind of anaemia

1. Sertoli cell tumour
2. Multiple myeloma
3. **Large splenic haemangiosarcoma**
4. Nasal fibrosarcoma
5. Bleeding caecal leiomyoma

Another tricky "quickie"


A microcytic, hypochromic, mildly regenerative anaemia with a high, or high normal platelet count

Most likely cause of this kind of anaemia

1. Large renal lymphoma
2. Multiple myeloma
3. Large splenic haemangiosarcoma
4. Nasal fibrosarcoma
5. Bleeding caecal leiomyoma

? Most likely cause of this kind of anaemia **?**

1. Large renal lymphoma
2. Multiple myeloma
3. Large splenic haemangiosarcoma
4. Nasal fibrosarcoma
5. **Bleeding caecal leiomyoma**



Paraneoplastic anaemia

- Failure of production
- Increased destruction
- Increased (external) loss

Another tricky "quickie"

A 10 year-old MC Golden retriever presented for acute collapse with apparent abdominal enlargement, bilaterally symmetrical, non-pruritic truncal alopecia, white, warm, moist gums, good pulse quality, PCV 10, TPP 69.

? Most likely cause of this kind of anaemia **?**

1. Sertoli cell tumour
2. Multiple myeloma
3. Bleeding splenic haemangiosarcoma
4. Nasal fibrosarcoma
5. Bleeding gastric carcinoma

Another tricky "quickie"

A 10 year-old MC Golden retriever presented for acute collapse with apparent abdominal enlargement, bilaterally symmetrical, non-pruritic truncal alopecia, white, warm, moist gums, good pulse quality, PCV 10, TPP 69.

? Most likely cause of this kind of anaemia **?**


- 1. Sertoli cell tumour**
2. Multiple myeloma
3. Large splenic haemangiosarcoma
4. Nasal fibrosarcoma
5. Bleeding gastric carcinoma

Stoogie, a 10 year-old MC mixed breed dog




Stoogie – Previous History

- One year ago, seen for seborrhoea
- Routine blood work at that time showed serum calcium 3.75 mmol/L, otherwise normal
- No action was taken (considered artifactual?)




Stoogie – Recent History

- Some vomiting x 6 months
- Occasional diarrhoea or constipation
- Inappetence
- PU/PD
- Depression, lethargy



Stoogie – Physical Exam

- Depressed
- Slightly underweight
- Pea-sized mass in the right anal sac



? Why is a rectal examination so important in dogs with PU/PD? **?**

1. Check for constipation
2. Check for anal adenoma
3. Check for apocrine gland adenocarcinoma of anal sac
4. Check for pelvic lymphadenopathy, a good indicator of T-cell lymphoma



Why is a rectal examination so important in dogs with PU/PD?



1. Check for constipation
2. Check for anal adenoma
- 3. Check for apocrine gland adenocarcinoma of anal sac**
4. Check for pelvic lymphadenopathy, a sure sign of T-cell lymphoma

Differential diagnoses considered from the history and P.E.

- Numerous causes of PU/PD (especially causes of persistent hypercalcaemia)
- Numerous causes of GI problems, weight loss and lethargy



Stoogie – Initial Plan

- History
- Physical examination
- Haemogram
- Serum chemistry profile
- Urinalysis
- Abdominal radiographs



Stoogie – Initial lab. results (everything else normal)

- BUN 33.9 mmol/L
- Creatinine 424.0 μ mol/L
- Phosphorus 2.1 mmol/L
- Calcium 3.82 mmol/L

Stoogie – Initial lab. results

- Urine S.G. 1.011
- WBCs 40-50 / hpf
- RBCs 3-5 / hpf
- Epithelial cells 2-3 / hpf

(*E.coli* subsequently cultured)



If you wanted to lower his blood Ca, at this stage, while you work him up...

Choose the least appropriate way:

1. 0.9% NaCl
2. Frusemide
3. Prednisolone
4. Calcitonin

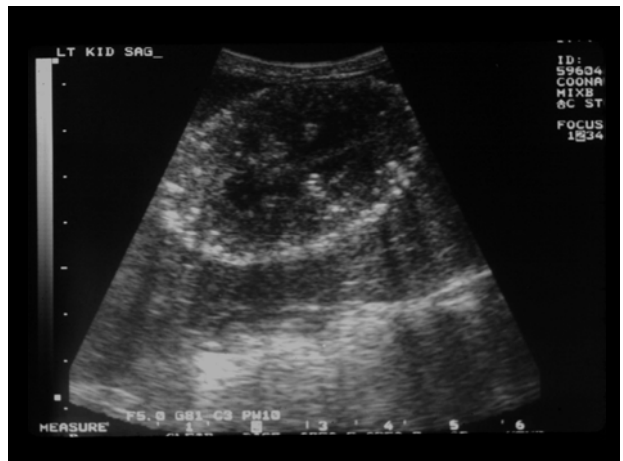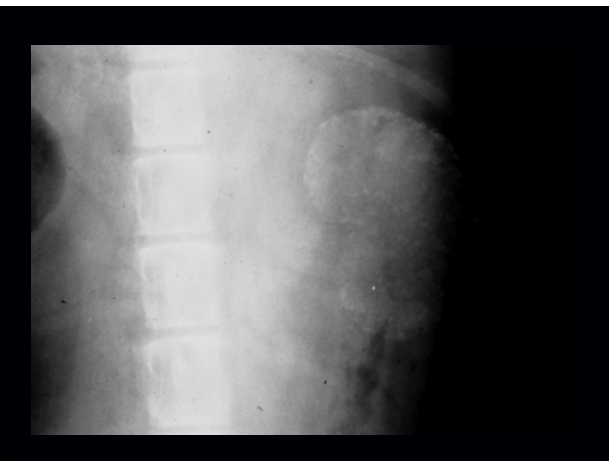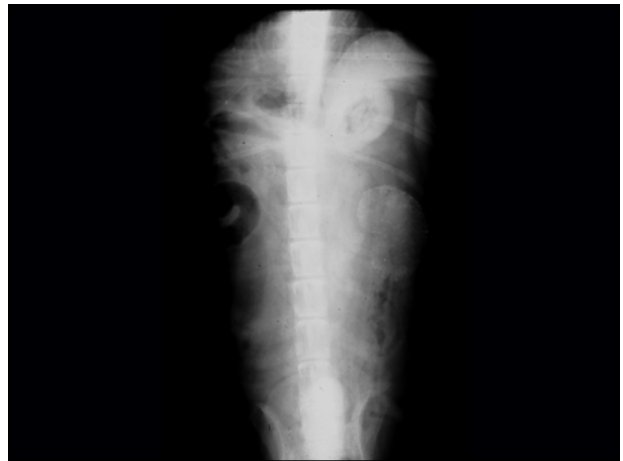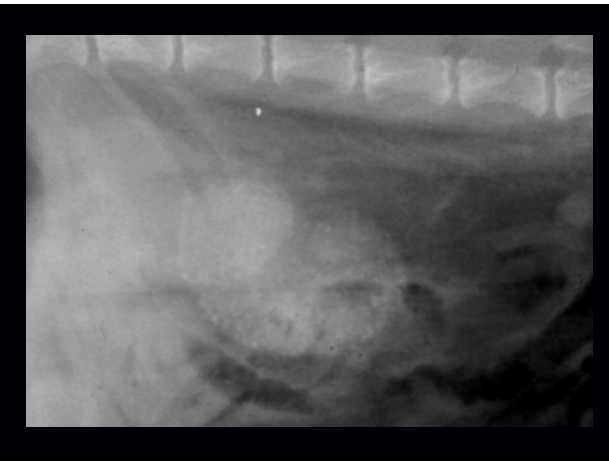
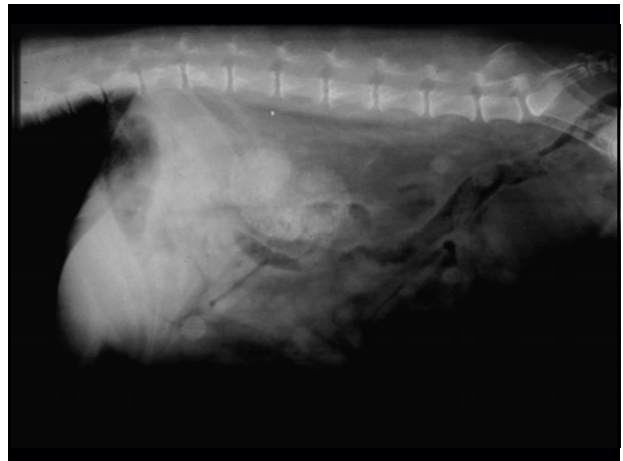
?

?

If you wanted to lower his blood Ca, at this stage, while you work him up...

Choose *the least appropriate* way:

1. 0.9% NaCl
2. Frusemide
- 3. Prednisolone**
4. Calcitonin



Stoogie – Abdominal Imaging

- Widespread, severe, multifocal discrete areas of mineralisation within both kidneys and the prostate gland
- No sign of pelvic or sublumbar lymphadenopathy

Updated problem list

- Azotaemia with isosthenuria
- Hyperphosphataemia
- Hypercalcaemia
- Urinary tract infection
- Severe renal mineralisation

Updated problem list

Still active

- Chronic PU/PD, lethargy, vomiting, inappetence
- Pea-sized anal sac mass



Are you ready to prepare Stoogie for removal of that anal sac mass?



1. Yes
2. No
3. Not sure



If not, why not?



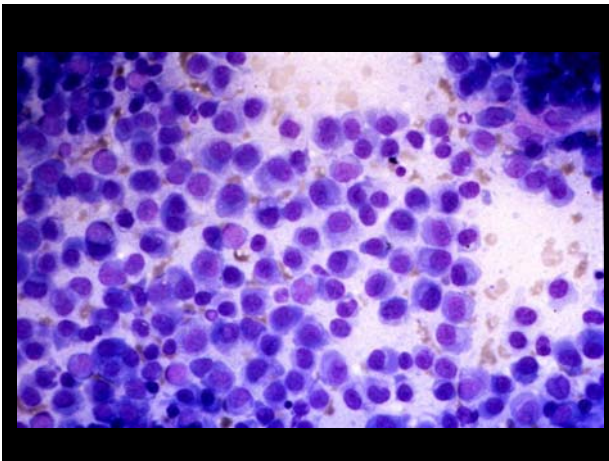
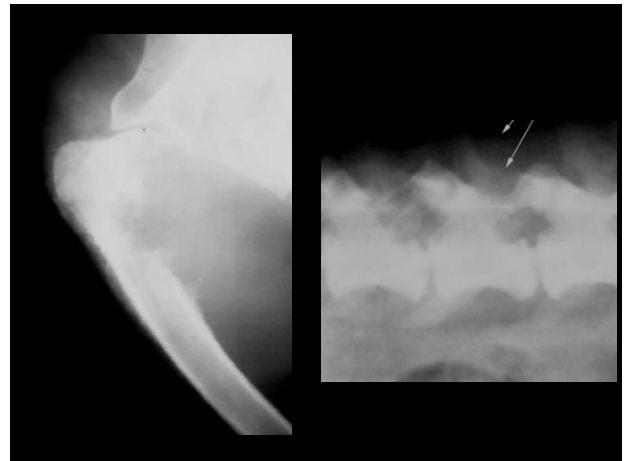
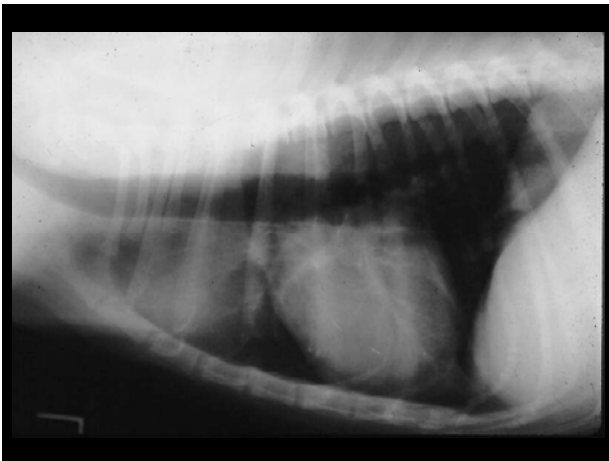1. I suspect something else is going on
2. I don't think this dog will ever benefit from surgery
3. Something else



Options for further investigation



1. Chest radiographs
2. Radiographic skeletal survey
3. Bone marrow aspirate(s)
4. PTH assay / ionized calcium
5. PTHrP assay



PTHrP

- Apocrine gland adenocarcinoma
- Lymphoma (not all)
- Other tumours

What about the size of that anal sac mass, given his history?

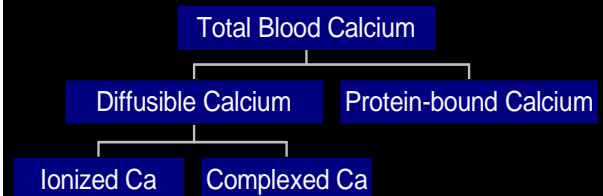
Options for further investigation

1. Chest radiographs
2. Radiographic skeletal survey
3. Bone marrow aspirate(s)
- 4. PTH assay / ionized calcium**
5. PTHrP assay

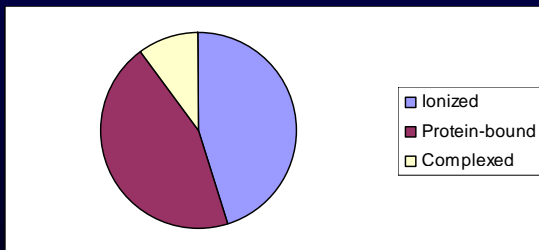
Further laboratory results

- PTH : 48 (n = 2-13)
- Ionized Ca: 1.53 mmol/L (N = 1.25-1.45)

Calcium fractions in blood



Calcium fractions in blood

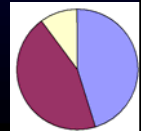

Ionized calcium is the physiologically active fraction

Hypercalcaemia in CRF

Total calcium may be a bit high, but ionized calcium usually isn't

(↑complexed Ca)



HyperPTH in CRF (simplified)

Phosphate retention → tendency to hypoCa → hyperPTH

So what if the iCa is high for another reason?

Presumptive diagnoses

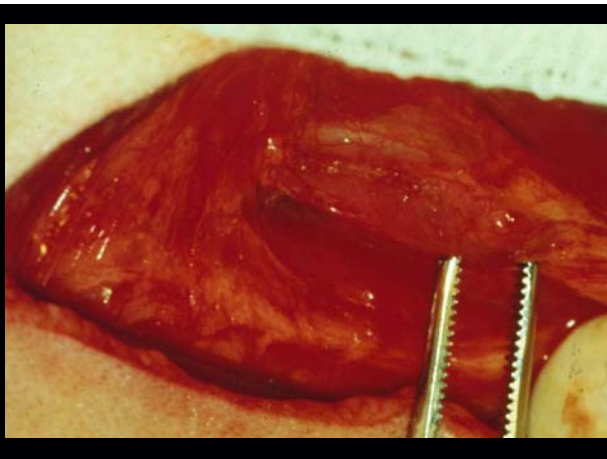- Primary hyperparathyroidism (no adenoma seen on U/S)
- ± Apocrine adenocarcinoma
- CRF
- UTI

Plan

- Appropriate antibiotic R_x for UTI
- Careful anaesthesia
- Surgical exploration of the parathyroid glands
- Excisional biopsy of right anal sac with the mass

Surgical pathology

- Single parathyroid adenoma
- Apocrine gland adenocarcinoma



The most predictable post-op complication?


1. Hypocalcaemia
2. CRF
3. Systemic hypertension
4. GI bleeding
5. Pleural effusion and ascites

The most predictable post-op complication?

- 1. Hypocalcaemia**
2. CRF
3. Systemic hypertension
4. GI bleeding
5. Pleural effusion and ascites

Outcome

- Home on medical management for CRF, systemic hypertension
- Progressive deterioration in renal function eventually led to euthanasia several months later



Span – an 8 year-old female Fox Terrier



Span – an 8 year-old female Fox Terrier

- Presented for acute depression and anorexia of 24 hours' duration
- T° 39°C, tense abdomen
- Haemorrhagic diarrhoea began six hours later. Received enrofloxacin and cephalexin at referring practice



Span – an 8 year-old female Fox Terrier

- PCV 41
- WBCC 143 x 10⁹/L (bands 11.4, Segs 124, Lymphs 2.86, Eos 4.29)
- Platelets adequate
- ↑ serum amylase & lipase



Span – an 8 year-old female Fox Terrier


- 48 hours later: muffled lung sounds
- PCV 33, TPP 52.1, retics 9.1 x 10⁹/L
- WBCC 252 x 10⁹/L (bands 22.68, segs 214.2, lymphs 7.56, monos 5.04, eos 2.52)



Span – an 8 year-old female Fox Terrier

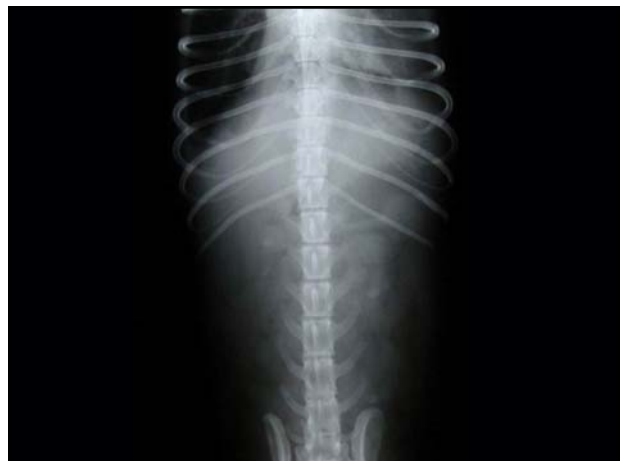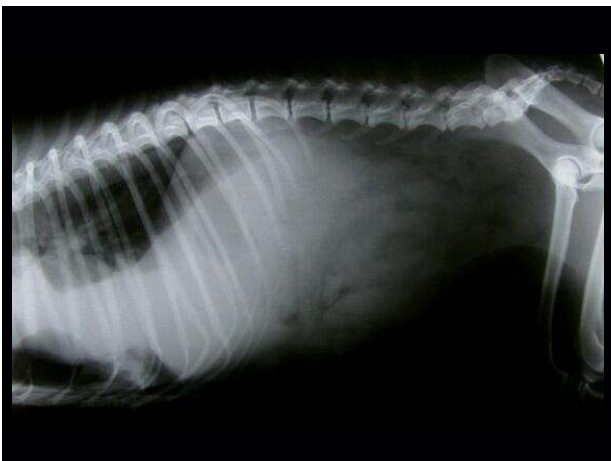
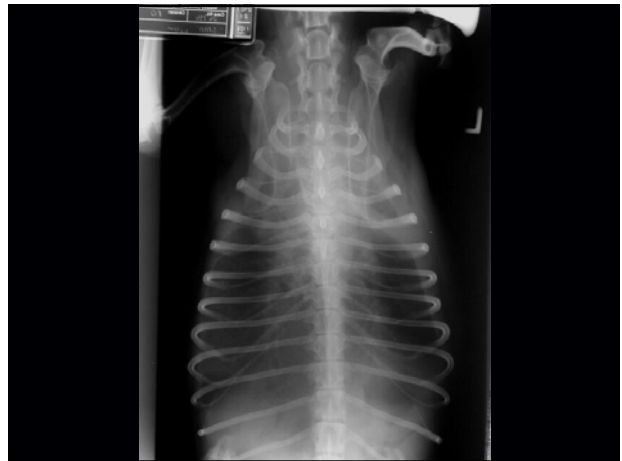
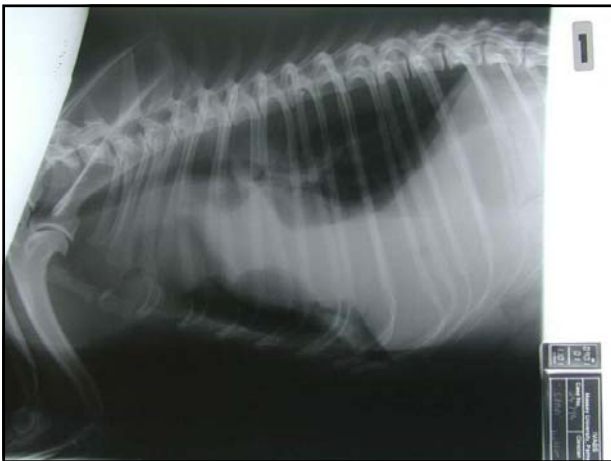- Many neutrophils show toxic changes, some lymphs look active
- ALP 232, amylase 1976, lipase 3538, bilirubin 11.4, albumin 22.1
- Urinalysis non-remarkable





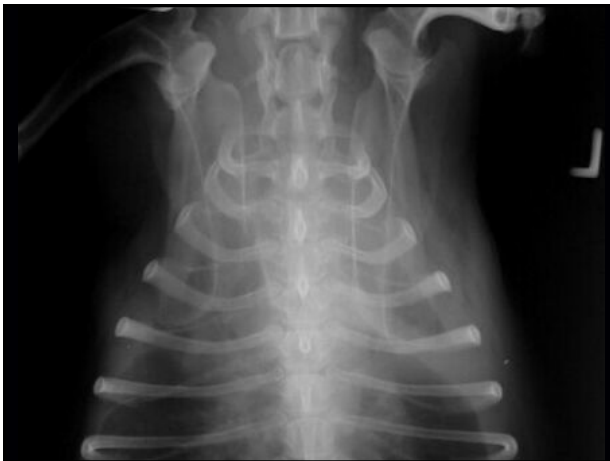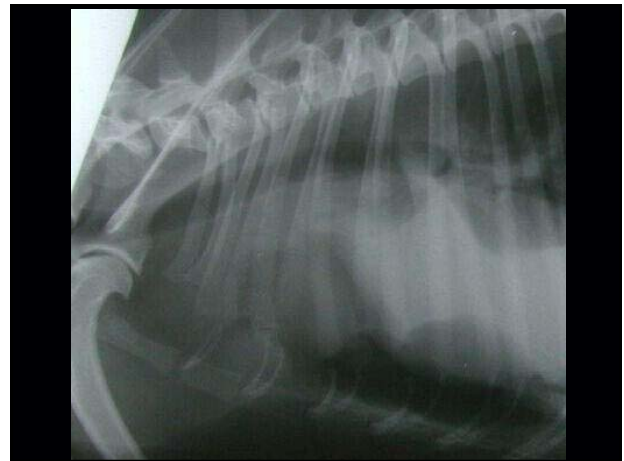
Does the presence of 'toxic changes' in PMNs indicate an infection is present?

- Yes
- No
- Usually



Your radiographic findings?

1. Pleural effusion
2. Cranial mediastinal mass
3. Pancreatitis
4. 1 and 2
5. 1, 2 and 3



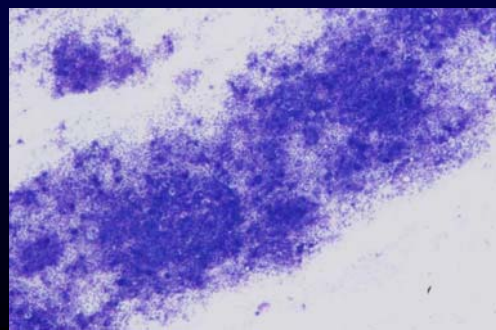
Cytology of pleural fluid

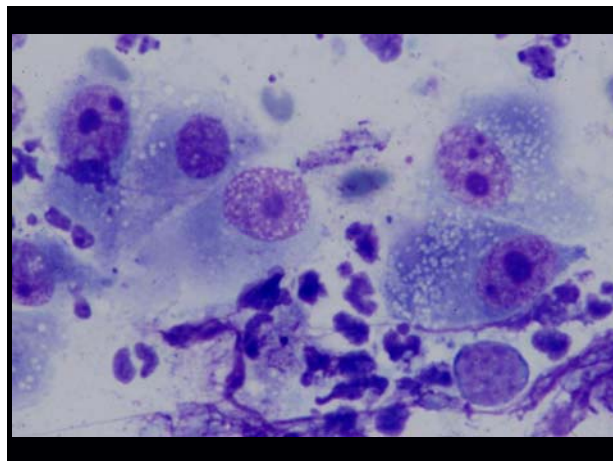
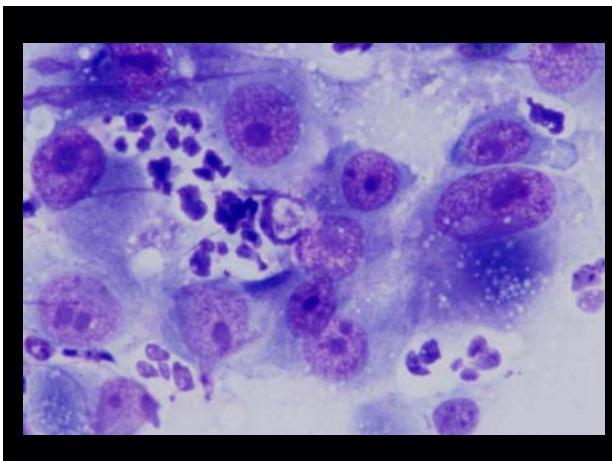
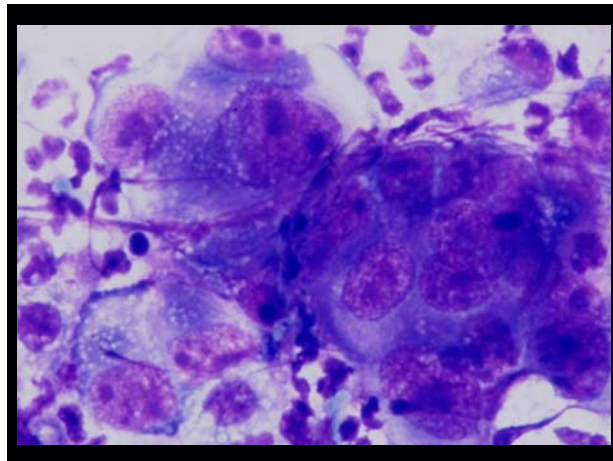
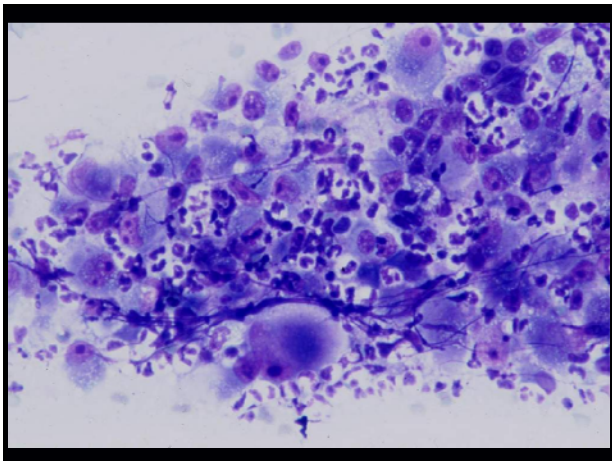
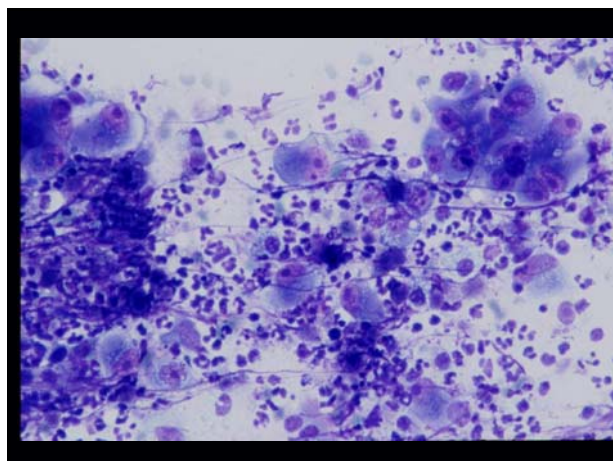
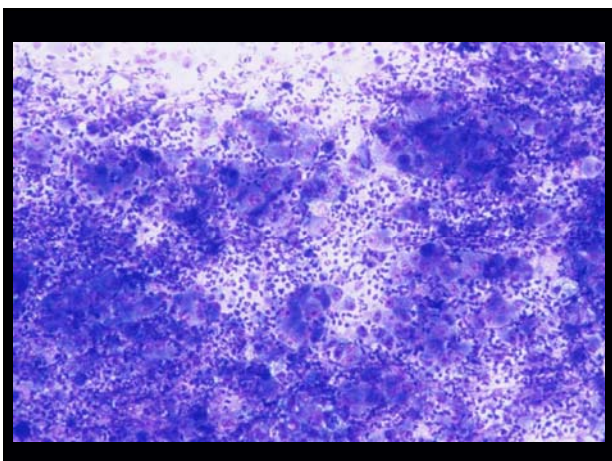
- *“Suppurative inflammation with toxic changes in PMNs. Recommend bacterial culture.”*

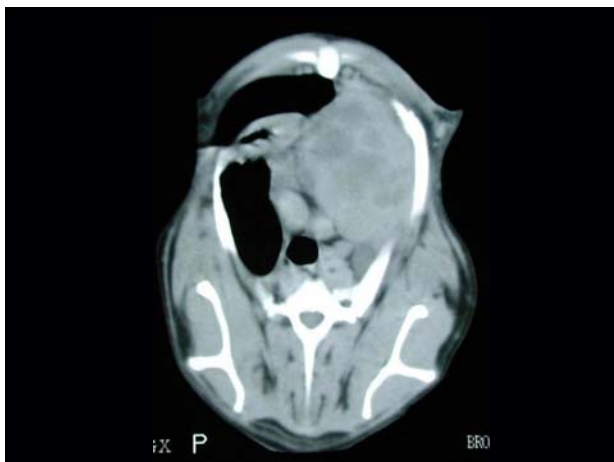
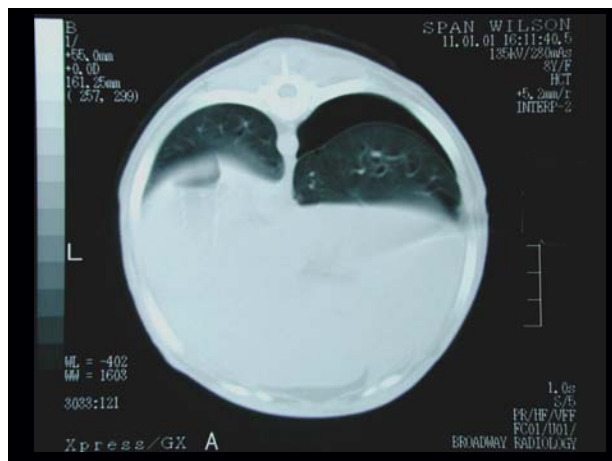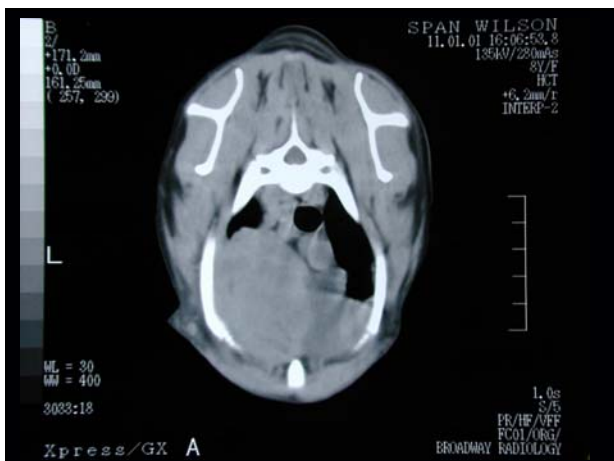Faecal culture

- Negative for Salmonella, Campylobacter and parasites

Aspirate cranial mediastinal mass



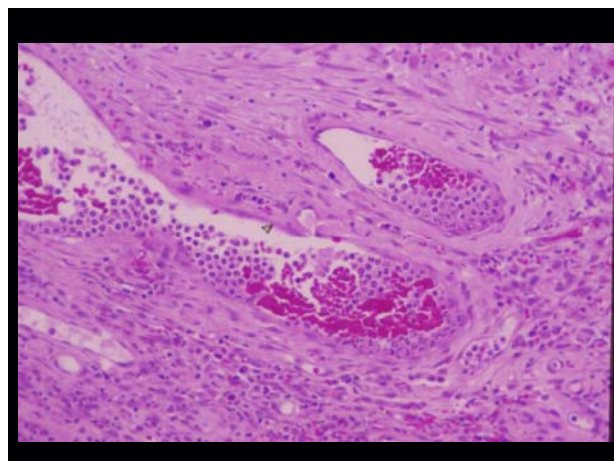
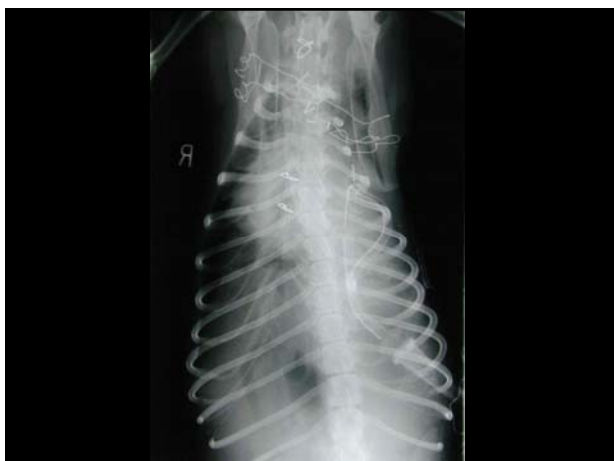

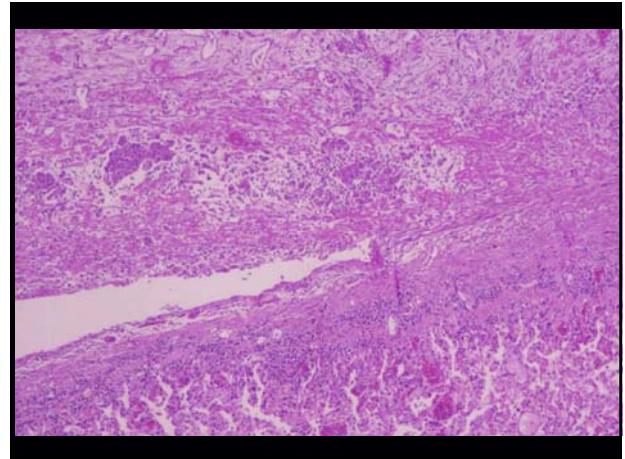
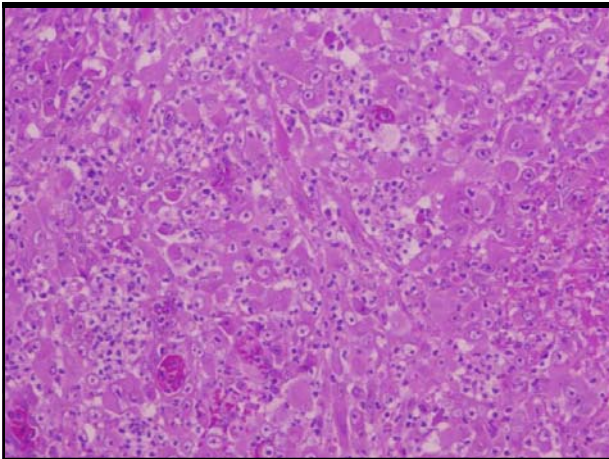


Least plausible mechanism of the extreme neutrophilia?

1. Tumour necrosis
2. Occult pancreatitis
3. Acute myelogenous leukaemia
4. Paraneoplastic
5. Infectious

? ?





Neutrophil chemotactic factors produced by malignant fibrous histiocytoma cell lines.

British Journal of Cancer
67(3):508-13, 1993

Inflammatory fibrous histiocytoma presenting leukemoid reaction.


Pathology, Research & Practice.
184(5):498-506, 1989

Inflammatory fibrous histiocytoma: an important variant of malignant fibrous histiocytoma highly responsive to chemotherapy.

Annals of Internal Medicine
97(6):858-63, 1982

Malignant fibrous inflammatory histiocytosis

Extreme leukocytosis



- Usually a neutrophilia, with or without a left shift
- Usually no fever
- ~60-330 x 10⁹/L PMNs
- Synthesis of haematopoietic growth factors by the tumour *e.g.*, G-CSF, GM-CSF, IL-3
- Need to remove the underlying cause



Bridget

An 8½ year-old female spayed English Springer Spaniel

Potted case summary



- Excellent appetite
- PU/PD (weeks to months)
- Urinary incontinence at night
- Difficulty seeing (?)

Potted case summary



- Raised liver enzymes
 - ALT 640
 - ALP 410
- Failure to suppress in LDDST on two occasions
- Hypoglycaemia



Your most favoured next step...

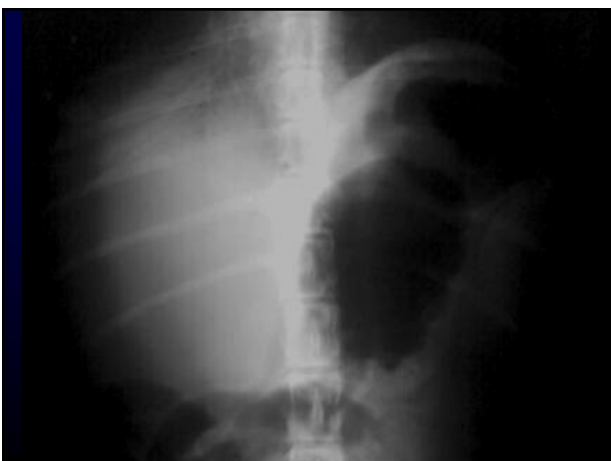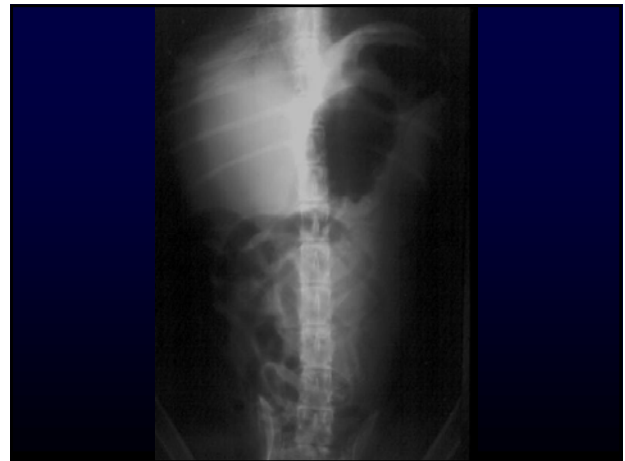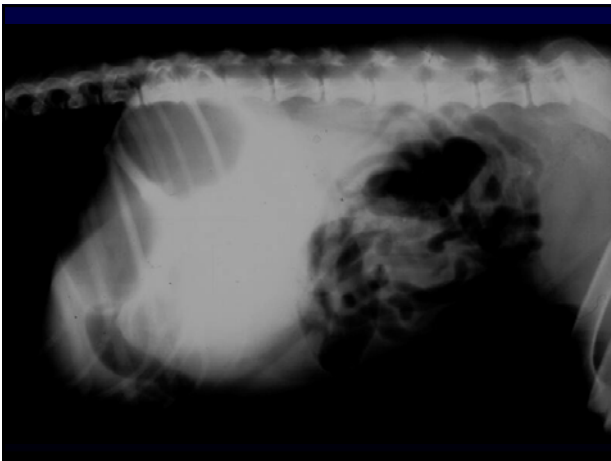
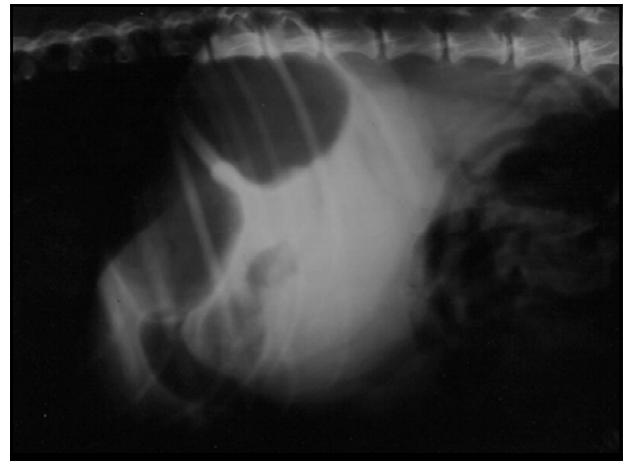
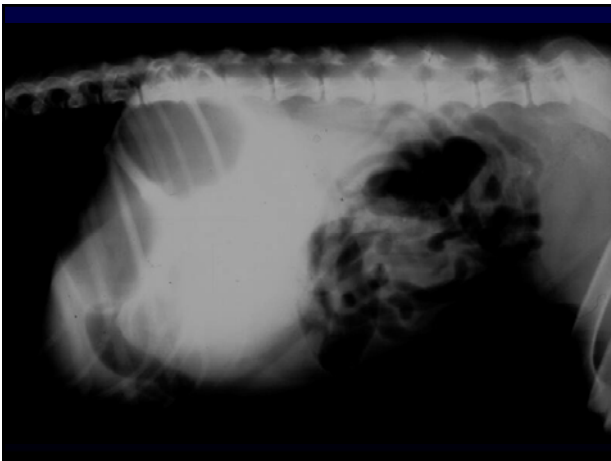


1. Image the liver
2. Image the adrenals
3. Recheck the blood glucose
4. Do an ACTH stimulation test instead of a LDDST
5. Do serum bile acids

Case progression



- Developed gastric dilatation, easily relieved by gastric intubation
- Bile acids done 12 hours later were modestly elevated
- Hypoglycaemia persists



? Your thoughts? **?**

1. Chronic gastric dilatation-torsion
2. Right cranial abdominal mass, displacing the stomach to the left and 'indenting it'
3. Pancreatic 'phlegmon'
4. Large liver tumour
5. None of the above

Abdominal ultrasound findings

- 8 cm diameter caudate lobe liver mass, pressing on the stomach



What about the hyperadrenocorticism?



1. ACTH secretion by the liver tumour
2. Glucocorticoid-secreting liver tumour
3. A false positive result due to the hypoglycaemia
4. Stress caused by non-adrenal illness
5. None of the above



What about the hypoglycaemia?

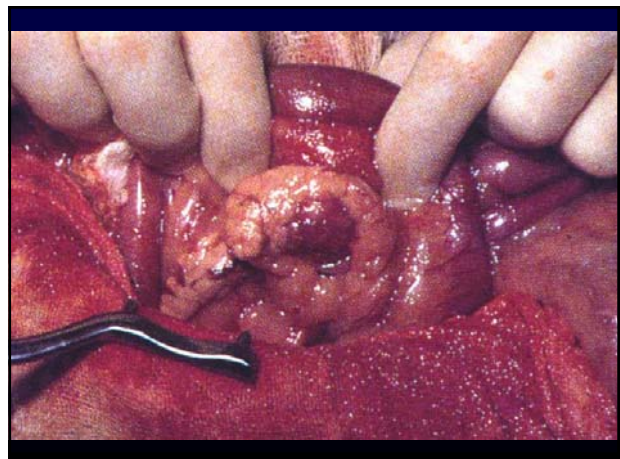
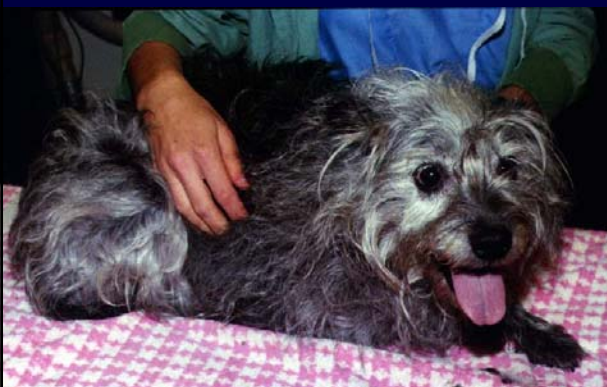

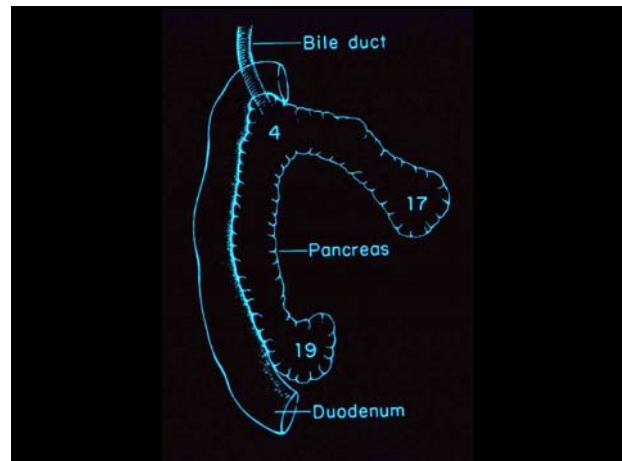
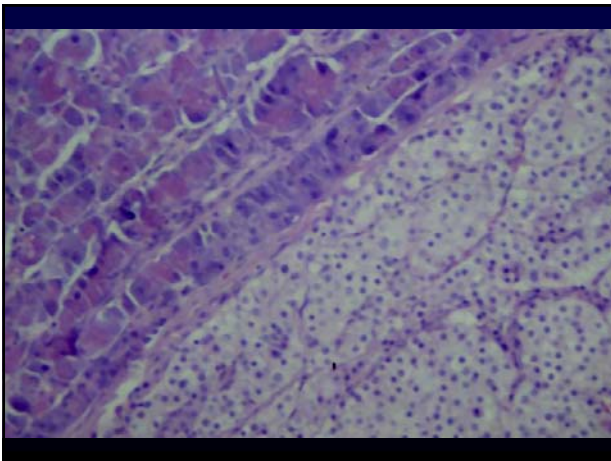
1. Concurrent insulinoma in the pancreas
2. Glucagon-secreting liver tumour
3. A false positive result due to prolonged storage of the blood
4. Production of 'hypoglycaemia-inducing substances' by the liver tumour
5. Consumption of glucose by the large liver tumour

Adult-onset hypoglycaemia

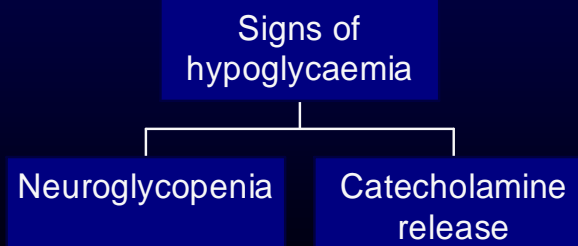
- Insulinoma
- Large liver tumours (esp. hepatomas, hepatocellular carcinomas)
- Leukaemias
- Salivary adenocarcinoma
- Others

Melanie





Paraneoplastic hypoglycaemia



Adult-onset hypoglycaemia

- Islet cell tumours make insulin
- Non-islet solid tumours make insulin-like growth factors
- Leukaemic cells may consume blood glucose
- Septic tumour-bearing patients may become hypoglycaemic by other mechanisms

Paraneoplastic hypoglycaemia

Clinical Features

- Insulinomas mainly in large breed dogs
- Liver tumours in any breed
- Seizures
- Hind limb weakness
- May require 48-72 hour fast to confirm presence of hypoglycaemia

Paraneoplastic hypoglycaemia

Differential Diagnoses

- laboratory artifact
- liver failure
- Addison's disease
- sepsis

Paraneoplastic hypoglycaemia

Differential Diagnoses

- Starvation
- Glycogen storage disease
- 'Hunting dog hypoglycaemia'
- Insulin overdose

Paraneoplastic hypoglycaemia

Diagnosis

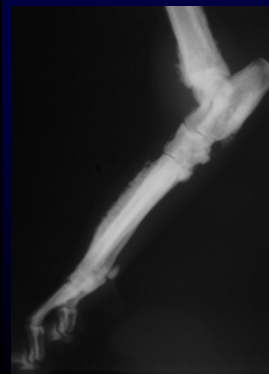
- Imaging
- Routine lab. work
- Insulin:glucose ratio
- Exploratory laparotomy

Paraneoplastic hypoglycaemia

Treatment

- Remove underlying cause if possible
- Glucocorticoids
- Frequent feeding
- ± Streptozotocin (Zanosar)
- ± Diazoxide
- ± Octreotide

Hypertrophic osteopathy



- Lameness, pain, swelling
- Thoracic diseases
- Bladder tumour rhabdomyosarcoma
- Increased blood flow, periosteal proliferation
- Vagotomy helps (neurovascular effect)

Superficial necrolytic dermatitis

- Liver disease, glucagonoma, other associations
- Hypoaminoacidaemia / Zn / niacin
- Median 10y, M > F

Superficial necrolytic dermatitis

- Feet
 - interdigital erythema, nail loss, hyperkeratosis
- Face
 - symmetrical erythema, alopecia, crusts around mouth, muzzle

Superficial necrolytic dermatitis

- Secondary infections
- Diagnosis: clinical suspicion in an animal with liver disease
- Confirmed by histopathology

Cancer cachexia (dogs)

- Anorexia, weight loss, fatigue, impaired immunity; not fully corrected by adequate caloric intake
- Alterations in carbohydrate, fat and protein metabolism are detectable before 'cachexia' is obvious

Cancer cachexia (dogs)

- Cytokines are hypothesised to mediate the effect (e.g., TNF, IL-1, IL-6, IFN alpha and IFN gamma)
- Interestingly, the metabolic derangements have been shown to persist during complete remissions induced by doxorubicin

Cancer cachexia (dogs)

- Many tumours preferentially use carbohydrates as fuel
- In humans and dogs, there is some evidence that diets relatively low in carbohydrates and replete in protein and fat confer an advantage on the patient (e.g., patient is more likely to go into remission)

Cancer cachexia (dogs)

- Arginine-deficient animals have decreased immune function. This improves with arginine supplementation.

This session is sponsored by

