



Joanne MacLean
Darren Russell

Pruritus ani

Background

Anal pruritus affects up to 5% of the population. It is often persistent and the constant urge to scratch the area can cause great distress. Although usually caused by a combination of irritants, particularly faecal soiling and dietary factors, it can be a symptom of serious dermatosis, skin or generalised malignancy or systemic illness.

Objective

This article discusses the assessment and management of Pruritus ani.

Discussion

It is important not to trivialise the symptom of anal Pruritus and to enquire about patient concerns regarding diagnosis. Once serious pathology has been excluded, management involves education about the condition; elimination of irritants contributing to the itch-scratch cycle including faecal soiling, dietary factors, soaps and other causes of contact dermatitis; and use of emollients and topical corticosteroid ointments. Compounded 0.006% capsaicin appears to be a safe and valid option for Pruritus not responding despite adherence to these conservative measures.

Keywords: pruritus ani; skin diseases; anus diseases



Anal pruritus, an intense chronic itching affecting the perianal skin, is a common condition. Anal pruritus is estimated to affect up to 5% of the population, with a male to female ratio of 4:1.¹⁻³

The patient with anal pruritus is typically an anxious and/or overweight male aged 40–60 years, with a colonic reflex associated with stress. Although an apparently trifling symptom, it is often persistent and the constant urge to scratch the area can cause great distress, not to mention some embarrassing moments. Perhaps because of this embarrassment, patients will often try a number of home remedies or ‘over-the-counter’ preparations before seeking medical advice. Although often resulting from benign causes such as faecal soiling and dietary factors, coexisting perianal pathology is frequently present and it is occasionally a serious underlying medical conditions (*Table 1*). In up to a quarter of cases the anal Pruritus is idiopathic.¹

Aetiology

The majority of cases of anal Pruritus have a ‘benign’ aetiology, and result from a combination of faecal soilage and dietary factors. Local anorectal disorders and contact dermatitis of the perianal skin may exacerbate the problem.

Faecal soiling, diet and the itch-scratch cycle

Faecal soilage may be a result of poor hygiene, anatomic abnormalities which make removal of faecal material difficult (eg. haemorrhoids, fissures, skin tags) or a primary abnormality of internal anal sphincter function. One study, using computerised ambulatory electromyography and manometry, demonstrated a longer duration of internal sphincter relaxation in patients with anal pruritus compared with controls.⁴ Faecal soilage may also be caused by abnormal bowel motions – diarrhoea due to food intolerance, antibiotics, laxatives and enemas. Diarrhoea may also cause perianal excoriation and constipation may causes fissures.

Sweating associated with inappropriate clothing or obesity may add to the suboptimal perianal conditions. These factors lead to irritation and subsequent scratching, which damages the sensitive perianal skin, worsening itch and precipitating an itch-scratch cycle. Even mild degrees of faecal soiling, which the patient may not be aware of, may be enough to cause an itch-scratch cycle.¹



Dietary associations with pruritus ani include caffeine, alcohol, chocolate, tomatoes, spices and citrus fruit. Some of these foods are known to cause relaxation of the lower oesophageal sphincter and therefore may contribute to internal anal sphincter relaxation.^{1,4,5}

Anorectal conditions

Any coexisting anal conditions can precipitate itch and up to half of patients with Pruritus ani will have an anorectal disorder, most commonly haemorrhoids.¹ It is important to note that anal cancers, perianal Paget disease and perianal Bowen disease, may present with itch.¹

Skin disorders

Perianal skin disorders are a very common association with Pruritus ani. In a series of 40 patients attending a combined colorectal and dermatology clinic, 34 had a recognisable dermatosis and 18 of these were contact dermatitis.⁶

Contact dermatitis can occur from a wide range of topical agents such as soaps, shower gels, creams, talc, perfumed/bleached toilet paper, baby wipes and latex condoms.^{1,6} Patients with anal Pruritus will frequently overwash with soap products or use a number of over-the-counter products which may worsen the problem. Frequently, contact dermatitis occurs from therapeutic agents.⁷ Haemorrhoid preparations can cause contact dermatitis. (Lignocaine is a rare allergen but benzocaine, which is found in some haemorrhoid preparations, is a common allergen.) Topical corticosteroid cream may also contain sensitising agents, resulting in deterioration in symptoms over a wider area after initial improvement.¹

Other skin disorders that may occur in association with anal Pruritus are listed in *Table 1*.

Infections

Although less common than the above listed causes, bacterial and fungal infections are important considerations. Fungal infections account for up to 15% of cases of Pruritus ani.⁵ Dermatophytes such as tinea are pathogenic and should be treated. *Candida* may be a commensal, but is more likely to be pathogenic in patients with diabetes, after steroid treatment and after systemic antibiotic use.¹

Bacterial infections including beta haemolytic streptococci and *Staphylococcus aureus* tend to cause chronic symptoms, with streptococcal infections more common in children.¹ Erythrasma is a cutaneous infection caused by *Corynebacterium minutissimum*, and often infects the toes and groin, as well as the perianal area, and can be diagnosed by Wood's light fluorescence.

Threadworms often infect multiple family members.

Sexually transmissible infections (STIs) including genital warts, genital herpes, syphilis, gonorrhoea and *Chlamydia trachomatis* can be associated with Pruritus ani, as can molluscum contagiosum and scabies.

Serious underlying causes not to be missed

Although the vast majority of cases are benign (despite being persistent or recurrent), occasionally cases are associated with more serious dermatoses; anorectal, skin or other malignancies; or systemic disease. It is important that these possibilities are considered during the history, examination and investigation.

History

It is important to take a directed history in order to identify readily treatable causes and exclude or diagnose serious pathology. Some patients will know, or think they know, what has caused the itching and it might not be the first thing that springs to your mind! It may be beneficial to address the patient's darkest fears (such as cancer or STIs) early. Asking the patient how much time they have spent 'googling' their condition often provides a clue to their level of anxiety.

The history of a patient with anal pruritus should cover the following:

- onset and time frame of the symptoms
- history of other significant medical conditions such as diabetes and connective tissue diseases. (Inadequately treated diabetes may predispose to poor anal sphincter tone and infection⁸)
- history of other skin complaints (eg. atopy, psoriasis, dermatitis, lichen sclerosus)
- bowel habit, including diarrhoea, constipation, rectal bleeding, weight loss, change in bowel habit. Rectal bleeding or weight loss should be appropriately investigated
- drug history, as some cases of pruritus are caused by drug eruptions or diarrhoea related to medications (eg. laxatives, antibiotics). (Topical polypharmacy leading to irritant or allergic contact dermatitis is common)
- dietary history, including caffeine intake, lactose or wheat intolerance and change in diet temporally related to pruritus
- family history of inflammatory bowel disease, dermatoses, diabetes or bowel cancer may be relevant
- sexual history should include inquiry about receptive anal intercourse or STIs such as herpes simplex virus (HSV) and genital warts. Contrary to popular belief, there is no evidence that consensual anal intercourse causes abnormal anal sphincter function. However, anal STIs may cause pruritus, latex condoms can cause a contact dermatitis and inadequate lubrication may cause minor skin trauma and consequent pruritus
- psychological/psychiatric disturbance, especially anxiety and depression, may be significant but may be a result of the symptoms. Delusional parasitosis is rare
- social history, including housing and employment, is relevant to managing perspiration, clothing and personal hygiene
- irritants, including perfumes and potions, use of potential irritants for pubic/perianal hair removal, washing, douching and other forms of 'groin grooming' can cause an irritant dermatitis.

Invite the patient to consider any other relevant history they may not have told you.



Table 1. Causes of Pruritus ani

Faecal soiling
Dietary factors <ul style="list-style-type: none">• More common: coffee (caffeinated and decaffeinated), tea, cola, alcohol, chocolate, tomato, including tomato sauce (histamine)• Less common: milk, peanuts, citrus fruits, grapes, spicy foods, prunes, figs
Anorectal disease <ul style="list-style-type: none">• Haemorrhoids• Abscesses• Anal fissures• Fistulae• Crohn disease
Benign tumours <ul style="list-style-type: none">• Seborrhoeic keratoses• Angiokeratomas• Anal intraepithelial neoplasia (rarely causes pruritus, generally asymptomatic)• Bowenoid papulosis (may contribute to faecal soiling)
Malignant tumours <ul style="list-style-type: none">• Squamous cell carcinoma• Extramammary Paget disease• Melanoma
Skin conditions <ul style="list-style-type: none">• Contact dermatitis – commonly (see text)• Hidradenitis suppurativa• Seborrhoeic dermatitis, atopic dermatitis• Psoriasis• Lichen simplex chronicus, lichen sclerosus et atrophicus, lichen planus• Connective tissue disease• Drug eruptions• Trauma (eg. waxing burns, shaving injuries and injuries secondary to anal insertion of foreign bodies)
Infection <ul style="list-style-type: none">• Worms, commonly threadworm• STIs – genital warts, genital herpes, syphilis, gonorrhoea, chlamydia, molluscum contagiosum, scabies, pubic lice• Tinea, candida• Streptococcal and staphylococcal infections, erythrasma
Other medical conditions <ul style="list-style-type: none">• Coeliac disease• Diabetes mellitus• Leukaemia/lymphoma• Renal failure• Iron deficiency anaemia• Hyperthyroidism• Hypovitaminosis (deficiencies of vitamin A, B and D have been associated with anal pruritus)
Iatrogenic
Chemotherapy
Psychological <ul style="list-style-type: none">• Anxiety• Sexual abuse• Fear of STI or cancer• Delusional parasitosis
Idiopathic <ul style="list-style-type: none">• Up to 25% of cases



Examination

Examination should not be limited to the anoderm, unless, following the history, the clinician is confident a limited examination will confirm the diagnosis. A full skin examination is often required, including examination of mucous membranes, nails, scalp, beard, chest, axillae and groin looking for evidence of dermatoses, lice, scabies, drug eruptions, and secondary syphilis.

Genital/perianal examination includes:

- examination of pubic hair for lice
- external genitalia and perianal area for evidence of *Condylomata acuminata* (warts), *C. lata* (secondary syphilis), squamous cell carcinoma (SCC), abscesses, ulceration, erythema, white areas and loss of architecture, signs of dermatoses and faecal soiling
- digital examination if rectal bleeding has been reported.

Use a lubricated proctoscope to examine the anal canal for reducible haemorrhoids, warts, SCC, erythema, pus around the anal crypts and ulceration. A Wood's lamp is useful to exclude *Corynebacterium*. However, despite all these possibilities, examination may be entirely normal.

Investigations

After history and examination, investigation may not be necessary. However, anorectal diseases and anorectal manifestations of systemic disease must be excluded. In patients with history or examination suggestive of other causes, and in those not responding to conservative care, relevant investigations may include:

- full blood count (useful for diagnosing infection, worm infestation or atopy)
- immunoglobulin E
- blood glucose
- syphilis serology if signs of possible syphilis infection such as condylomata lata, chancre, mucous patches. (Note that syphilis is increasingly common in men who have sex with men)
- tissue transglutaminase (coeliac screen)
- swabs for microscopy and culture (fungal, streptococcal, staphylococcal, gonococcal and *Corynebacterium* infections)
- if at risk of STIs, anal polymerase chain reaction (PCR) swabs for *Neisseria gonorrhoeae*, *C. trachomatis*, PCR swabs taken from lesions for HSV, syphilis and vaginal swabs (vaginal discharge may cause anal pruritus)
- patch tests if contact dermatitis is suspected
- nocturnal cello tape test and/or stool test for helminthes (Figure 1, 2)
- biopsy (3–6 mm punch). This is useful for diagnosing noninfective blistering skin conditions in patients not responding to conservative treatment and for investigating abnormal looking areas for SCC. However, biopsy is unlikely to be helpful if the skin is macroscopically normal (Notes on biopsy: if time permits use emla cream or lignocaine gel to reduce sensation before injecting local anaesthetic with a 26 g needle. Use of silver nitrate or aluminium chloride solution is sometimes preferable to a suture,

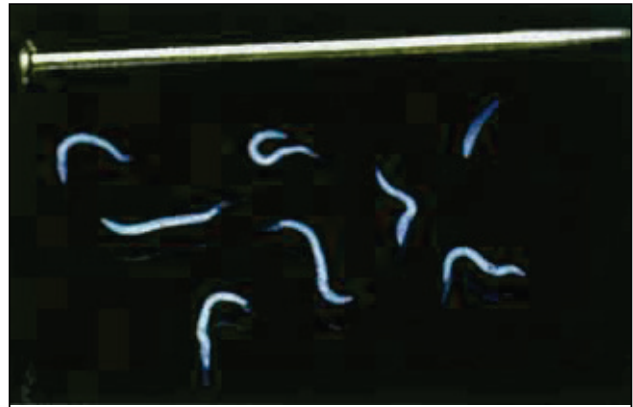


Figure 1. Adult female pinworms

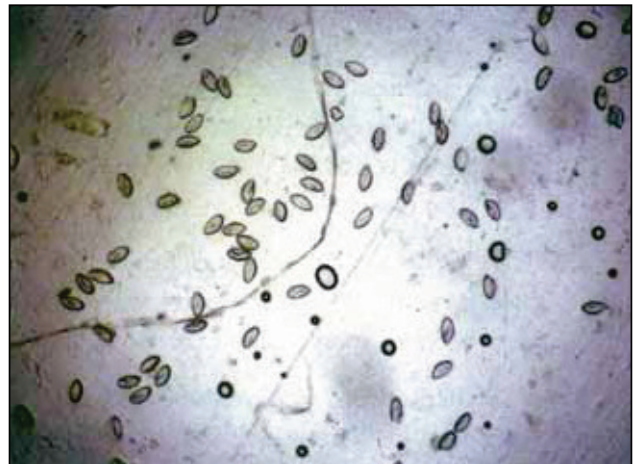


Figure 2. Positive stickytape test for pinworm

depending on the biopsy site. Biopsy the most abnormal looking area, and if biopsying a vesicular lesion, include a small area of normal skin for comparison. It is worthwhile seeking out a pathologist with an interest in dermatoses)

- colonoscopy if there are any suspicious symptoms accompany pruritus, such as altered bowel habit or bleeding.

Management of benign anal pruritus

Any underlying factors identified need to be appropriately treated. It is important to educate the patient about the recurring, benign nature of this irritating condition and to ensure adherence to the following simple, yet essential, measures to eliminate irritants and resolve symptoms.

Normalisation of bowel motions

Additional fibre and an adequate fluid intake should be directed toward achieving the perfect stool, said to be that which is formed yet so smooth that it barely requires the use of toilet paper.

Twice round the pan and pointed at both ends. Such happy defecators are rarely troubled by pruritus.

J Alexander-Williams⁹



Cleaning after defaecation

Patients often inadvertently worsen their symptoms with overzealous cleaning of the perianal area. Perfumed or bleached toilet paper is a potential irritant and should not be used. The use of a bidet, a bucket of lukewarm water, wet cloth or moist cotton wool is preferable and the perianal area should be patted dry with a soft cloth or unbleached toilet paper or dried with a hair dryer. Rubbing or scrubbing the area should be actively discouraged.

Clothing

Advise the wearing of loose, natural fibre clothing, and the avoidance of prolonged sitting.

Nudism is ideal but, sadly, often impracticable.
J Alexander-Williams⁹

Soaps and cleansers

Advise patients to not use soap – use aqueous cream or a soap free cleanser in the shower instead and to cease the use of any other creams or potential irritants, including over-the-counter treatments and hair removal methods.

Do not scratch!

This can be a tricky one as patients often scratch at night, sometimes to the point of bleeding, without being aware of doing so. Advise paring back fingernails and the wearing of gloves or mittens to bed, preferably ones that fit snugly around the wrist as these are less likely to be removed during sleep. A sedating antihistamine at night may be required.

With attention to the above listed management, some patients may require no further treatment or only a zinc cream or mild topical steroid such as 1% hydrocortisone.¹ However, some patients will still experience pruritus – and it is essential to break the itch-scratch cycle. Having excluded infections of the perianal skin, a potent topical steroid may be used, preferably in an ointment base (as it contains less potential preservative irritants; however, some patients will prefer the texture of creams, especially if the area is hairy) twice daily for 3–6 weeks. Start with methylprednisolone fatty ointment reducing to a moderate potency preparation such as betamethasone valerate 0.02% and then 1% hydrocortisone cream. Advise patients that this is not curative and that they may need to return to a more potent preparation from time-to-time; 2% liquor picis carbonatum in aqueous cream can also be used.

Other treatments for intractable pruritus

Various treatments including local anaesthetic injections, cryotherapy and destruction of subcutaneous nerves with injected methylene blue, alcohol or phenol² have been tried, with little success.

An Israeli study of 44 patients with intractable pruritus ani produced encouraging results using topical capsaicin in a 0.006% preparation.¹⁰ Capsaicin, which depletes substance P in nerve cells, is not commercially available in this strength and needs to be

made by a compounding pharmacist (by diluting currently available preparations with white soft paraffin). Stronger preparations tend to cause burning.

Fractionated X-ray has also been described in the treatment of intractable anal pruritus. In general, excising skin tags has not been shown to be of benefit but this needs to be assessed individually. Skin tags may prevent adequate cleaning of the perianal area and in some cases, excision may solve the problem.⁹

Conclusion

It is important not to trivialise the symptom of a pruritic anus. Anal pruritus may at worst be a symptom of serious or life threatening pathology such as SCC, and at best distressing and embarrassing. It is also important to enquire about patient concerns regarding diagnosis and, once serious pathology has been excluded, to explain the chronic nature of the condition and persist with the listed conservative measures. Compounded 0.006% capsaicin appears to be a safe and valid option for the desperate, if symptoms persist despite genuine cessation of rubbing and scratching.

Authors

Joanne MacLean BSc(Med), MBBS, FRACGP, DipRuralMed, is a general practitioner, Cairns Sexual Health Service, Queensland. joanne_maclean@health.qld.gov.au

Darren Russell FRACGP, DipVen, FACHSHM, is Clinical Associate Professor, The University of Melbourne and James Cook University, and Director of Sexual Health, Cairns Sexual Health Service, Cairns, Queensland.

Conflict of interest: none declared.

References

1. Siddiqi S, Vijay V, Ward M, Mahendran R, Warren S. Pruritus ani. *Ann R Coll Surg Engl* 2008;90:457–63.
2. Jones D. ABC of colorectal diseases: Pruritus ani. *BMJ* 1992;305:575–7.
3. Markell K, Billingham R. Pruritus ani: etiology and management. *Surg Clin North Am* 2010;90:125–35.
4. Farouk R, Duthie G, Pryde A, Bartolo DC. Abnormal transient internal sphincter relaxation in idiopathic pruritus ani: physiological evidence from ambulatory monitoring. *Br J Surg* 1994;81:603–6.
5. Smith LE, Henrichs D, McCullah RD. Prospective studies on the etiology and treatment of pruritus ani. *Dis Colon Rectum* 1982;25:358–63.
6. Dasan S, Neill SM, Donaldson D R, Scott H J. Treatment of persistent pruritus ani in a combined colorectal and dermatological clinic. *Br J Surg* 1999;86:1337–40.
7. Harrington CI, Lewis FM, McDonagh AJ, Gawkrödger DJ. Dermatological causes of pruritus ani. *BMJ* 1992;305:995.
8. Froese DP. Pruritus ani. In: *Current treatment in colon and rectal surgery*. Philadelphia: Mosby, 2005; p. 49–53.
9. Alexander-Williams J. Pruritus ani. *BMJ* 1983;287:159–60.
10. Lysy J, Sistiery-Ittah MJ, Israelit Y, et al. Topical capsaicin – a novel and effective treatment for idiopathic intractable pruritus ani: a randomised, placebo controlled, crossover study. *Gut* 2003;52:1323–6.

correspondence afp@racgp.org.au